

Oftalmološke manifestacije meningoencefalitisa nepoznatog podrijetla kod pasa

Morteza Gholi, Céline Sadaf

Master's thesis / Diplomski rad

2024

Degree Grantor / Ustanova koja je dodijelila akademski / stručni stupanj: **University of Zagreb, Faculty of Veterinary Medicine / Sveučilište u Zagrebu, Veterinarski fakultet**

Permanent link / Trajna poveznica: <https://um.nsk.hr/um:nbn:hr:178:687033>

Rights / Prava: [In copyright](#) / [Zaštićeno autorskim pravom.](#)

Download date / Datum preuzimanja: **2025-01-29**



Repository / Repozitorij:

[Repository of Faculty of Veterinary Medicine -](#)
[Repository of PHD, master's thesis](#)



THE UNIVERSITY OF ZAGREB
FACULTY OF VETERINARY MEDICINE

INTEGRATED UNDERGRADUATE AND GRADUATE UNIVERSITY STUDIES
VETERINARY MEDICINE

DIPLOMA THESIS

Céline Sadaf Morteza Gholi

Ocular manifestations of meningoencephalitis
of unknown origin in dogs

Zagreb, 2024

University of Zagreb
Faculty of Veterinary Medicine

Clinic for Surgery, Ophthalmology and Orthopaedics
Head of the Clinic: Prof. dr. sc. Dražen Vnuk
Mentor: Dr. sc. Valentina Plichta

Clinic for Internal Medicine
Head of the Clinic: Izv. prof. dr. sc. Iva Šmit
Mentor: Izv. prof. dr. sc. Ivana Kiš

Members of the Committee for Defence of the Master's Thesis:

1. Izv. prof. dr. sc. Ivan-Conrado Šoštarić-Zuckermann, DECVF
2. Dr. sc. Valentina Plichta
3. Prof. dr. sc. Martina Đuras
4. Izv. prof. dr. sc. Ivana Kiš DVM PhD (substitute)

This paper contains 57 pages, 24 figures, 4 tables and 38 literature citations.

ACKNOWLEDGEMENTS

I dedicate this thesis and the entirety of my studies to my beloved family, who have always believed in me and supported the pursuit of my childhood dream of becoming a veterinarian. I want to express my deepest gratitude to my mother for always being there during challenging times in which she brought the best out of me. Without you I'd certainly not become a veterinarian.

To my late father, baba jounam, I am eternally grateful. You have given me the strength to make the right decisions and have protected me throughout. I know studies have always been important for you and I hope I have made you proud. I wish you were here to witness my graduation.

I can't thank enough my sister Saina for being the one I can rely on in difficult times. Living away from you for 6 years made me understand how precious your presence is.

I extend my heartfelt thanks to my friends, without whom this journey in Croatia would not be the same. A special thanks to my amazing friend and study partner, Elisa who brought a spark to every part of this journey. Thank you, Jana, Becky, Sofie, Ida for being my little piece of Home in Croatia. Cheers to the wonderful moments we've shared, your pure hearts and your support. I'd like to thank all the people from my class without whom I'd not be the Céline I am today. Writing these words, I'd like to remember our Tiani who left us too soon. May your soul rest in peace Dr Meredith.

Thank you to Dr Lebars and Dr Olmo Lopez, to have taught me so much.

Many thanks to most of my professors, dedicated and passionate about their job, always taking the time to answer my (numerous) questions. Thank you Prof. Butković for everything you have done for me during these years. Thank you Brian, Prof. Zuckermann and Prof. Đuras for your help and time you invested in me!

Sincere thanks my mentors without who this thesis would not take place. Thank you for your kindness, patience and understanding.

Thank you, Aoki, for motivating me to become a veterinarian.

Finally, I'd like to recognize my own dedication, commitment and hard work throughout these years. I am grateful for my growth and all the achievements I have accomplished, as they reflect the resilience and the effort invested in myself and my studies.

List of the abbreviations:

- MUO: Meningoencephalitis of Unknown Origin
- ME: Meningoencephalitis
- GME: Granulomatous Meningoencephalitis
- NE: Necrotizing Encephalitis
- NME: Necrotizing Meningoencephalomyelitis
- NLE: Necrotizing Leucoencephalitis
- CSF: Cerebrospinal Fluid
- MRI: Magnetic Resonance Imaging
- WBC: White Blood Cells
- CNS: Central Nervous System
- NDS: Neurodisability Scale
- SRMA: Steroid Responsive Meningitis Arteritis
- DLA II: Dog Leukocyte Antigen II
- HR: Heart Rate
- RR: Respiratory Rate
- CRT: Capillary Refill Time
- DTH: Delayed Type Hypersensitivity
- TNCC: Total Nucleated Cell Count
- BBB: Blood Brain Barrier
- CA: Cytosine Arabinoside
- CRI: Constant Rate Infusion
- PLR: Pupillary Light Reflex
- CN: Cranial Nerve
- STT: Schirmer Tear Test
- FLAIR: Fluid Attenuated Inversion Recovery

Figures

Figure 1. Left: Cranial and spinal dura mater with olfactory bulb and nerve. Right: Brain in situ after removal of the cranial meninges. Cerebellum and medulla oblongata are visible. Left lateral view. (DONE et al., 2009).....	4
Figure 2. Left: Cerebrum and cranial dura mater. Dorsal view. Right: Isolated brain and all the cranial nerve roots at their attachments to the brain. Ventral view. (DONE et al., 2009)	4
Figure 3. The meninges (a: Skull, b: Dura mater, e: Arachnoid mater, f: Sub-arachnoid space filled with CSF, g: blood vessel, h: Pia mater, i: Connection of Pia mater with Cerebral cortex forming the Glia Limitans (SMOLLICH and MICHEL, 1992).....	5
Figure 4. Internal structure of the canine eye (MAGGS et al., 2018).....	7
Figure 5. Blood supply to the retina and optic nerve. A: Horizontal section of the eye showing the two origins of the retinal blood supply. B: The dual nature of the retinal blood supply: the choroid together with its capillary bed (choriocapillaris) and the large vessels on the retinal surface with its smaller arterioles and venules (MAGGS et al., 2018).....	8
Figure 6. Optic nerve, Optic disc and blind spot of a healthy eye. Haematoxylin and Eosin. Original magnification: top left 4x; top right: 10x; bottom left: 20x; bottom right: 40x. (Department of Anatomy, Histology and Embryology of the faculty of Veterinary Medicine of Zagreb. Courtesy of Lucija Devčić DVM PhD and Assoc.Prof. Snježana Kužir)	9
Figure 7. Classification of MUO.....	10
Figure 8. Section showing a characteristic perivascular cuff lesion around a blood vessel comprising an exclusively mononuclear inflammatory cell infiltrate (mostly lymphocytes and some macrophages) in the cerebellar white matter of a 4-year-old miniature Pinscher diagnosed with GME. Haematoxylin and Eosin. Original magnification: top left 4x; top right: 10x; bottom left: 20x; bottom right: 40x. (Department of Veterinary Pathology of the faculty of Veterinary Medicine of Zagreb, Courtesy of assist. Prof. Dorothea Huber and assoc. Prof. Ivan-Conrado Šoštarić-Zuckermann)	13
Figure 9. Left: Normal dog's fundus including the tapetal and non-tapetal parts. Right: Retinal atrophy, hyperreflectivity of the tapetum. Blood vessels are narrowed. (KELAWALA et al., 2016).....	14
Figure 10. Brain of a 3-year-old female chihuahua diagnosed with NME. In the left hemisphere a necrotic lesion in the grey matter is noted. (Department of Veterinary Pathology of the faculty of Veterinary Medicine of Zagreb. Courtesy of assist. Prof. Dorothea Huber and Assoc. Prof.Ivan-Conrado Šoštarić-Zuckermann)	14

Figure 11. Ocular GME/optic neuritis. Involvement of the optic nerves and chiasm can produce the clinical deficits of optic neuritis. Note the brownish discoloration of the cut surface of each optic nerve. The inset displays the optic chiasm revealing extensive perivascular infiltrates (TALARICO and SCHATZBERG, 2010).....	15
Figure 12. The cranial nerves and the lobes of the brain (BUDRAS and FRICKE, 1994)	19
Figure 13. Postcontrast sagittal T1-weighted MRI image of a dog with necropsy-confirmed disseminated GME. Note the multiple irregularly shaped, contrast-enhanced foci in the ventral brainstem (yellow arrow), caudal cerebellum (green arrow), and C1–C2 spinal cord (white arrow) (ADAMO et al., 2007).....	23
Figure 14. Sagittal T2- weighted image of the cranial cervical spinal cord of dog 9, showing poorly defined, irregular and diffuse hyperintensity (CHERUBINI et al., 2006).....	23
Figure 15. Transverse T2-weighted image of the brain, showing a midline shift towards the right (arrowheads) and hyperintense lesions affecting the left thalamus and left temporal and parietal lobes (arrows) (CHERUBINI et al., 2006).....	24
Figure 16. CSF tap (ELIAS and BROWN, 2008).....	24
Figure 17. Distribution of the sampled population according to their gender	30
Figure 18. Distribution of the sampled population according to their age.....	30
Figure 19. Distribution of the sampled population according to their body weight	30
Figure 20. Blood parameters of sampled population	31
Figure 21. Case 10: Complete resting mydriasis diagnosed with MUO. The lens is visible in both eyes. Both direct and consensual PLRs were absent. Both eyes are non-visual	32
Figure 22. Case 10: Identification of multifocal intra-axial lesions that appear hyperintense on T2 and FLAIR sequences, isointense on T1, and show extensive enhancement after contrast injection. These lesions are located in the left hemisphere, the optic chiasma + optic nerves, and the cerebellum	33
Figure 23. Case 9: Multifocal lymphoplasmacytic infiltrates are noted within the optic nerve. Haematoxylin and Eosin. Original magnification: Left: 10x; middle: 20x; right: 40x. (Department of Veterinary Pathology of the faculty of Veterinary Medicine of Zagreb. Courtesy of assist. professor Lidija Medven Zagradišnik and Assoc.Prof. Ivan-Conrado Šoštarić-Zuckermann)	34
Figure 24. Fundoscopy with indirect ophthalmoscopy. Left: Case 9. Right: Case 10.....	34

Tables

Table 1. Distribution of the sampled population according to their breed.....	31
Table 2. Clinical signs and examination results in patients included in the study.....	32
Table 3. Localization of CNS lesions.....	35
Table 4. Treatment and ophthalmological outcome of sampled population	36

INDEX

1. INTRODUCTION	1
2. REVIEW OF THE RESULTS OF PREVIOUS RESEARCH	3
2.1 The brain and its anatomy	3
2.1.1 Brain coverings: The meninges	5
2.2 The eye and its anatomy	6
2.3 Connection between the brain and the eye	7
2.4 Meningoencephalitis	10
2.4.1 Definition and origin.....	10
2.4.2 Pathogenesis.....	12
2.4.3 Clinical signs	15
2.4.4 Diagnosis and clinical assessment tools.....	16
2.4.5 Therapy	25
2.4.6 Prognosis	27
3. MATERIALS AND METHODS	28
4. RESULTS	30
5. DISCUSSION	37
6. CONCLUSION.....	41
7. REFERENCES.....	42
8. SUMMARY	47
9. SAŽETAK.....	48
10. CURRICULUM VITAE	49

1. INTRODUCTION

Meningoencephalitis of unknown origin (MUO) is a general term describing inflammatory changes of the central nervous system (CNS) for which non-infectious etiology is assumed. Meningitis means the inflammation of the meninges, together with the inflammation of the brain tissue it is called meningoencephalitis.

The absence of a clearly identified causative pathogen, along with the broad spectrum and variable combinations of clinical signs which overlap with other conditions add significant complexity to the diagnostic process. Furthermore, the definitive diagnosis requires histopathological examination of brain tissue, which can be performed post-mortem, further complicating efforts to confirm the disease during a patient's life. However, brain biopsies can be performed ante-mortem but the associated risks and potential complications often outweigh the benefits in most cases. Consequently, the diagnosis of MUO mostly remains presumed in a clinical setting (NESSLER et al., 2021).

The main mechanism of action of MUO is due to the white blood cells (WBC) leakage in the brain parenchyma due to a so far inexplicable damage to the blood brain barrier (BBB). The leakage triggers strong immune responses, leading to further damage to the CNS itself (ADAMO et al., 2007). Depending on the focal or multifocal localization of the lesions, a variety of clinical signs such as seizures, ataxia, head tilt, neck stiffness, blindness and obtundation happen as consequence (O'NEILL et al., 2005). These damages disturb the integrity of the CNS parenchyma, where contrast substance adheres and can then be seen in magnetic resonance imaging (MRI) or computed tomography (CT). These cellular infiltrates can be quantified in the cerebrospinal fluid (CSF). Therefore, the history and clinical signs, together with an MRI and CSF tap can suffice to diagnose MUO in dogs (NESSLER et al., 2021).

The treatment for MUO focuses on stabilizing the patient and long-term immunosuppressive therapy. Corticosteroids are the primary treatment, often combined with other immunosuppressive drugs to reduce side effects and improve outcomes. While many patients show initial improvement, relapses are common.

MUO is a severe condition with a guarded prognosis, where early diagnosis, breed, and neurological signs significantly impact survival rates. While some dogs respond well to treatment, many experience relapses or long-term neurological deficits (GONCALVES et al., 2024).

The purpose of this study is to examine the prevalence of ophthalmologic manifestations in dogs diagnosed with MUO that were admitted to the Internal medicine and Surgery clinic of the Faculty of Veterinary Medicine of Zagreb. Additionally, the study aims to assess both clinical and visual outcomes after the treatment of these patients. The hypothesis is that ocular manifestations associated with MUO occur at a relatively low incidence within the population of dogs affected by this condition.

2. REVIEW OF THE RESULTS OF PREVIOUS RESEARCH

2.1 The brain and its anatomy

The brain acts as the body's control center. It is the most complex organ of the body. It processes sensory information, regulates emotions, vital activities like breathing and heart rate, and controls movement and behavior. It also enables learning, memory, adaptation and survival instincts, ensuring an efficient adaptation to the environment. It is made up of neurons that communicate through electrical and chemical signals.

The brain is composed of the cerebrum, the brainstem and the cerebellum (MEYER, 1964) (Figure 1). The cerebrum is composed of two hemispheres (Figure 2). The right hemisphere controls the left side of the body, and the left hemisphere controls the right side of the body. Each hemisphere is composed of 4 parts called lobes: frontal, parietal, temporal and occipital lobes (BUI and DAS, 2023). Each of them having their own functions. Structurally, the CNS consists of gray matter and white matter. The gray is formed by the aggregation of the cell bodies of the neurons within the CNS. The white matter consists mainly of myelinated nerve cell processes or portions of processes inside the CNS (MEYER, 1964). In the brain, the gray matter is primarily located on the outer surface, forming the cerebral cortex. The white matter lies beneath the gray matter, connecting different regions of the brain and facilitating communication between them. In the spinal cord, the arrangement is reversed. The gray matter is positioned centrally, forming a butterfly or H-shaped structure, while the white matter surrounds it. This configuration allows the gray matter to process sensory and motor signals locally, while the white matter carries signals to and from the brain (MEYER, 1964). The olfactory bulb on the forebrain is responsible for processing the different scents detected by cells in the nasal cavity (Figure 1).

The brainstem is composed of the midbrain, the pons and the medulla oblongata. Through the foramen magnum of the skull, the medulla exits and extends to the spinal cord passing through all the vertebrae to carry the messages to and from the brain to the rest of the body (MEYER, 1964).

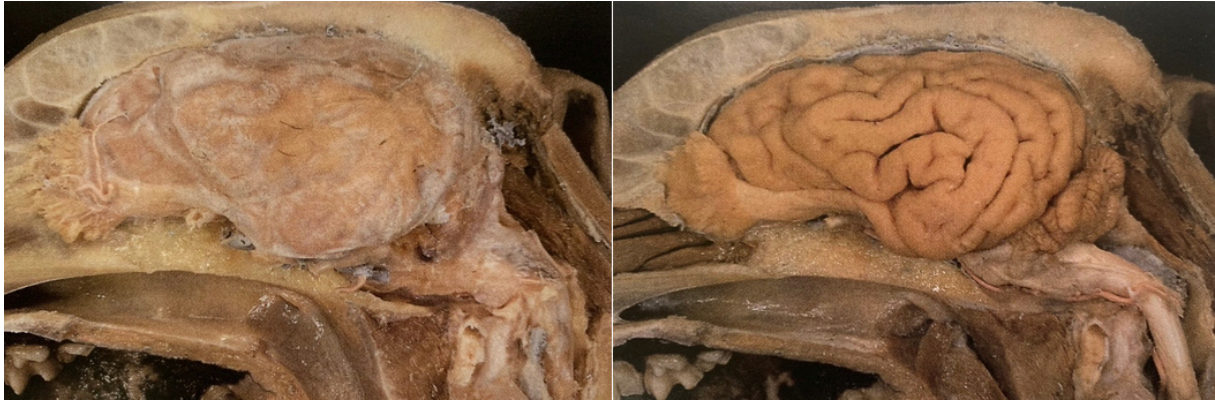

Figure 1. Left: Cranial and spinal dura mater with olfactory bulb and nerve. Right: Brain *in situ* after removal of the cranial meninges. Cerebellum and medulla oblongata are visible. Left lateral view. (DONE et al., 2009)

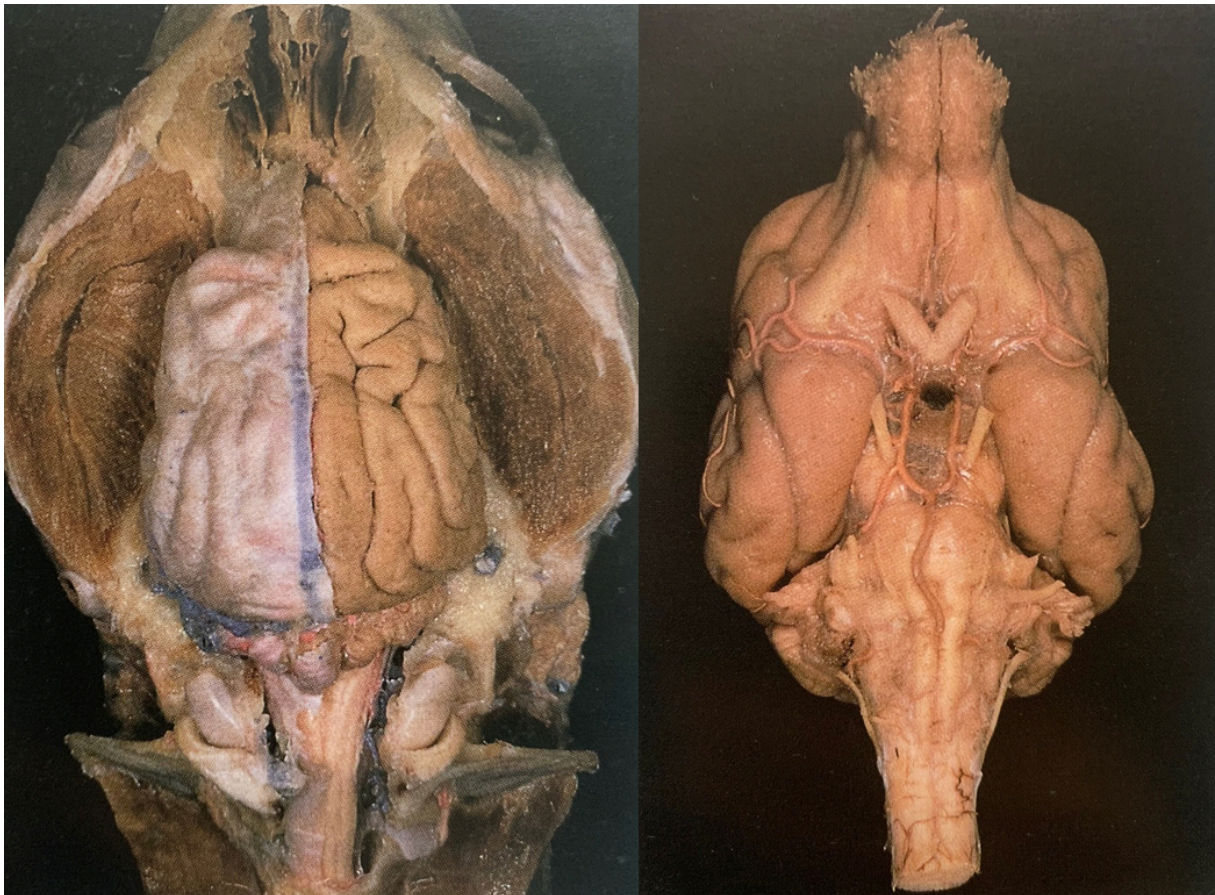

Figure 2. Left: Cerebrum and cranial dura mater. Dorsal view. Right: Isolated brain and all the cranial nerve roots at their attachments to the brain. Ventral view. (DONE et al., 2009)

2.1.1 Brain coverings: The meninges.

The brain is not only protected by the thick and strong bones of the skull but also by three thin tissue layers of connective tissue continuing along the spinal cord called the meninges coming from the ancient Greek “meninx” meaning membrane (Figure 3).

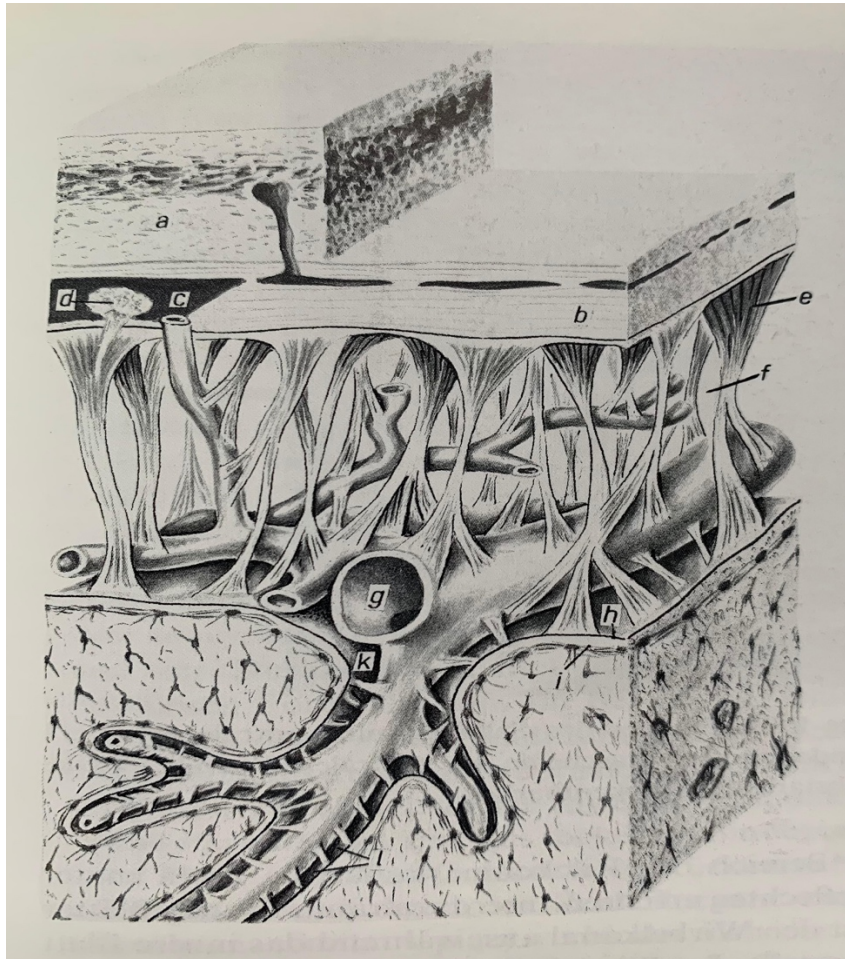


Figure 3. The meninges (a: Skull, b: Dura mater, e: Arachnoid mater, f: Sub-arachnoid space filled with CSF, g: blood vessel, h: Pia mater, i: Connection of Pia mater with Cerebral cortex forming the Glia Limitans (SMOLLICH and MICHEL, 1992)

The thickest and closest to the skull is called Dura Mater. It comes from the Latin word “tough mother”. It’s composed of two layers; the periosteal layer lining the inner part of the cranium and the meningeal layer just below (McCLURE, 1964).

The second layer is called the Arachnoid Mater which is a thin avascular layer of connective tissue making spiderweb-like projections towards the innermost layer, thus the name. Between those projections, in the sub-arachnoid space, CSF circulates acting as a cushion for the whole central nervous system (CNS) (brain and spinal cord) (McCLURE, 1964).

The innermost and third layer is called Pia Mater, coming from the Latin word “tender mother” since it’s the most delicate membrane which contours and adheres to the brain and spinal cord (McCLURE, 1964). The arachnoid membrane and pia mater are collectively referred to as the leptomeninges due to their delicate structure compared to the thick, fibrous dura mater (KÖNIG and LIEBICH, 2004) which is referred to pachymeninx (LIEBICH, 2019).

Subarachnoid cisterns are areas where the space between the arachnoid and pia mater is expanded. The cerebellomedullary cistern, the largest cistern, is found at the junction of the cerebellum and medulla. This cistern provides a site for CSF collection using a needle inserted through the atlanto-occipital membrane (EVANS and DE LAHUNTA, 2009).

2.2 The eye and its anatomy

The eye is considered to be the extension of the brain. The eyes continuously produce images that are quickly relayed to the brain. It’s an active organ constantly adjusting itself to produce the best image possible for the brain to process. The eye orbit in dogs is composed of different bones: frontal, lacrimal, zygomatic, sphenoid and palatine bone. Even though it doesn’t go all the way around the eyeball, this orbit protects the eyeball the same way the skull protects the brain.

The eyelids, along with the eyelashes and the nictitating membrane (or third eyelid), protect the eye by shielding it from particles and preventing scratches (GELATT, 2018). Tears, composed of water, oil, and mucus, keep the eye moist and create a protective film, secreted by glands and drained by the lacrimal puncta into the nose via the nasolacrimal ducts (GELATT, 2018) (Figure 4). The sclera, covered by the conjunctiva, provides structure, while the cornea focuses light onto the retina and protects the eye’s front (GELATT, 2018). The iris controls the pupil’s size, regulating light entry based on the surrounding brightness. The lens, located behind the iris, focuses light on the retina. It thickens to focus on nearby objects via ciliary muscle contraction and thins to focus on distant objects when the muscles relax (MAGGS et al., 2018) (Figure 4).

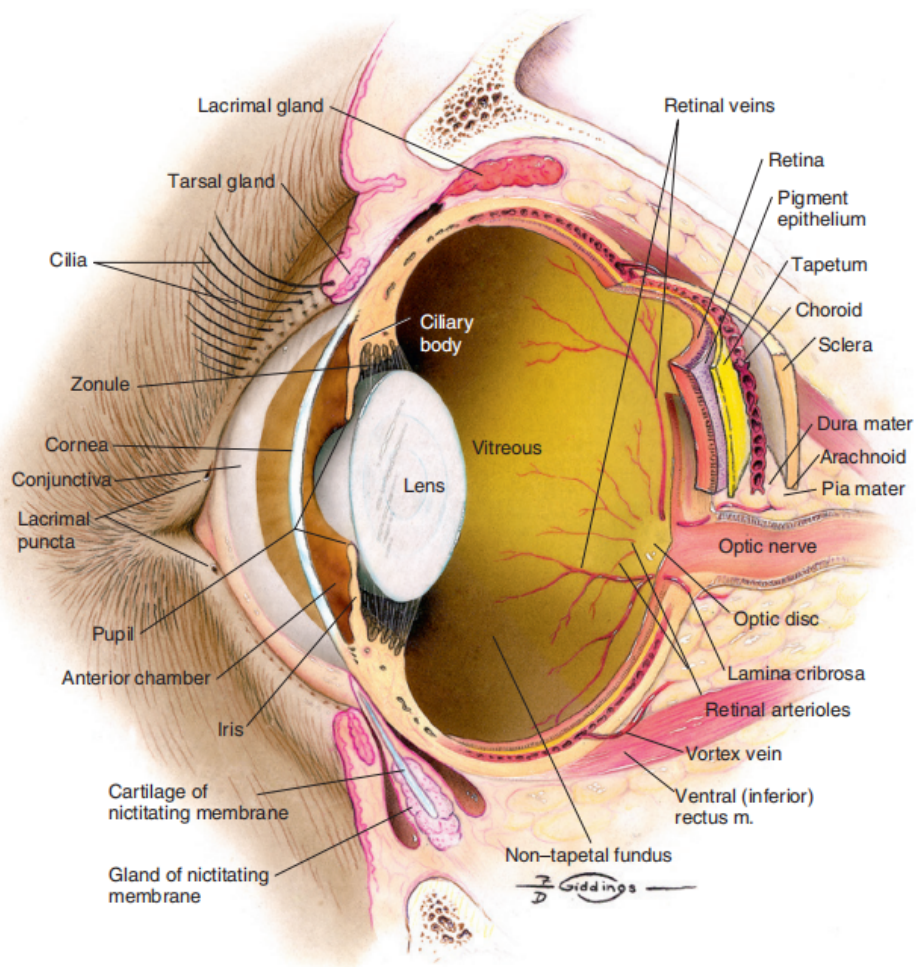


Figure 4. Internal structure of the canine eye (MAGGS et al., 2018)

2.3 Connection between the brain and the eye

The connection between the eye and the brain occurs via the optic nerve, which transmits visual signals from the retina to a specific area of the brain called the visual cortex, located at the back of the brain (in the occipital lobe). The following steps outline the visual pathway:

1. Retina: When light hits the retina, photoreceptors convert this light into electrical impulses (LIEBICH, 2019).
2. Optic nerve: These impulses are then sent via the axons of retinal ganglion cells, which form the optic nerve (Figure 6). This nerve carries the visual signals (KÖNIG and LIEBICH, 2004).

3. Optic chiasm: At the optic chiasm, fibers from each eye partially cross. This allows information from the left visual field to be processed by the right hemisphere of the brain, and vice versa (KÖNIG and LIEBICH, 2004).
4. Lateral geniculate nucleus: After the chiasm, the nerve fibers travel to the lateral geniculate nucleus in the thalamus, an important relay station (KÖNIG and LIEBICH, 2004).
5. The superior fibers of the optic radiation take a dorsomedial route through the parietal lobe toward the occipital cortex, forming Baum's loop (dorsal bundle). In contrast, the inferior fibers follow an anteroinferior path around the temporal horn of the lateral ventricle, then curve medially and posteriorly to form Meyer's loop, ultimately relaying to the lingual gyrus within the calcarine sulcus of the occipital lobe. (KAMALI et al., 2014).
6. Visual cortex: Finally, the signals are transmitted to the visual cortex where the image is reconstructed.

In summary, the eye captures light, converts it into electrical signals, and these signals are transmitted to the brain, which interprets them to form an image.

To understand to pathogenesis of MUO, it is very important to emphasize that all those nervous pathways from the eye (retina) to the occipital lobe of the brain are tightly connected with blood vessels bringing oxygen and nutrients to those structures (5).

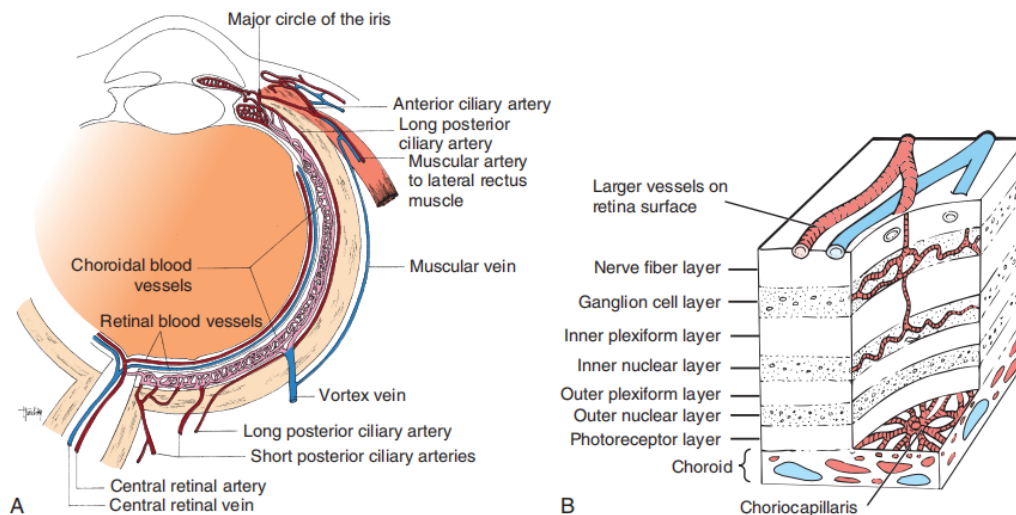


Figure 5. Blood supply to the retina and optic nerve. A: Horizontal section of the eye showing the two origins of the retinal blood supply. B: The dual nature of the retinal blood supply: the choroid together with its capillary bed (choriocapillaris) and the large vessels on the retinal surface with its smaller arterioles and venules (MAGGS et al., 2018)

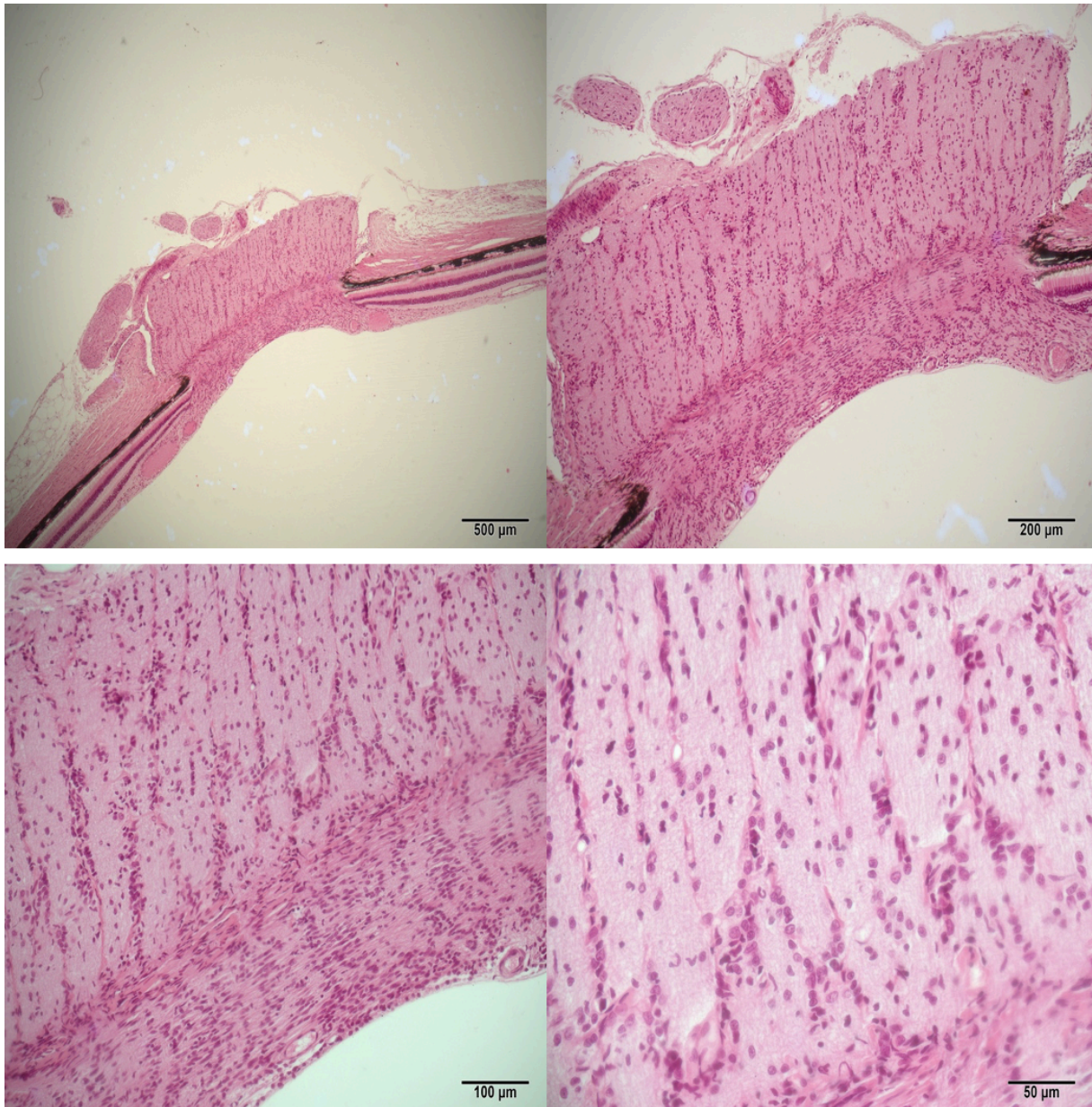


Figure 6. Optic nerve, Optic disc and blind spot of a healthy eye. Haematoxylin and Eosin.
Original magnification: top left 4×; top right: 10x; bottom left: 20x; bottom right: 40x.
(Department of Anatomy, Histology and Embryology of the faculty of Veterinary Medicine of Zagreb. Courtesy of Lucija Devčić DVM PhD and Assoc.Prof. Snježana Kužir)

2.4 Meningoencephalitis

2.4.1 Definition and origin

Meningoencephalitis (ME) exists when the inflammatory cells (WBC) are present in the brain and the fluid surrounding it and the meninges.

The causes of ME can be classified into two categories: infectious and non-infectious. Infectious ME can be caused by various pathogens. In dogs, especially adult animals, viruses, protozoa, rickettsia, parasites and fungi are more frequent causes of meningitis and encephalitis than are bacteria (LONG, 2018). CNS infections are relatively rare and typically occur when the CNS's protective barriers, that we have discussed previously, become compromised or weakened. Infections may also reach the CNS by spreading from other sites in the body, such as the bloodstream, sinuses, inner ear, vertebrae, or spinal discs. This spread can be facilitated by foreign material migration (grass awns, gunshots...), bite wounds, or other traumatic injuries located near the head or spinal regions (LONG, 2018).

Most often, when the causative organism cannot be found, and the patient's presumed diagnosis is Meningoencephalitis of Unknown Origin (MUO).

Depending on the histopathology, MUO is further divided in a subgroup called granulomatous meningoencephalitis (GME) and necrotizing encephalitis (NE) that is later divided in two forms: first being necrotizing meningoencephalomyelitis (NME) and second being necrotizing leucoencephalitis (NLE) (GONCALVES et al., 2024) (Figure 7).

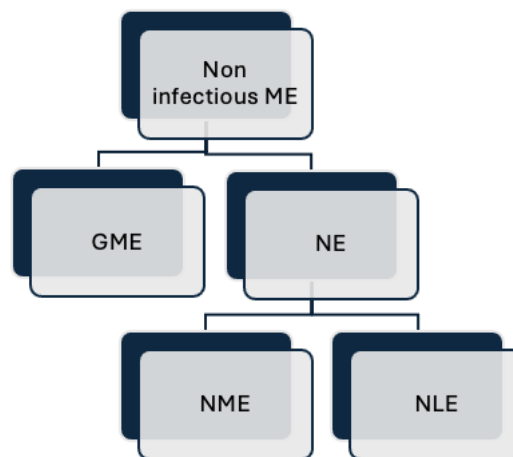


Figure 7. Classification of MUO

Various articles present differing classifications for the disease: some recognize specific forms such as Pug dog encephalitis or Greyhound meningoencephalitis, while others classify it more broadly, considering only GME and NME (JONES et al., 2024).

GME can manifest in three distinct clinical forms: the multifocal, the focal and the optic form. In the multifocal form, multiple areas of the central nervous system are involved simultaneously. With the focal form, the inflammation is localized to a specific region. And when the inflammation targets primarily the optic nerve, we categorize it as the optic form, which can potentially lead to vision impairment or blindness (O'NEILL et al., 2005). The multifocal form generally leads to acute and rapidly progressive signs; the focal form is insidious and with slower progression; the optic form leads to acute blindness (CORNELIS et al., 2018).

Even though dogs of any breed and age can be affected, young to middle aged, medium to small toy breeds are the most commonly affected (e.g., Pug, Maltese, Chihuahua, Yorkshire Terrier) (OSHIMA et al, 2023). Female dogs are believed to be more commonly affected compared to male dogs (CORNELIS et al, 2018).

The precise cause of non-infectious MUO remains uncertain, but it is believed to have a multifactorial origin. Research suggests a genetic component, particularly involving Dog Leukocyte Antigen (DLA) class II genes (DLA II), which have been identified in breeds like Chihuahuas, Maltese, and Pugs (OSHIMA et al., 2023; NESSLER et al., 2021). Serum glial fibrillary acidic protein (GFAP) concentrations were found to be significantly higher in pug dogs with NME compared with healthy controls and other breeds affected with NME, suggesting a breed-specific fragility of astrocytes (GONCALVES et al., 2024). In addition to genetic predisposition, unknown triggers, such as vaccinations or environmental influences, are also thought to play a significant role. NESSLER et al. (2021) propose a potential "hit-and-run" theory, suggesting that an infectious agent may trigger the inflammation but be cleared by the immune system before diagnostic tests can detect it. The dilemma is that absence of evidence is not evidence of absence (NESSLER et al 2021).

The so far absence of infectious agents, the effectiveness of immunosuppressive therapy, breed predisposition and genetic factors determine the categorization of MUO into immune-mediated diseases. This immune-mediated etiology has been suggested by KIPAR et al. (1998). They demonstrated that inflammatory cells within GME lesions consisted predominantly of MHC Class II antigen-positive macrophages and CD3 antigen-positive T lymphocytes. These findings are suggestive of a T cell-mediated delayed-type hypersensitivity (DTH), organ-specific auto-immune disease.

2.4.2 Pathogenesis

In MUO, the BBB, a protective barrier between the blood and CNS tissue, is, for some unknown reason, compromised. This breakdown allows immune cells and inflammatory mediators to enter the CNS, escalating the inflammation (ADAMO et al., 2007). Contrast enhancement on MRI is one sign of BBB breakdown, reflecting areas where the barrier is no longer intact and allowing contrast agents to leak into the brain parenchyma (ADAMO et al., 2007). Therefore, in GME, this leakage of WBC causes an angiocentric inflammation reaction characterized by perivascular cuffs of lymphocytes, macrophages and plasma cells in the parenchyma and meninges of the brain and spinal cord (ADAMO et al., 2007) (Figure 8). Immune cells then infiltrate the brain parenchyma, causing inflammatory changes such as gliosis (activation of glial cells), demyelination, and necrosis. Based on the distribution of these lesions, GME is classified in 3 morphological forms: disseminated, focal and ocular. In disseminated (multifocal) GME, the white matter of the cerebrum, caudal brainstem, cerebellum and cervical spinal cord is primarily affected. However, vascular lesions may also be found in grey matter, leptomeninges, and choroid plexus (ADAMO et al., 2007). Forebrain and brainstem signs are reported most frequently with multifocal GME, whereas forebrain signs alone are more frequent with focal GME (COATES and JEFFERY, 2014).

When neighboring perivascular cuffs coalesce, a solitary granuloma may form, representing the focal form of GME. Focal lesions most often happen in the brainstem, more precisely in the pontomedullary region and in the cerebral white matter (ADAMO et al., 2007). Ocular form of GME is the least commonly reported type of GME. An ocular form occurs with granulomatous cuffs initially involving the optic nerves (Figure 11), optic disc, or retina, resulting in lesions in the retinal or post-retinal portions of the optic nerves (MAEHARA et al., 2009). As discussed previously, the rich microvasculature of the retina makes it very fragile to any extent of inflammation. In fact, the scarce space between each layer of the retina and between the retina and the choroid does not allow any edema, influx of WBC or granulomatous cuff to go unnoticed. It leads to an acute onset of blindness and unresponsive to light stimulation as a result of unilateral or bilateral optic neuritis, uveitis and/or retinal hemorrhage or detachment (ADAMO et al., 2007). Vessels may be dilated, and focal hemorrhage may be present (ADAMO et al., 2007). The Figure 9 demonstrates a healthy optic nerve (on the left) and shows the optic disc of a MUO patient with ocular manifestations (on the right). Funduscopic examination may reveal a hyperemic, edematous disc.

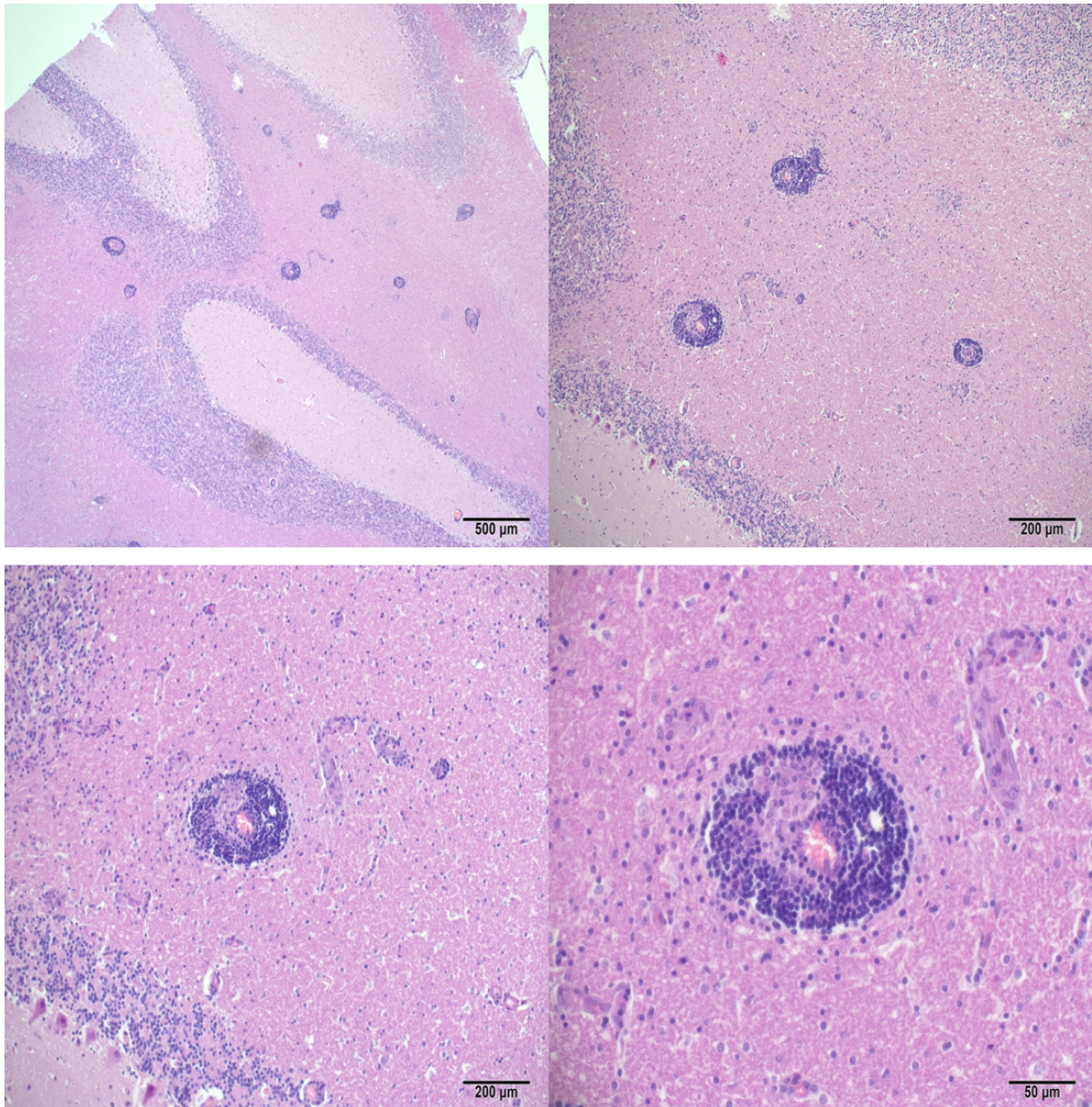


Figure 8. Section showing a characteristic perivascular cuff lesion around a blood vessel comprising an exclusively mononuclear inflammatory cell infiltrate (mostly lymphocytes and some macrophages) in the cerebellar white matter of a 4-year-old miniature Pinscher diagnosed with GME. Haematoxylin and Eosin. Original magnification: top left 4×; top right: 10x; bottom left: 20x; bottom right: 40x. (Department of Veterinary Pathology of the faculty of Veterinary Medicine of Zagreb, Courtesy of assist. Prof. Dorothea Huber and assoc. Prof. Ivan-Conrado Šoštarić-Zuckermann)

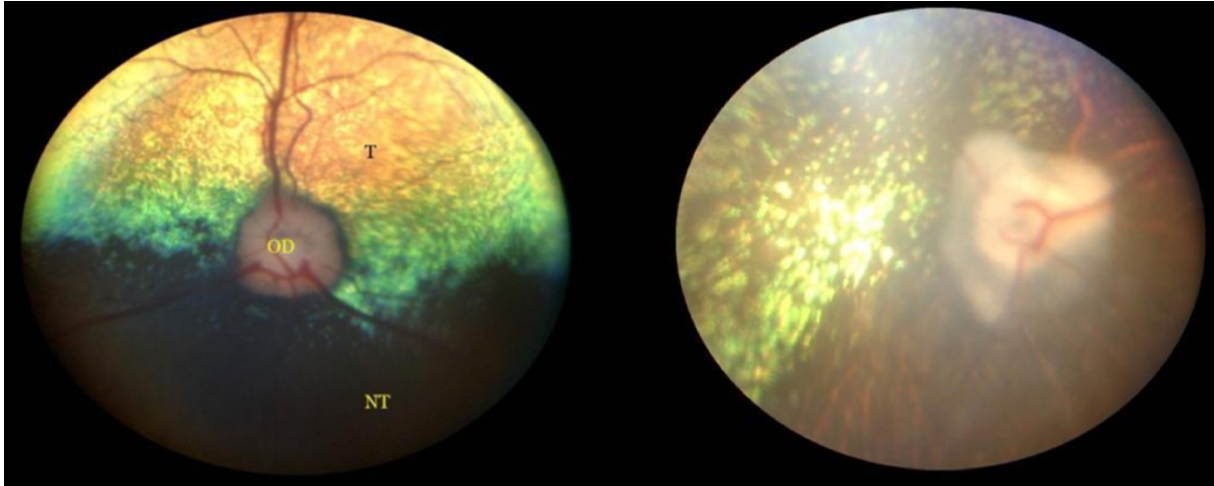


Figure 9. Left: Normal dog's fundus including the tapetal and non-tapetal parts. Right: Retinal atrophy, hyperreflectivity of the tapetum. Blood vessels are narrowed.
(KELAWALA et al., 2016)

Necrotizing Meningoencephalitis (NME) mainly affects the gray matter, causing necrotic lesions in the cerebral cortex (Figure 10). Pug dogs are commonly affected by NME (GONCALVES et al., 2024). Necrotizing Leukoencephalitis (NLE) predominantly affects the white matter in the forebrain and brainstem (COATES and JEFFERY, 2014)

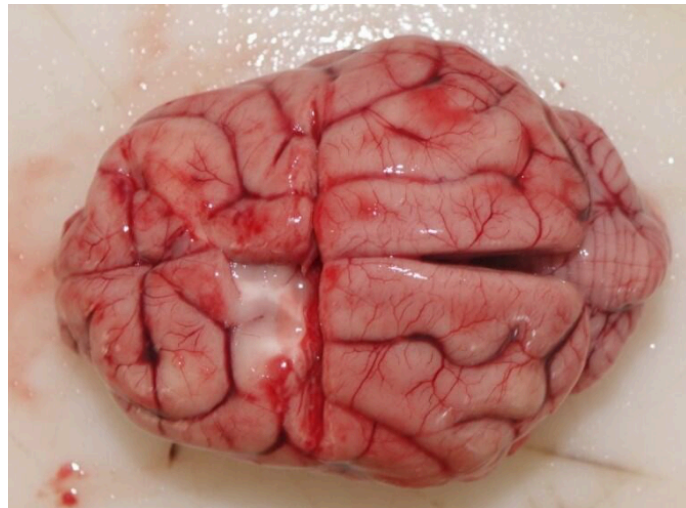


Figure 10. Brain of a 3-year-old female chihuahua diagnosed with NME. In the left hemisphere a necrotic lesion in the grey matter is noted. (Department of Veterinary Pathology of the faculty of Veterinary Medicine of Zagreb. Courtesy of assist. Prof. Dorothea Huber and Assoc. Prof. Ivan-Conrado Šoštarić-Zuckermann)

2.4.3 Clinical signs

The clinical signs of MUO can emerge suddenly, presenting as an acute neurologic crisis, or they may progress gradually over a span of weeks to months, becoming increasingly severe as the disease advances. Most often the clinical signs develop gradually over a few days. Common manifestations are (O'NEILL et al., 2005):

- Neurologic: seizures, obtundation, proprioceptive deficit, ataxia, pain and neck rigidity, muscle tremors, loss of consciousness...
- Ophthalmic: blindness, complete bilateral resting mydriasis...
- Vestibular: dizziness, loss of balance, or a pronounced head tilt, nystagmus...
- Locomotor: Paraparesis, paraplegia, compulsive circling, pain...

In these cases of MUO, systemic involvement is not expected, the disease is usually restrained to the CNS. Consequently, the physical examination and laboratory findings (hematology, biochemistry, electrolytes) will be normal in most of the affected dogs (PLATT and OLBY, 2004, COATES and JEFFERY 2014, DEWEY et al., 2016). Differently from SRMA, MUO could but rarely causes pyrexia (CORNELIS et al., 2018).

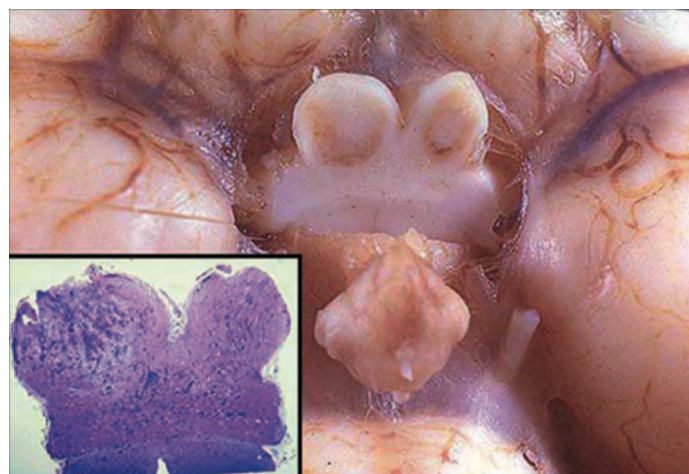


Figure 11. Ocular GME/optic neuritis. Involvement of the optic nerves and chiasm can produce the clinical deficits of optic neuritis. Note the brownish discoloration of the cut surface of each optic nerve. The inset displays the optic chiasm revealing extensive perivascular infiltrates (TALARICO and SCHATZBERG, 2010)

2.4.4 Diagnosis and clinical assessment tools

The breed, age, and clinical signs of an affected dog can guide a veterinarian towards a particular category of disease. However, these indicators alone are not sufficient for a definitive diagnosis and must be supported by additional tests to confirm the underlying condition. Therefore, a thorough anamnesis must be taken (including vaccinal status, antiparasitic treatments, suspected trauma or intoxication events...) and general physical exam must be done (HR, RR, temperature, mucous membrane colors, CRT...). The complete blood analysis can be done to evaluate the white blood cells status and exclude toxic (lead, organophosphates, ethylene glycol) and metabolic causes (hypoglycemia, hepatic encephalopathy, electrolyte imbalances). Ideally, the most common parasites affecting the CNS should be excluded: *Toxoplasma gondii*, *Neospora caninum*, *Anaplasma phagocytophilum/A. platys*, *Borrelia burgdorferi*, *Ehrlichia canis/E. Ewingii*, *Dirofilaria immitis*, *Angiostrongylus vasorum/A. cantonensis*.

Naturally, if neurologic clinical signs are present, a neurologic examination should be performed in order to localize the lesion(s). The main components to be evaluated during neurological examination are mental status and behavior, gait and postural reactions, cranial nerves, spinal reflexes, palpation and pain perception. Since there is no validated clinical scale available for the objective assessment of MUO severity GONCALVES et al., (2023) tried to design a neurodisability scale (NDS) to grade the clinical severity and determine its reliability and whether or not the score at the presentation correlates with outcome. The scale relies on attributing a numerical rating of dysfunction (0-3) in 7 categories giving an overall score of between 0 (normal) and a theoretical maximum of 21 (severe disability). The 7 categories being: ambulatory status, cerebral functions, cerebellar functions, brainstem functions, visual functions, postural abnormalities and seizures within the 7 previous days. The NDS has been used retrospectively in 100 dogs diagnosed with MUO and in 31 dogs prospectively. It showed good reliability prospectively in MUO patients but with this small population, no association with outcome could be identified.

Neurological examination

As the history is being taken, if ambulatory, the dog should be free in the consultation room in order to observe his reaction to the surroundings. The mental status needs to be evaluated through level of consciousness (alert, obtunded, stuporous, comatose) and content of

consciousness (quality of consciousness: delirium/dementia) (DEWEY et al., 2016). Behavioral abnormalities are identified by comparing the patient's behavior to expected behavior for animals of a similar breed and age. Behavioral changes may be an indication of forebrain (cortical) disease (DEWEY et al., 2016). The animal's attitude (eye and head position relative to the body, such as head tilt or head turn) and posture (body position in relation to gravity, including decerebrate rigidity, decerebellate rigidity, Schiff-Sherrington posture, or abnormalities like kyphosis, lordosis, scoliosis, plantigrade/palmigrade stance) provide important insights into the localization of CNS lesions (DEWEY et al., 2016). Therefore, these signs should be carefully observed and accurately identified. Gait will be observed to detect if there is any lameness, ataxia (proprioceptive, cerebellar or vestibular), paresis/paralysis or abnormal movements (tremor, myotonia, myoclonus) (DEWEY et al., 2016). If a dog suddenly loses its vision, the handling of the animal should be gentle, avoiding sudden movements or touches, as the dog is likely in shock from the sudden loss of sight. Consequently, the subsequent step, involving the assessment of postural reactions, must also be performed with caution. The proprioceptive positioning of the paws will help us differentiate orthopedic disease from a neurological disease. If the result is equivocal, further tests can be performed such as hemiwalking, wheelbarrowing, hopping and extensor postural thrust (DEWEY et al., 2016). One of the essential parts of the neurological examination is the evaluation of the cranial nerves (CN) (DEWEY et al., 2016) (Figure 12):

CN I: Olfactory nerve: Cover the patient eyes and present food beneath the food and watch the sniffing behavior. This test is not often performed.

CN II: Optic nerve: Before doing any tests, the size of each pupil should be assessed to detect the presence of anisocoria. Then a bright source of direct light will be presented to each eye to elicit a direct consensual PLR in each eye (+/- CNIII: parasympathetic function). Next, the menace response is being elicited; approach the side of the eye with a subtle hand movement that simulates a threat to elicit a blink response.

Avoid making exaggerated movements, as this could create airflow that triggers a blink reflex for reasons unrelated to the test, potentially resulting in a false positive. Initially, the patient can be observed negotiating obstacles in the examination room (e.g. chairs, tables and other objects) which can help to assess the sight.

Visual following can be evaluated with a cotton ball/toy in front of the patient to see if the patient's eyes and head follow the object. While assessing the pupillary light reflex (PLR), the dazzle reflex can also be tested. This involves briefly shining a bright light directly into the eye, causing a partial or complete closure of the eyelids in response. A positive dazzle reflex

suggests that the retina and optic nerve are functioning, even if vision is impaired or absent. Whereas a negative dazzle reflex may indicate severe retinal, optic nerve, or brainstem dysfunction. This test is useful in assessing neurological function when other visual reflexes (like the menace response) cannot be reliably performed.

CN III: Oculomotor, CN IV: Trochlear, CN VI: Abducent nerves: are cranial nerves that control the eye movement together. Then patient is observed for spontaneous strabismus (or nystagmus). Patient's head can be moved up and down or side to side to induce vertical or horizontal nystagmus respectively. By doing the oculocephalic reflex is being elicited: the physiological nystagmus has a fast phase in the direction of the eye movement. This test evaluates CN VIII (sensory) and III, IV, VI (motor). The CN VI is mediated by the corneal reflex which consists of touching the cornea with a cotton-tipped applicator moistened with saline in order to induce retraction of the globe.

CN V: Trigeminal nerve: the function of the motor portion is assessed through the observation (and palpation) of the masticatory muscles (temporalis and masseter muscles) and their symmetry. The sensory portion of the ophthalmic branch is evaluated by the corneal reflex (discussed above) and by touching the medial canthus of the eyelid region during palpebral reflex provocation. The maxillary branch can be tested by touching the lateral canthus during the palpebral reflex elicitation.

CN VII: Facial nerve: The face of the patient should be observed carefully to compare the right and left side of the lips, the eyes, the nostrils and ears. For the eyes, the palpebral reflex is the most helpful where the medial or lateral canthus of the eye is touched and in response the patient should close the eye thanks to this nerve. Lacrimation, as the parasympathetic function of this nerve, can be evaluated with a Schirmer Tear Test (STT). STT is a semiquantitative test that measures the production of tears. A specific paper strip is inserted under the lower eyelid for a minute. As the tear is being absorbed by the strip, the color of this strip changes. Normal values in dog are 12-25 mm/min (OLLIVIER et al., 2008).

CN VIII: Vestibulocochlear nerve: For cochlear portion, the patient should orient their ear and head towards a loud noise (e.g. whistle), because cochlear problems lead to hearing loss. If there are any signs of vestibular dysfunction (the vestibular portion), signs of head tilt, abnormal nystagmus and an ataxic broad-based stance is seen.

CN IX: Glossopharyngeal and CN X: Vagus nerves: The client should be asked about any history of dysphagia, regurgitation, voice change or inspiratory stridor. Gag reflex should be elicited by gently touching the back of the throat or the base of the tongue with a gloved finger or applicator stick.

CN XI: Accessory nerve.: The trapezius muscle receives motor input from this nerve, so any damage to the nerve may cause muscle atrophy. However, such nerve deficits are seldom identified in clinical practice.

CN XII: Hypoglossal nerve: For this nerve you should inspect the tongue for any asymmetry, atrophy or deviation. The patient usually immediately licks its nose after the gag reflex is elicited, if there is any deficit in this nerve, the patient will be able to lick only one side the nose

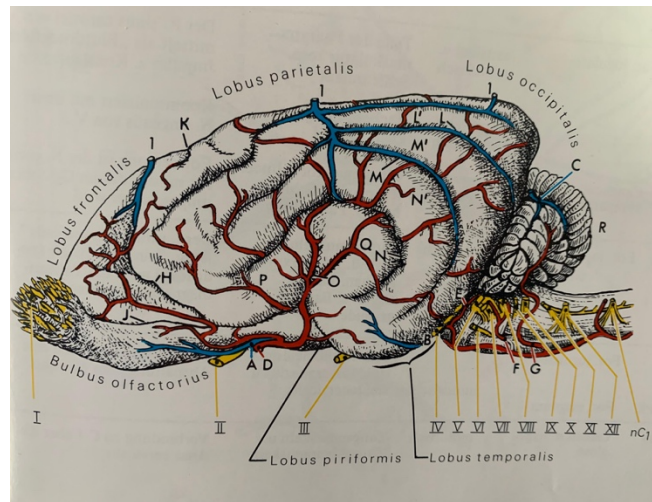


Figure 12. The cranial nerves and the lobes of the brain (BUDRAS and FRICKE, 1994)

Neurolocalization of CNS lesions in dogs is based on identifying clinical signs and their correlation with specific anatomical regions of the nervous system. It is often categorized as follow (DEWEY et al., 2016):

1. Forebrain Lesions: These typically present with behavioral changes, seizures, circling, and proprioceptive deficits on the contralateral side.
2. Brainstem Lesions: Manifestations include cranial nerve deficits, altered mentation, vestibular signs, and postural reaction deficits.
3. Cerebellar Lesions: Indicate hypermetria, intention tremors, and ataxia without paresis.
4. Spinal Cord Lesions: Divided into segments such as:
 - C1-C5: Tetraparesis or proprioceptive ataxia affecting all limbs.
 - C6-T2: Reduced reflexes in forelimbs and proprioceptive ataxia in hind limbs.
 - T3-L3: Proprioceptive ataxia or paresis restricted to hind limbs.
 - L4-S3: Flaccid paralysis or decreased reflexes in pelvic limbs.

According to COATES and JEFFERY (2024), when talking about MUO, the most common localization of the lesions are the following:

In GME: mainly the white matter of the cerebrum, brainstem, cerebellum and cervical spinal cord. The lesions are mostly multifocal but can occasionally be focal. Forebrain signs are common in focal GME while brainstem signs dominate in multifocal GME.

In NME: mainly the grey matter of the forebrain. Lesions often cause severe cortical necrosis with the clinical signs corresponding to forebrain lesions.

In NLE: mainly the white matter of the cerebrum and the brainstem.

MUO often results in multifocal neurolocalization, as lesions frequently involve multiple areas of the brain and spinal cord. This multifocal distribution is one of the key features differentiating MUO from more localized conditions such as neoplasia (PLATT and OLBY, 2004).

Ophthalmological examination

Besides the standard eye assessments included in the cranial nerve examination, additional specific tests can be conducted to gather more comprehensive information about the eyes and brain.

Both the anterior and posterior segments of the eye must be examined to confirm that all ocular components are normal. This requires thorough examination using a direct ophthalmoscope with a slit beam which is effective for this purpose. Aqueous, corneal and lens opacities or other issues can impair vision and may be the primary reason for the patient's visit (MAGGS et al., 2018).

Once diseases from the anterior chamber have been ruled out, we should examine the posterior segment, focusing specifically on the fundus (from the Latin word "fundus," meaning "bottom"). This examination, known as fundoscopy, should ideally be performed in a darkened room to achieve the clearest and brightest view of the fundus. To enhance visibility, it is helpful to use a mydriatic drug like tropicamide to dilate the pupil, allowing a thorough inspection of the fundus. A direct or indirect ophthalmoscope is then utilized to carefully assess the area. The appearance of the normal fundus varies considerably between dogs. This wide range of normality must be appreciated before abnormality can be detected (PETERSEN-JONES, 2007). The fundus consists of the optic nerve head, the retina, the superficial retinal vasculature, the choroid underlying the retina (including the tapetal area) and sometimes the underlying sclera can be visible (MAGGS et al., 2018). The optic nerve head is composed of the axons of ganglion cells, which converge at the lamina cribrosa and pass through the sclera to form the optic nerve.

As these axons converge, they acquire a myelin sheath, which in dogs occurs before reaching the lamina cribrosa, causing a slight elevation of the optic nerve head above the retinal surface. This also influences the shape of the optic nerve head, which can range from round to triangular. Additionally, in dogs, a complete or partial venous circle is often visible at the optic nerve head, with retinal vessels rising above the retinal surface before entering the elevated optic nerve head. The optic disc is white to pink because of myelin and capillaries being together. Any changes in size, in vascularity or in prominence of the nerve head should be recognized (MAGGS et al., 2008). The retinal vasculature varies in pattern and number of vessels. Some small breed dogs may have less extensive vasculature than large breed dogs. This should not be confused with blood vessel attenuation (PETERSEN-JONES, 2007).

Dogs have usually both tapetal and non-tapetal areas with an irregular junction (Figure 9). The tapetal region is located in the upper part of the retina and lies over a reflective layer called the tapetum lucidum, which is part of the choroid. The tapetum lucidum enhances vision in dim light by reflecting light back through the photoreceptor layer a second time (MAGGS et al., 2018). The tapetum has finely granular appearance and can be gold, blue-green or orange-ish (MAGGS et al., 2008) and appears bright and reflective during fundoscopy. The rest of the fundus (non-tapetal) is more homogenous and lies below the tapetal area, in the ventral part of the retina. It appears darker, typically reddish-brown or brownish gray depending on the degree of ocular pigmentation (PETERSEN-JONES, 2007). The non-tapetal retina receives less light reflection but contains a higher concentration of pigment, which helps absorb stray light and prevents it from scattering, contributing to sharper vision during daylight. The clinical significance of each one of these components should be well known in order to be able to recognize abnormalities of the fundus: retinal thinning results in tapetal hyperreflectivity, indicative of retinal degeneration (caused by i.e. retinal dysplasia, post-inflammatory changes, progressive retinal atrophy). The change in tapetal color from retinal thickening can reduce the reflection from the tapetal area (caused by i.e. retinal edema, retinitis). Vascular changes such as hemorrhage can be noticed at various layers (caused by i.e. trauma, coagulopathies, hypertension, inflammation). Changes in the superficial retinal blood vessel include narrower/thinner vessels (cause by i.e. anemia, post-inflammation changes, retinal degeneration), wider blood vessels (caused by i.e. hypertension, hyperviscosity), segmental dilation and constriction of vessels (caused by i.e. hypertension, inflammatory diseases). Retinal detachment can happen due to inflammation, hypertension, neoplasia, trauma... Optic disc changes are very common; it can be swollen and inflamed (then called papilledema) where

the margins can be blurred (Figure 9) due to optic neuritis. Additionally, the optic disc may show signs of hemorrhage (PETERSEN-JONES, 2007).

Additional diagnostic procedures

After the clinical examination, if MUO is suspected, two additional tests that are crucial for the diagnostic of MUO. These are advanced diagnostic imaging of the head which includes MRI or CT and CSF tap (O'NEILL et al., 2005). Both tests should be performed under general anesthesia since the dog has to be kept still for a prolonged period of time. This crucial detail allows the MRI, which is the preferred imaging modality, or the CT to acquire desired sequences and for the CSF tap, to diminish the possibility to damage the spinal cord. MRI is a non-invasive imaging technique used in both veterinary and human medicine to generate three-dimensional highly detailed images of the inside of the body, particularly useful for examining soft tissues, such as the brain, spinal cord, muscles, and internal organs. With a MRI of the dog's brain, the abnormalities indicating meningoencephalitis can be observed. The findings vary depending on the type of MUO (GME, NLE, NME) (CHERUBINI et al., 2006 and MAEHARA et al., 2009).

The most common MRI finding is hyperintense (bright) lesions on T2-weighted image, indicating areas of inflammation, oedema or necrosis. These lesions are usually multifocal and found in the brain parenchyma, with preference for white matter, especially in GME (Figure 10) (CHERUBINI et al., 2006 and MAEHARA et al., 2009).

WINDSOR et al. (2022) suggested a potential early clinical phenotype of necrotizing meningoencephalitis in genetically at-risk pug dogs on whose MRI, meningeal enhancement was identified in the dura mater and leptomeninges of pug dogs with NME. This meningeal enhancement is associated with histopathologically confirmed inflammatory infiltrates within the sulci and is most prominently observed in the cerebral sulci and the longitudinal fissure.

GME lesions often show variable contrast enhancement on T1-weighted images after the administration of gadolinium contrast. Enhancement can be focal or multifocal and is frequently associated with areas of active inflammation (TALARICO and SCHATZBERG, 2010).

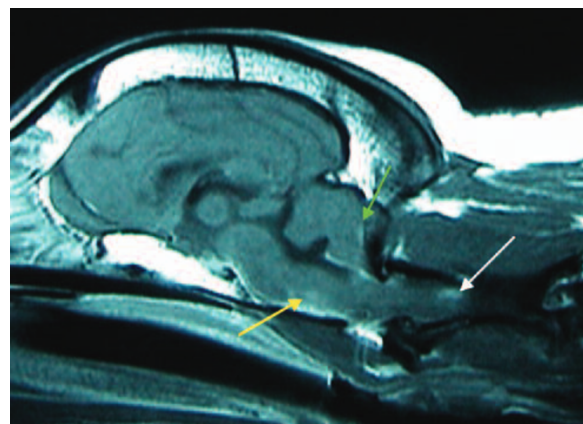


Figure 13. Postcontrast sagittal T1-weighted MRI image of a dog with necropsy-confirmed disseminated GME. Note the multiple irregularly shaped, contrast-enhanced foci in the ventral brainstem (yellow arrow), caudal cerebellum (green arrow), and C1–C2 spinal cord (white arrow) (ADAMO et al., 2007)

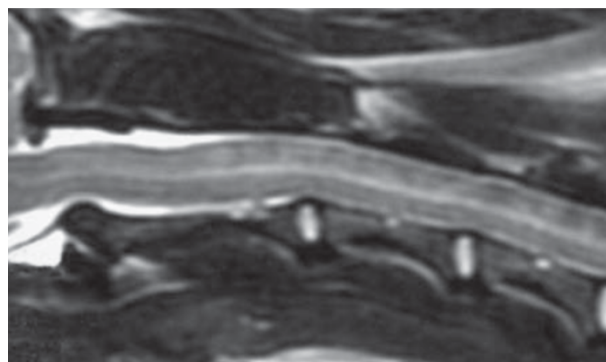


Figure 14. Sagittal T2- weighted image of the cranial cervical spinal cord of dog 9, showing poorly defined, irregular and diffuse hyperintensity (CHERUBINI et al., 2006).

In GME, lesions can involve the brainstem and cerebellum, (Figure 13) as well as the spinal cord in some cases (Figure 14). These areas appear hyperintense on T2-weighted images and may show a "patchy" or "multifocal" distribution.

A mass effect and midline shift can be observed in severe inflammation and swelling can cause a mass effect, shifting midline structures and compressing surrounding brain tissue, especially in cases with large lesions or cavitory necrosis like in NE (Figure 15) (CHERUBINI et al., 2006).

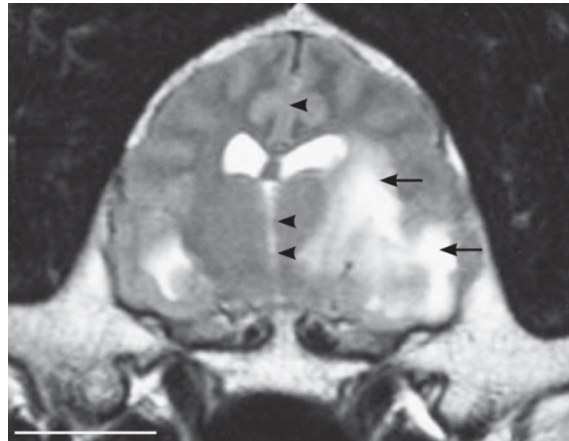


Figure 15. Transverse T2-weighted image of the brain, showing a midline shift towards the right (arrowheads) and hyperintense lesions affecting the left thalamus and left temporal and parietal lobes (arrows) (CHERUBINI et al., 2006)

While the patient is anesthetized, the neurologist will also perform a CSF tap (Figure 16). During the CSF tap, a small amount of this fluid is removed, using a long needle, and will be analyzed. The fluid will first be assessed macroscopically (color, transparency...). Later, the fluid will be examined under a microscope to assess what types of cells are present. The composition of the fluid will be tested to quantify the total nucleated cells count (TNCC) and protein concentration (O'NEILL et al., 2005).

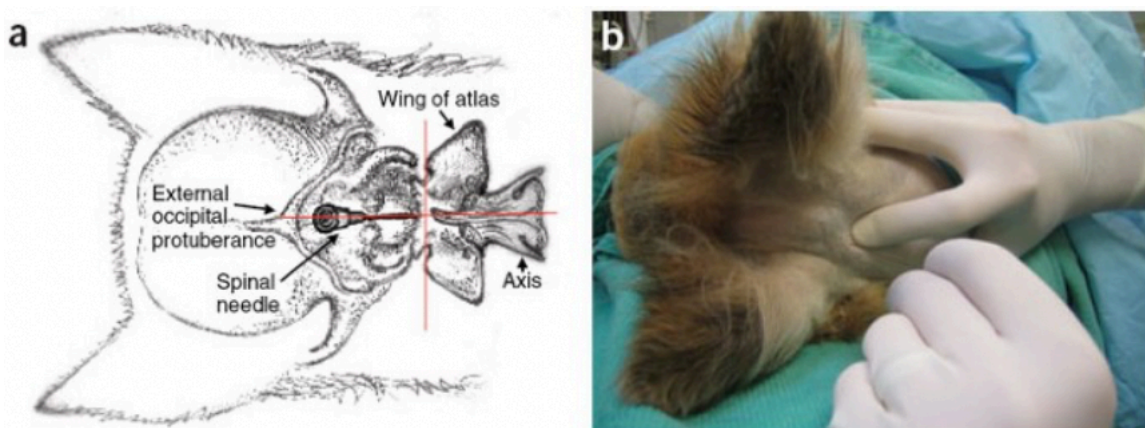


Figure 16. CSF tap (ELIAS and BROWN, 2008)

GRANGER et al. (2010) managed to gather fifty-six papers from 1962 to 2008, containing a total of 457 dogs in order to determine the predominant type of cell in the CSF of each dog in each category of MUO. They meticulously selected the ones that had the maximum amount of information to have the most objective results possible. In 104 GME cases, 34 MUO cases, and 37 NE cases, sufficient data was available to determine the predominant cell type (defined as constituting more than 50% of the total cell population). Lymphocytes predominated in 42% of GME cases and 71% of MUO cases. In NE cases, monocytes and lymphocytes were equally represented, while neutrophils were the primary cell type in fewer than 10% of cases across all groups.

To establish a definitive diagnosis of MUO, a CNS biopsy is required; however, this procedure is highly costly and carries the risk of irreversible brain damage, potentially resulting in further neurological decline. Consequently, MUO diagnosis is typically based on findings from neurological examinations, MRI scans, and CSF analysis, following the exclusion of infectious diseases. According to GRANGER et al. (2010), the criteria for antemortem diagnosis of MUO include:

- Dogs aged over 6 months
- MRI evidence of multiple, single, or diffuse intra-axial hyperintensities on T2-weighted imaging
- CSF analysis showing pleocytosis with more than 50% mononuclear cells
- Elimination of infectious disease as a cause.

2.4.5 Therapy

The initial approach to treatment focuses on stabilizing the patient according to the severity of the neurological impairment, followed by maintenance therapy. If seizures are present, anticonvulsant medications are required (BEASLEY and SHORES, 2023). Stabilization may involve providing supplemental oxygen for hypoxemia, administering crystalloid or colloid fluids to support cerebral blood flow and manage low blood pressure, and using osmotic agents (such as mannitol or hypertonic saline) to alleviate increased intracranial pressure (COATES and JEFFERY, 2014).

Since MUO is considered an autoimmune condition, treatment mostly involves immunosuppressive medications. The primary drugs used are corticosteroids, particularly prednisolone, at immunosuppressive doses (2 mg/kg/day), or dexamethasone. The initial high

doses are gradually tapered based on the patient's response every 4 weeks (COATES and JEFFERY, 2014), aiming to reach the lowest effective dose to control clinical signs. Although many dogs show good initial improvement, clinical signs frequently relapse as the steroid dose is tapered or over time, making long-term prognosis guarded (O'NEILL et al., 2005). After relapsing, the prognosis for permanent recovery is poor. The extended use of high-dose corticosteroids can lead to significant side effects, including gastrointestinal ulcers, pancreatitis, and iatrogenic hyperadrenocorticism (ADAMO et al., 2007). To mitigate these risks, second-line immunosuppressive agents such as azathioprine (Imuran®), cyclosporine (Atopica®), and leflunomide are often used in combination with corticosteroids (O'NEILL et al., 2005). These additional drugs help reduce the corticosteroid dose, thereby minimizing its adverse effects (O'NEILL et al., 2005). However, these immunosuppressive agents come with their own potential risks, including myelosuppression, hepatotoxicity, and gastrointestinal disturbances. Regular monitoring of blood work and serum biochemistry is recommended to detect any early signs of toxicity (O'NEILL et al., 2005).

For their immunosuppressive effects and their ability to cross the BBB, some antineoplastic drugs have commonly been used together with corticosteroids, such as Cytosine Arabinoside (CA). It acts on mitotically active cells by inserting itself into DNA molecules, causing premature chain termination. The typical administration involves subcutaneous injections of 50 mg/m² twice daily for 2 consecutive days, combined with ongoing prednisolone therapy. This regimen is repeated every 3 to 4 weeks for 3 to 4 cycles depending on the patient results (O'NEILL et al., 2005). The interval between treatment cycles is then gradually extended by 1 week at a time, eventually reaching a 6-week cycle interval (O'NEILL et al., 2005; ADAMO et al., 2007).

Radiation therapy can be considered alternatively for focal GME. However mixed opinions exist since delayed (from 3 weeks to 6 months up to years) adverse reactions, such as brain necrosis, exist. According to ADAMO et al., (2007): "The risk for late delayed effects increases with the size of each radiation fraction and with a higher total dose".

ADAMO et al. (2007) and COATES and JEFFERY (2014), suggest that cytarabine, procarbazine, and cyclosporine treatment for GME may result in better long-term outcomes than those previously reported with corticosteroids treatment alone. However, recently, JONES et al. (2024) conducted a study comparing the rates of neurological improvement in 69 dogs diagnosed with MUO, treated either with corticosteroids alone or in combination with continuous rate infusion (CRI) of cytarabine. The results showed no significant differences in treatment outcomes between the 2 groups. Antibiotics may be required to address potential

underlying infections and to prevent secondary infections that could exacerbate the autoimmune condition.

2.4.6 Prognosis

MUO is fatal if not treated promptly and with the appropriate treatment and, even then, its prognosis is guarded. GONCALVES et al. (2024) conducted a study on 447 dogs diagnosed with MUO. They identified clinical prognostic variables within observed population: 82% (366/447) of dogs survived to discharge and 63.5% (284/447) were alive at 6 months; 36% of the latter (103/284) had persistent neurological deficits. Certain factors, including breed (with pugs being less likely to survive compared to other breeds), the presence of epileptic seizures, paresis, and higher NDS at diagnosis, were found to be negatively correlated with survival at six months. According to GONCALVES et al. (2024): “Previous studies have identified that younger age at diagnosis and early diagnosis (within 7 days of development of clinical signs) are associated with longer survival times”. In contrast, seizures and obtundation are linked to shorter survival times (GONCALVES et al., 2024). The study also revealed that nearly half of the dogs that survive the initial treatment and are discharged experience a relapse of clinical signs (GONCALVES et al., 2024). Patients that survive the initial stage of the disease tend to have a more stable course and respond at least partially to treatment. Survival rates in dogs with MUO are influenced by several factors, including the type of meningoencephalitis and the clinical presentation. Dogs with localized focal lesions tend to have a more favorable prognosis compared to those with widespread multifocal disease (GONCALVES et al., 2024).

A strong indicator of prognosis is the dog’s response to treatment. Dogs that show significant improvement in MRI findings and CSF analysis after three months of therapy generally have a favorable long-term survival. Conversely, if there is minimal or no response within this initial three-month period, the prognosis remains guarded.

3. MATERIALS AND METHODS

This retrospective study aims to investigate the prevalence of ophthalmologic manifestations, and clinical and visual outcomes after the treatment of dogs diagnosed with MUO. This research has been approved by the Ethical committee of the Veterinary Faculty of the University of Zagreb (Klasa: 640-01/23-02/12; ur. br.: 251-61-41-23-01). The medical records of the Clinic for Surgery, Ophthalmology and Orthopedics and the Clinic for Internal Medicine were searched with the aid of the VEF Protocol archives database in the period from the 1st January 2022 to the 15th of July 2024.

For this study, inclusion criteria were:

- Presence of neurologic abnormalities compatible with MUO (diagnostic procedures including anamnesis of the animals)
- Age of the patients between 6 months and 8 years
- A positive response to the immunosuppressive therapy
- A written consent from each owner

Excluding criteria were:

- Insufficient documentation at admission
- Insufficient follow-up data

The neurological examinations were performed either at the Clinic for Internal Medicine or at the Clinic for Surgery, Ophthalmology and Orthopedics where the ophthalmological examinations were taking place. The results of the fundoscopies which were performed, and the histopathological slides of an enucleated case have been used for this study. The results of this study did not distinguish between bilateral and unilateral ophthalmological clinical signs, nor did they consider whether the neurological signs were confined to one, two, or all four limbs. As a result, cases where clinical signs were limited to a single eye or limb were automatically categorized as deficient or unhealthy.

The data obtained from each patient includes:

- Signalment (breed, age, body weight and gender)
- The history and the reason of the admission of the dog
- Results from physical examination
- Neurologic deficits
- Ophthalmologic deficits
- Additional advanced diagnostic procedures performed
- Duration and progression of the deficits and the response to therapy
- Outcome of the patient and the remaining sequelae

This data has been analyzed through Microsoft Excel for descriptive statistical analysis.

4. RESULTS

Based on inclusion criteria, this study includes 10 dogs of different breed, age and gender who were admitted to the Clinic for Internal Medicine.

Among the 10 dogs diagnosed with MUO included in this study 70% were females and 30% were males (Figure 17).

Gender distribution

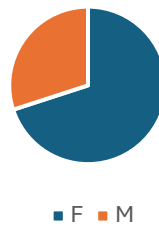

Figure 17. Distribution of the sampled population according to their gender
The age varied from 2 to 7,5 years old. The majority of them were close to 5 years, which came out to be the mean age of the patients presented in our study ($5 \pm 2,5$ years) (Figure 18).

Age distribution

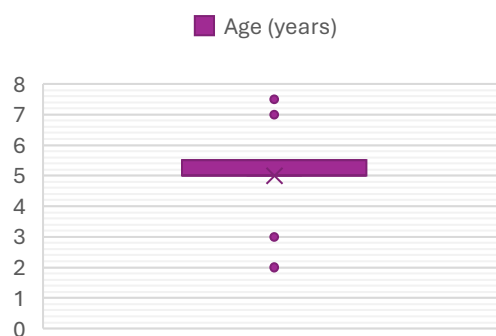


Figure 18. Distribution of the sampled population according to their age
The Figure 19 show the weight range of the patients which varied from 2,9kg to 12,5kg making a mean of 6,86kg.

Weight distribution

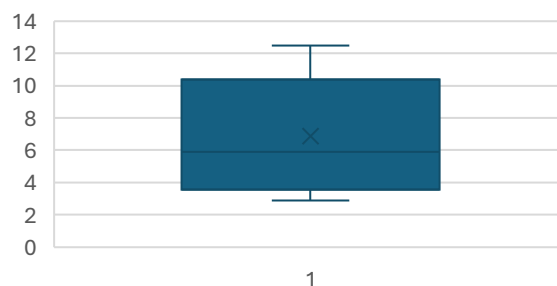


Figure 19. Distribution of the sampled population according to their body weight

Breed presentation of the patients is demonstrated in the Table 1. Three of the dogs included in this study were of the Maltese breed.

Table 1. Distribution of the sampled population according to their breed

Breed	Number of patients
Maltese	3
Chihuahua	1
French Bulldog	1
Cavalier King Charles	1
Pinscher	1
Miniature Schnauzer	1
Poodle	1
Mixed	1

At the initial examination, the total leukocytes, CRP, albumin and total proteins in all the patients were measured and are presented in Figure 20. The normal reference range for total leukocytes is $6-17 \times 10^9/L$, for CRP is below 10mg/L, for albumin is 22-44g/L and for total proteins is 52-82g/L. The serum was hemolytic in 5 out of the 10 patients.

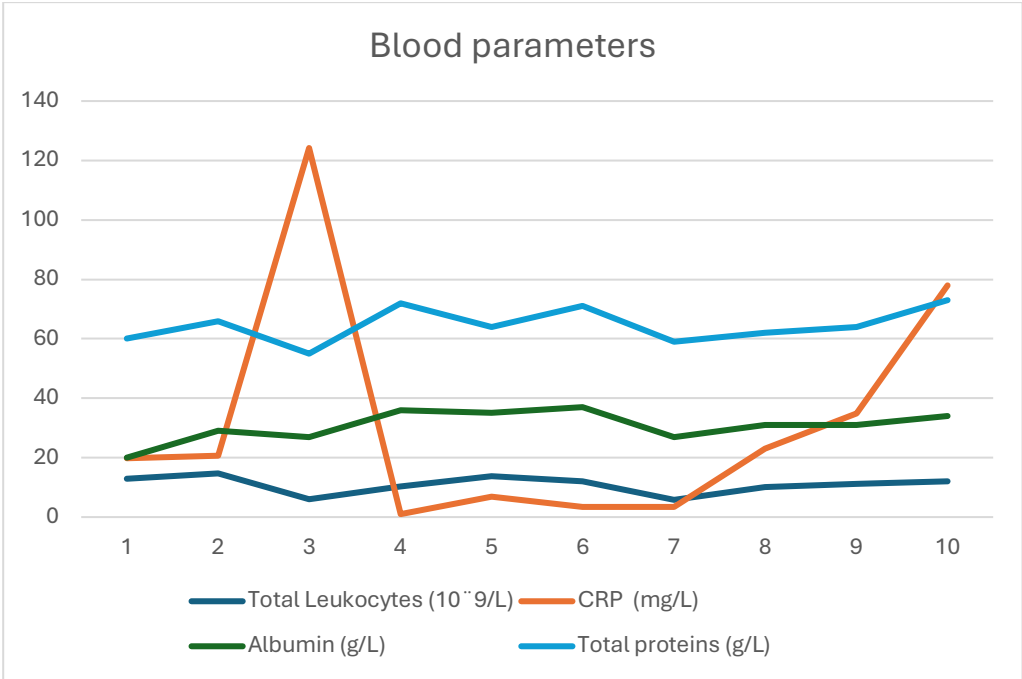


Figure 20. Blood parameters of sampled population

The clinical signs and results of diagnostic tests and examinations are presented in the Table 2. Resting mydriasis and absence of menace response were a very common findings together with PLR absence (Figure 21).

Table 2. Clinical signs and examination results in patients included in the study

Ophthalmological Clinical signs	Number of patients	Total patients examined
Visual impairment	10	10
Menace response absent	10	10
Resting mydriasis	6	10
PLR absent	5	10
Palpebral reflex absent	2	10
Fundoscopic changes	3	4 (np in the rest)
Neurological Clinical Signs		
Proprioceptive deficit	8	10
Neck stiffness	7	10
Vestibular signs (head tilt)	6	10
Unconscious/Depressed/Disoriented	8	10
Ataxia	8	10
Strabismus and/or Nystagmus	5	10
Seizure	2	10
MRI lesions	7	7 (np in the rest)
Cerebellar herniation	7	7
CSF tap abnormal	3	3 (np in the rest)
Parasite testing negative	6	6 (np in the rest)

np: not performed




Figure 21. Case 10: Complete resting mydriasis diagnosed with MUO. The lens is visible in both eyes. Both direct and consensual PLRs were absent. Both eyes are non-visual

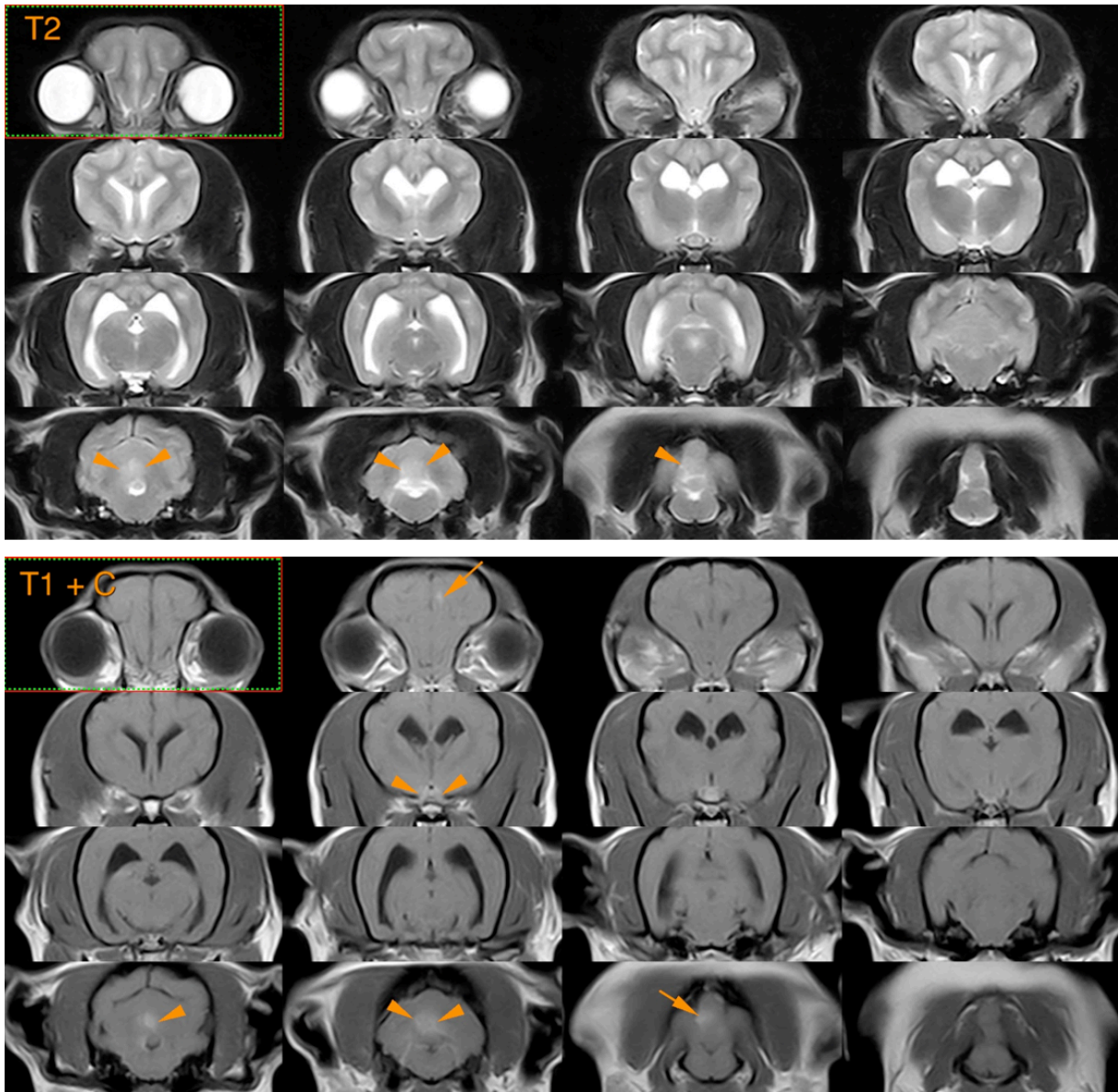


Figure 22. Case 10: Identification of multifocal intra-axial lesions that appear hyperintense on T2 and FLAIR sequences, isointense on T1, and show extensive enhancement after contrast injection. These lesions are located in the left hemisphere, the optic chiasma + optic nerves, and the cerebellum

Out of 3 cases in which CSF tap was performed, 2 of the obtained samples had blood contamination. All the samples had elevated TNCC and elevated protein concentration. The detail identification of the cells was appreciated in only one case where lymphocytes and monocytes were predominant. Additionally, the histopathological results from the enucleated eye of case 9 showed lymphoplasmacytic infiltrates in the optic nerve.

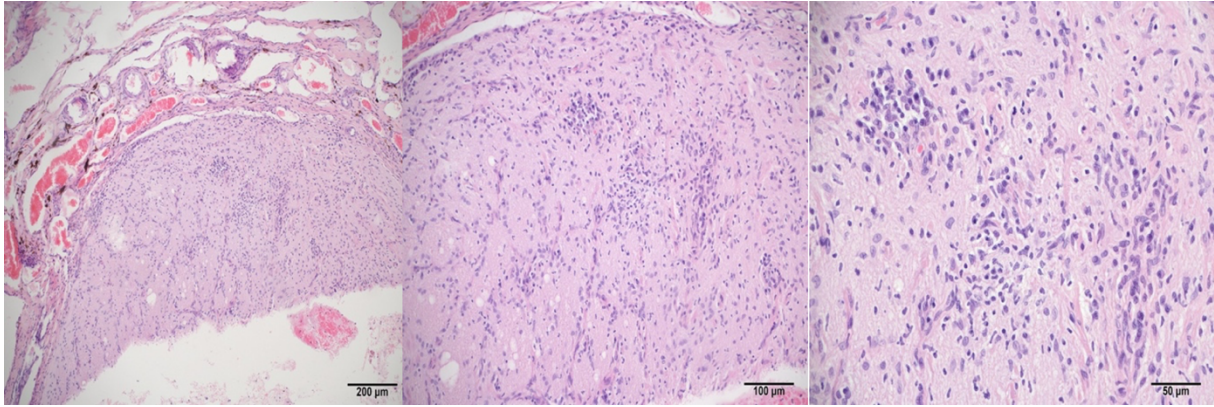


Figure 23. Case 9: Multifocal lymphoplasmacytic infiltrates are noted within the optic nerve. Haematoxylin and Eosin. Original magnification: Left: 10x; middle: 20x; right: 40x. (Department of Veterinary Pathology of the faculty of Veterinary Medicine of Zagreb. Courtesy of assist. professor Lidija Medven Zagradišnik and Assoc.Prof. Ivan-Conrado Šoštarić-Zuckermann)



Figure 24. Fundoscopy with indirect ophthalmoscopy. Left: Case 9. Right: Case 10.

In case 9, optic neuritis has been demonstrated recognized by the optic nerve swelling, loss of physiological cup and indistinct disc. Petechial hemorrhages are also present (Figure 24). The Figure 23 shows the histopathological slide of the enucleated eye of case 9 where lymphoplasmacytic infiltrates are noted within the optic nerve.

The picture of the fundus of case 10 has been taken after treatment (Figure 24). Segmental hyperreflectivity and pigment deposits in retinal pigmented epithelium are noted. The optic nerve head is smaller and darker. The eye is non-visual.

Table 3 shows the localization of lesions found on the MRI images of the patients.

4 of the 7 patients who had performed MRI had cerebellar herniation (Table 3) among which 2 of them died. All the patients who had performed MRI had multifocal lesions in the CNS (Figure 22)

Table 3. Localization of CNS lesions

Case	Lesion localization on MRI
3	Cerebrum, brain stem, meninges, spinal cord C6-T2, (+Cerebellar herniation)
4	Cerebellum, brainstem, occipital region, thalamus, corona radiata (+Cerebellar herniation)
5	Cerebrum + spinal cord C1-C5 (+Cerebellar herniation)
6	Cerebellum (+Cerebellar herniation)
8	Optic nerve, brainstem, spinal cord C1-C5
9	Cerebrum and spinal cord C1-C5
10	Optic chiasma, optic nerve and cerebellum

After the treatment, 80% of the patients survived to the date of writing this thesis. Among them 30% of the patients ended unilaterally blind, 20% ended up fully blind and 30% gained their vision back. 7 patients out of 10 have been treated with standard corticosteroid for MUO (CORNELIS et al., 2019), 3 patients were additionally treated with Cytosine Arabinoside (Cytozar®) (LOWRIE et al., 2016) and 1 patient was additionally treated with Cyclosporine (Ciklosporin Alkaloid) (PAKOZDY et al., 2009). One of the patients received a treatment for increased intracranial pressure (Mannitol 10% HZTM), and 3 patients had antibiotic therapy with Trimethoprim-sulphadiazine instituted for the treatment of secondary infection. The treatment of each case and their ophthalmological outcome is demonstrated in the Table 4.

Table 4. Treatment and ophthalmological outcome of sampled population

Cases	Treatment	Ophthalmological outcome
1	Corticosteroids + Cytozar ® + Enrofloxacin	Blind (unilateral)
2	Corticosteroids + Trimethoprim	Visual
3	Corticosteroids + Cyclosporine	Blind (unilateral)
4	Corticosteroids + Trimethoprim	Dead
5	Corticosteroids + Mannitol	Dead
6	Corticosteroids + Cytozar. ® + Cyclosporine	Visual
7	Corticosteroids + Cyclosporine	Blind (unilateral)
8	Corticosteroids + Trimethoprim	Visual
9	Corticosteroids	Blind
10	Corticosteroids + Cytozar ®	Blind

5. DISCUSSION

This study explored the prevalence of ophthalmologic manifestations in dogs diagnosed with MUO. It also observed the clinical and visual outcome of each patient. Many of the findings correspond with previous studies.

In our study, females were more represented than males in 70% against 30% respectively. This finding is in accordance with most of the articles about MUO such as with O'NEILL et al. (2005), TALARICO and SCHATZBERG (2010), COATES and JEFFERY (2014), CORNELIS et al. (2019) among others.

COATES and JEFFERY (2014) mentioned that “dogs aged between approximately 3 and 7 years are most commonly affected by all subtypes of MUO”. This statement coincides with the mean of the ages of the patients involved in this study, being 5 years old, exactly like O'NEILL et al. (2005) and CORNELIS et al. (2019) mentioned as well.

In this study all the patients were small breed dogs, the average weight of the dogs was 6.86 kg, which indeed corresponds to the small-sized dog category. This finding supports the deduction that the disease predominantly affects small breeds. Similar observations have been reported by O'NEILL et al. (2005) and COATES and JEFFERY (2014). The small breed that is over-represented in this study is Maltese (3 patients) (Table 1), which is one of the most affected breeds according to TALARICO and SCHATZBERG (2010) and OSHIMA et al. (2023).

As PLATT and OLBY (2004), COATES and JEFFERY (2014) and DEWEY et al. (2016) mentioned, systemic signs are uncommon because the disease is limited to the central nervous system and bloodwork often show no abnormalities. The blood parameters that we selected confirm these statements: In all the cases, the albumin was within the reference range (except for case number 1 which is borderline with the lower reference, and clinically estimated as not being relevant). The total protein and the total leukocyte count for each case were within the reference ranges as well. However, CRP was much more fluctuant. In 6 cases, the CRP was increased compared to the normal reference. In 4 of the cases the CRP was within the reference range. However, in 2 out of those 4 cases, concomitant disease was observed, and therapy was given for it, which could interfere with the level of the CRP. In total, 3 patients had concomitant diseases that could influence the concentration of CRP in their blood: the case number 3 had a very increased level of CRP, which was probably the consequence of a concomitant infection with babesiosis, the case number 4 had otitis and received non-steroidal anti-inflammatory drugs and the case number 9 received corticosteroid therapy 10 days before admission for discopathies.

GRANGER et al. (2010), tried to determine the predominant type of cell in the CSF of patients diagnosed with MUO. They concluded that there was a prominence of mononuclear cells (lymphocytes and monocytes). This is in agreement with the cells found in one of our cases where mononuclear cells were abundant. In the histopathological slides of the enucleated eye of case 9, the same findings were discovered with optic neuritis (Figure 23).

Visual impairment was present in all our cases. Naturally the menace response was absent in all the cases as well. However, this doesn't mean that ocular form of GME was present. Since the eyes are tightly connected to the brain. If a lesion is situated in the visual cortex of the brain, the eye will be "healthy" but non-visual. Fundoscopy was performed in 4 out of the 10 cases but only in 3 cases changes were present. However, in the only case where changes were not observed at the time of admission, the eyes were still non-visual, stayed non-visual up and fundoscopic changes appeared years later (Figure 24). However, the MRI performed on this dog revealed multifocal lesions, so the blindness could be the consequence of the optic neuritis but also a symptom of a potential lesion in the visual cortex of the brain (Figure 22). Out of the 4 patients on which fundoscopy was performed, 3 patients with fundoscopic changes were observed and were therefore considered as ocular form of GME. Consequently, ocular form of GME was represented in 30% of the sampled population. Considering that fundoscopy was not performed in 6 of the sampled population, ocular form of GME can therefore be underestimated in this study.

The trigeminal nerve, responsible for the sensory component of the palpebral reflex, and the facial nerve, responsible for its motor component, appear to be largely unaffected, as only two patients demonstrated deficits in the palpebral reflex.

GONCALVES et al. (2024) claimed that "seizures and obtundation are linked to shorter survival times". In this research, 2 patients had seizures, among which one of them was obtunded upon admission. However, both are still alive.

MRI was performed in 7 out of 10 dogs. In all of them multifocal hyperintense lesions were present intra-axially on T2 weighted images. According to GRANGER et al. (2010), this finding is one of the inclusion criteria for antemortem diagnosis of MUO. The next criterion of inclusion is pleocytosis on CSF analysis with > 50% mononuclear cells. Out of the 3 cases on which CSF has been analyzed, all 3 of them had pleocytosis with more than 50% mononuclear cells. The other criterion was the age of the dogs: all the animals were older than 6 months. And finally, the exclusion of parasitic/infectious diseases: out of 6 cases that have been tested to exclude parasitic/infectious diseases, all of them were negative.

In dogs diagnosed with MUO the most common MRI findings are intra-axial multifocal hyperintense lesions on T2 weighted images. The lesions are more commonly situated in the cerebrum, cerebellum, brain stem, cervical spinal cord and optic nerve/chiasma. This finding is in accordance with CHERUBINI et al. (2006) and MAEHARA et al. (2009).

It is worth emphasizing that the Faculty of Veterinary Medicine at the University of Zagreb primarily receives more complex cases referred from primary care clinics across Croatia. This specialized focus may limit the diversity of cases represented in studies conducted there. To ensure a more comprehensive dataset, involving smaller, more traditional veterinary clinics in similar research could be valuable. Such inclusion would broaden the scope of the study and provide insights into cases that might not typically reach referral institutions.

The hypothesis of this study is that ocular manifestations associated with MUO occur at a relatively low incidence within the population of dogs affected by this condition. Based on our findings, ocular form of GME alone is less likely to happen since all the images on the MRI of the patients showed multifocal lesions. However, in 2 of the MRI performed, specific lesions were observed on the optic chiasma/optic nerve among other lesions. And on the 4 fundoscopies realized, 3 have the ocular form of GME.

After treatment, 3 patients lost sight in one eye, 2 dogs became completely blind, and 2 patients died. Therefore, these outcomes highlight the severity of MUO and the potential for significant residual impairments or fatality despite adequate therapeutic intervention, underscoring the need for early diagnosis and optimized therapeutic strategies.

Our study has many limitations. The first and main one being that the small size of the sample did not allow us to draw very significant statistics from our data. Moreover, the general ophthalmological and neurological examinations were performed by different clinicians. Therefore, the approach to examination and the way reports were written by the clinician collecting the data could have influenced the results of this study.

Furthermore, the lack of standardized treatment, and even more the lack of unique salvage protocols could have influenced the individual survival times and likelihood of relapse. The overall lack of histopathological examination in most cases makes a misdiagnosis a possibility. But that is the universal deficiency of all the research conducted in dogs with MUO worldwide. As described earlier, some animals had concurrent diseases: on one hand, it is therefore possible that in some cases the clinical signs could have been caused by a second condition. Or that the therapy of MUO influenced the success of treatment of that concurrent disease. On the other hand, excluding the patients with concurrent diseases would be denying

the fact that in everyday life, veterinary and human doctors must treat patients with more than one disease.

6. CONCLUSION

- MUO affects mostly small sized female dogs about 5 years of age.
- In this study, the overrepresented breed with MUO is Maltese.
- In dogs diagnosed with MUO, the most frequently observed MRI findings include intra-axial multifocal hyperintense lesions visible on T2-weighted images. These lesions are predominantly located in the cerebrum, cerebellum, brainstem, cervical spinal cord, and optic nerve or chiasm.
- Visual impairments are very common in dogs diagnosed with MUO. In this study, the prevalence of ocular meningoencephalitis is not considered low since 30% of patients had ocular form of GME.
- All the patients diagnosed with the ocular form of GME had multifocal lesions thorough their CNS, therefore it is unlikely that these patients had the ocular form of GME alone.
- MUO is a severe condition with poor prognosis if not diagnosed on time. If the patients survive, it is more likely that they will have sequelae for the rest of their life.

7. REFERENCES

1. ADAMO P. F., W. M. ADAMS, H. STEINBERG (2007): Granulomatous meningoencephalomyelitis in dogs. *Compend. Contin. Educ. Vet.* 29, 678-690.
2. BEASLEY M. J. and A. SHORES (2023): Perspectives on pharmacologic strategies in the management of meningoencephalomyelitis of unknown origin in dogs. *Front. Vet. Sci.* 10:1167002.
DOI:10.3389/fvets.2023.1167002.
3. BUDRAS K. D., W. FRICKE (1994): Atlas der Anatomie des Hundes. Lehrbuch für Tierärzte und Studierende. 4th Ed., Schlütersche Verlagsanstalt und Druckerei GmbH & Co., Hannover. 47A.
4. BUI T., J. M. DAS (2023): Neuroanatomy, Cerebral Hemisphere. In: StatPearls. Treasure Island (FL): StatPearls Publishing (2024). NCBI Bookshelf ID: NBK549789. Online link: <https://www.ncbi.nlm.nih.gov/books/NBK549789/>.
5. CHERUBINI G. B., S. R. PLATT, T. J. ANDERSON, C. RUSBRIDGE, V. LORENZO, P. MANTIS, R. CAPPELLO (2006): Characteristics of magnetic resonance images of granulomatous meningoencephalomyelitis in 11 dogs. *Vet. Rec.* 159, 110-115.
DOI:10.1136/vr.159.4.110.
6. COATES J. R., N. D. JEFFERY (2014): Perspectives on Meningoencephalomyelitis of Unknown Origin. *Vet. Clin. N. Am.: Small Anim. Pract.* 44, 1157-1185.
DOI:10.1016/j.cvsm.2014.07.009.
7. CORNELIS I., L. VAN HAM, I. GIELEN, S. DE DECKER, S. F. M. BHATTI (2018): Clinical presentation, diagnostic findings, prognostic factors, treatment and outcome in dogs with meningoencephalitis of unknown origin: A review. *Vet. J.* 244, 37-44,
DOI:10.1016/j.tvjl.2018.12.007.
8. DEWEY C. W., R. DA COSTA, W. B. THOMAS (2016): Performing the neurological examination. In: *Practical Guide to canine and feline neurology*. 3rd Ed., John Wiley & Sons Inc. 9-28.

9. DONE S. H., P. C. GOODY, S. A. EVANS, N. C. STICKLAND (2009): Color Atlas of Veterinary Anatomy, 3, The Dog & Cat, 2nd Ed, Mosby, Elsevier, Edinburgh, London, UK. 80-87.
10. ELIAS A. and C. BROWN (2008): Cerebellomedullary cerebrospinal fluid collection in the dog. *Lab. Anim. (NY)* 37, 457-458.
DOI:10.1038/labani008-457.
11. EVANS H. E., A. DE LAHUNTA (2009): Guide to the dissection of the dog, 7th Ed., Saunders, Elsevier, St Louis, Missouri, USA, 210.
12. GELATT K. N. (2018): Eye structure and function in Dogs. 2024 Merck & Co., Inc., Rahway, NJ, USA and its affiliates (MSD).
13. GONÇALVES R., S. DE DECKER, G. WALMSLEY, T.W. MADDOX (2024): Prognosis in meningoencephalitis of unknown origin in dogs: Risk factors associated with survival, clinical relapse, and long-term disability. *J. Vet. Intern. Med.* 38, 1583-1590.
DOI:10.1111/jvim.17037.
14. GONÇALVES R., T. W. MADDOX, S. PHILLIPPS, A. NAGENDRAN, C. COOPER, R. ORLANDI, R. FENTEM, G. L. WALMSLEY (2023): Development of a reliable clinical assessment tool for meningoencephalitis in dogs: The neurodisability scale. *J. Vet. Intern. Med.* 37, 1111-1118.
DOI:10.1111/jvim.16717
15. GRANGER N., P. M. SMITH, N. D. JEFFERY (2010): Clinical findings and treatment of non-infectious meningoencephalomyelitis in dogs: A systematic review of 457 published cases from 1962 to 2008. *Vet. J.* 184, 290–297.
DOI:10.1016/j.tvjl.2009.03.031.
16. JONES B. S., F. X. LIEBEL, A. FADDA, S. MARTIN, R. LAWN, K. LAZZERINI, T. HARCOURT-BROWN (2024): Corticosteroid monotherapy versus combined cytarabine continuous rate infusion and corticosteroid therapy in dogs with meningoencephalitis of unknown origin: A blinded, randomized, controlled trial. *J Vet Intern Med.* 38, 1618-1625.
DOI:10.1111/jvim.17088.

17. KAMALI A., K. H. HASAN, P. ADAPA, A. RAZMANDI, Z. KESER, J. LINCOLN, L. A. KRAMER (2014): Distinguishing and quantification of the human visual pathways using high-spatial-resolution diffusion tensor tractography. *Magn Reson Imaging*. 32, 796-803.
DOI:10.1016/j.mri.2014.04.002.
18. KELAWALA D. N., D. B. PATIL, P. V. PARIKH, M. J. SHETH, C. G. JOSHI, B. REDDY (2016): Clinical studies on progressive retinal atrophy in 31 dogs. *Iran J. Vet. Res.* 18, 119-123.
DOI:10.22099/ijvr.2017.4096.
19. KIPAR A., W. BAUMGÄRTNER, C. VOGL, K. GAEDKE, M. WELLMAN (1998): Immunohistochemical Characterization of Inflammatory Cells in Brains of Dogs with Granulomatous Meningoencephalitis. *Vet. Pathol.*, 35, 43-52.
DOI: 10.1177/030098589803500104.
20. KÖNIG H. E. and H. G. LIEBICH, (2004): Nervous system (systema nervosum). In: *Veterinary Anatomy of Domestic Mammals, Textbook and Colour Atlas*. Schattauer GmbH, Hölderlinstraße 3, D-70174 Stuttgart, Germany, 465-536.
21. LIEBICH H. G. (2019): Receptors and sense organs (organa sensuum). In: *Veterinary Histology of Domestic Mammals and Birds, Textbook and Colour Atlas*. 5th Ed., (Liebich H. G. Ed.), 5m Publishing Ltd, Benchmark House, 8 Smithy Wood Drive, Sheffield, S35 1QN, UK. 347-379.
22. LONG M. T. (2018): *Meningitis and Encephalitis in Dogs*. Merck & Co., Inc., Rahway, NJ, USA (MSD).
23. LOWRIE M., S. THOMSON, P. SMITH, L. GAROSI (2016): Effect of the constant rate infusion of cytosine arabinoside on mortality in dogs treated with meningoencephalitis of unknown origin. *Vet. J.* 213, 1-5.
DOI:10.1016/j.tvjl.2016.03.026.

24. MAEHARA T., A. SHIMADA, T. MORITA, Y. SAWASHIMA, K. SAWASHIMA (2009): Distribution of the Inflammatory Lesions in the Central Nervous System of Dogs Affected with Disseminated and Ocular Form of Granulomatous Meningoencephalomyelitis. *J. Vet. Med. Sci*, 71, 509-512.
DOI:10.1292/jvms.71.509.
25. MAGGS D. J., P. E. MILLER, R. OFRI, (2008): Basic Diagnostic Techniques. In: *Slatter's fundamentals of veterinary ophthalmology*, 4th Ed., Saunders, Elsevier, St Louis, Missouri, USA, 81-105
26. MAGGS D. J., P. E. MILLER, R. OFRI (2018): *Slatter's fundamentals of veterinary ophthalmology*. 6th Ed. Saunders, Elsevier, St. Louis, Missouri, USA.
27. McCLURE R.C. (1964): The Spinal Cord and Meninges. In: *Anatomy of the dog*. (MILLER M.E., Ed.), 1st Ed., W. B. Saunders Company, Philadelphia, London, 533-543.
28. MEYER H (1964): The Brain. In: *Anatomy of the dog*. (MILLER M.E, Ed), 1st Ed., W. B. Saunders Company, Philadelphia, London, 480-532.
29. NESSLER J. N., W. K. JO, A. D. M. E. OSTERHAUS, M. LUDLOW, A. TIPOLD (2021): Canine Meningoencephalitis of Unknown Origin—The Search for Infectious Agents in the Cerebrospinal Fluid via Deep Sequencing. *Front. Vet. Sci.* 8:645517.
DOI:10.3389/fvets.2021.645517.
30. O'NEILL E. J., D. MERRETT AND B. JONES (2005): Granulomatous meningoencephalomyelitis in dogs: A review. *Ir. Vet. J.*, 58, 86-92.
DOI:10.1186/2046-0481-58-2-86.
31. OLLIVIER, F., C. PLUMMER, K. BARRIE (2008): The eye examination and Diagnostic procedures. In: *Essentials of Veterinary Ophthalmology*, 2nd Ed., Wiley-Blackwell, Ames, Iowa, USA, 3-22.
32. OSHIMA A., D. ITO, F. KATAKURA, J. MIYAMAE, M. OKANO, M. NAKAZAWA, S. KANAZONO, T. MORITOMO, M. KITAGAWA (2023): Dog leukocyte antigen class II alleles and haplotypes associated with meningoencephalomyelitis of unknown origin in Chihuahuas. *J. Vet. Med. Sci.*, 85, 62-70.
DOI:10.1292/jvms.22-0116.

33. PAKOZDY A., M. LESCHNIK, S. KNEISSL, M. GUMPENBERGER, A. GRUBER, A. TICHY, J. G. THALHAMMER (2009): Improved survival time in dogs with suspected GME treated with cyclosporine. *Vet. Rec.* 164, 89-91.
DOI: 10.1136/vr.164.3.89.
34. PETERSEN-JONES S. M., (2007): The Fundus: What's Normal What's Not. Book of Abstract of the 32nd Annual Congress of World Small Animal Veterinary Association, 19-23rd August, Sydney, Australia. Online link: <https://www.vin.com/doc/?id=3860797>.
35. PLATT S. R., and N. J. OLBY (2004): *BSAVA Manual of Canine and Feline Neurology*, 3rd Ed., JSAP, Gloucester, England.
36. SMOLLICH A., G. MICHEL (1992): *Mikroskopische Anatomie der Haustiere*. 2nd Ed., Gustav Fischer Verlag Jena, Stuttgart, 401.
37. TALARICO L. R. and S. J. SCHATZBERG (2010): Idiopathic granulomatous and necrotizing inflammatory disorders of the canine central nervous system: a review and future perspectives. *J. Small Anim. Pract.* 51, 138-149.
DOI:10.1111/j.1748-5827.2009.00823.x.
38. WINDSOR R, S. STEWART, J. SCHMIDT, M. MOSQUEDA, I. PIRAS, S. M. KELLER, B. STEINMETZ, D. L. BORJESSON, M. HUENTELMAN, C. KHANNA (2022): A potential early clinical phenotype of necrotizing meningoencephalitis in genetically at-risk pug dogs. *J. Vet. Intern. Med.* 36, 1382-1389.
DOI:10.1111/jvim.16444.

8. SUMMARY

Ocular manifestation of meningoencephalitis of unknown origin in dogs

Retrospective study

Céline S. Morteza Gholi

Meningoencephalitis of unknown origin (MUO) is a general term describing inflammatory changes of the central nervous system (CNS) for which non-infectious etiology is assumed.

The purpose of this study is to examine the prevalence of ophthalmologic manifestations in dogs diagnosed with MUO that were admitted to the Clinic for Internal Medicine and the Clinic for Surgery, Ophthalmology and Orthopaedics of the Faculty of Veterinary Medicine of Zagreb. Additionally, the study aims to assess both clinical and visual outcomes after the treatment of these patients. The hypothesis was that ocular manifestations associated with MUO occur at a relatively low incidence within the population of dogs affected by this condition.

In this study 10 patients from the faculty of Veterinary Medicine of Zagreb were included. Prevalence of ocular clinical signs were a common feature since all the 10 patients suffered from ophthalmological deficits. However, ocular clinical signs don't necessarily mean ocular form of GME. To distinguish these two: fundoscopy was performed on 4 out of the 10 patients and 3 patients had fundoscopic changes and were therefore considered as ocular form of GME. They represent 30% of the sampled population. Considering that fundoscopy was not performed in 6 of the sampled population, ocular form of GME can therefore be underestimated in this study. However, the 3 patients with ocular form of GME had presence of multifocal lesions thorough their CNS. Consequently, it is unlikely that these patients had the ocular form of GME alone.

After the treatment, 80% of the patients survived to the date of writing this thesis. Among them 30% of the patients ended unilaterally blind, 20% ended up fully blind and 30% gained their vision back.

MUO is a severe condition with a poor prognosis if not diagnosed promptly. Even when patients survive, they are likely to experience lifelong sequelae.

Keywords: MUO, GME, Ocular, visual outcome.

9. SAŽETAK

Oftalmološke manifestacije meningoencefalitisa nepoznatog podrijetla kod pasa

Retrospektivna studija

Celine S. Morteza Gholi

Meningoencefalitis nepoznatog podrijetla (MNP) opći je izraz koji opisuje upalne promjene središnjeg živčanog sustava (SŽS) za koje se pretpostavlja da imaju neinfektivnu etiologiju.

Svrha ovog istraživanja je ispitati prevalenciju oftalmoloških manifestacija kod pasa dijagnosticiranih s MNP, koji su primljeni na Kliniku za unutarnje bolesti i na Kliniku za kirurgiju, oftalmologiju i ortopediju Veterinarskog fakulteta u Zagrebu. Osim toga, cilj je procijeniti kliničke ishode nakon liječenja ovih pacijenata. Hipoteza je da se oftalmološke manifestacije povezane s MNP pojavljuju s relativno niskom učestalošću unutar populacije pasa pogođenih ovim stanjem.

U istraživanje je uključeno 10 pacijenata s Veterinarskog fakulteta u Zagrebu. Oftalmološki klinički znakovi bili su česta značajka jer su svi pacijenti imali oftalmološke deficite. Međutim, oftalmološki klinički znakovi ne znače nužno i očni oblik GME-a. Za razlikovanje ovih stanja provedena je fundoskopija kod 4 od 10 pacijenata, pri čemu su kod 3 pacijenta zabilježene promjene na fundusu, što ih je svrstalo u kategoriju očnog oblika GME-a. Oni čine 30% ispitivane populacije. Budući da fundoskopija nije provedena kod 6 pacijenata, očni oblik GME-a u ovom istraživanju može biti podcijenjen. Međutim, kod 3 pacijenta s očnim oblikom GME-a zabilježena je prisutnost multifokalnih lezija u CNS-u, što ukazuje da je malo vjerojatno da su imali isključivo očni oblik GME-a.

Nakon liječenja, 80% pacijenata preživjelo je do trenutka pisanja ovog rada. Među njima, 30% pacijenata ostalo je slijepo na jedno oko, 20% potpuno slijepo, dok je 30% povratilo vid.

MNP je ozbiljno stanje s lošom prognozom ako se ne dijagnosticira pravovremeno. Čak i kad pacijenti prežive, često imaju trajne posljedice.

Ključne riječi : MNP, GME, oftalmološki, vizualni ishod.

10. CURRICULUM VITAE

My name is Céline S. Morteza Gholi, I was born on the 9th of April 1996 in Paris, France, where I mainly grew up.

From 2007 until 2012, I attended the French School of Tehran in Iran, where I am originally from.

I got my Scientific Baccalaureate at the Louise Michel high school in Champigny-sur-Marne, France. After that, for personal reasons, I had 3 sabbatical years, during which I travelled to many countries and improved my linguistic skills. I now speak fluent French, English, Persian and Spanish.

In 2018, I started studying in the international program of the Faculty of Veterinary Medicine at the University of Zagreb in Croatia. From my second year, after being the major of my promotion in Histology, I started working as a demonstrator in the Histology practicals until my 5th year.

From the summer of my second year, I started working as a veterinary nurse at the private Veterinary Clinic “Les Bestioles” in Ivry sur Seine, France. I continued going every summer until my last year of studying being the summer of 2024. In total I was working there for around 10 non-consecutive months, during which I learned immensely.

I created, with the help of Senior Assist. Butković, a Surgery workshop at my faculty. These workshops helped 5th and 6th year International and Croatian students to practice their surgery skills (such as sterilization, enucleation, sutures, splenectomy, mastectomy, enterotomy, enterectomy...) on cadavers under the supervision of the professors. After my 4th year until my last, I volunteered at the Clinic of Obstetrics and Reproduction. I was going to most of the nightshifts during which I gained a lot of hands-on experience.

During my 6 years stay in Croatia, I studied the Croatian language for 3 years and ended up with a B2 level certification in Croatian.

For my External Practice Training, I decided to go abroad. I chose Alicante in Spain, where I completed a 2-month externship at the private Veterinary Clinic “Alivet”. This externship and my summer job in France helped me to see how a veterinarian works in real life, how to handle a clinic and enriched my knowledge about the different practice techniques each veterinarian has.