

# Mandibulectomy and maxillectomy in dogs and cats

---

**Demoor, Ines Soledad Titaina**

**Master's thesis / Diplomski rad**

**2024**

*Degree Grantor / Ustanova koja je dodijelila akademski / stručni stupanj:* **University of Zagreb, Faculty of Veterinary Medicine / Sveučilište u Zagrebu, Veterinarski fakultet**

*Permanent link / Trajna poveznica:* <https://um.nsk.hr/um:nbn:hr:178:241984>

*Rights / Prava:* [In copyright](#)/[Zaštićeno autorskim pravom.](#)

*Download date / Datum preuzimanja:* **2024-09-12**



*Repository / Repozitorij:*

[Repository of Faculty of Veterinary Medicine -  
Repository of PHD, master's thesis](#)



THE UNIVERSITY OF ZAGREB  
FACULTY OF VETERINARY MEDICINE

INTEGRATED UNDER-GRADUATE AND GRADUATE UNIVERSITY STUDIES IN  
*VETERINARY MEDICINE*

Inès Solédad Titäina Demoor

Mandibulectomy and maxillectomy in dogs and cats

Zagreb, 2024

Inès Solédad Titaina Demoor

Clinic for Surgery, Orthopedics and Ophthalmology

Head of Clinic: Professor Dražen Vnuk, PhD, DVM

Mentor: Associate professor Andrija Musulin, PhD, DVM

Members of the Committee for Defense of the Master's Thesis:

1. Associate professor Andrija Musulin, PhD, DVM
2. Associate professor Mirna Brkljačić, PhD, DVM
3. Associate professor Marko Pećin, PhD, DVM
4. Professor Dražen Vnuk, PhD, DVM (substitute)

The paper contains 60 pages, 17 figures, 3 tables, 14 literature citations.

## ACKNOWLEDGEMENTS

I would like to thank my mentors, Associate Professor Andrija Musulin, PhD, DVM and Mirta Vučković, DVM for the opportunity to work with them, the professional guidance and help in the writing of this thesis. I would also like to thank them for their teaching and kindness throughout the surgery course.

A big thank you to my friends all over the world for your support, love and memorable memories throughout the years.

A special thank you to my family - Maman, Papa, Glwadys, Clara, Mamie, Papy. Thank you for giving me the opportunity to fulfill my dream, for believing in me, for your endless support and unconditional love. I love you.

Thank you to my four legged friends - Chouchou, Oeka, Raven, Ulpu, and Nayla.

## ABBREVIATIONS

OS - Osteosarcoma

POF - Peripheral odontogenic fibroma

SCC - Squamous cell carcinoma

CAA - Canine acanthomatous ameloblastoma

FS - Fibrosarcoma

MM - Malignant melanoma

LN - Lymph node

CT - Computed tomography

URMN - Unilateral rostral mandibulectomy

BRMN - Bilateral rostral mandibulectomy

URMX - Unilateral rostral maxillectomy

BRMX - Bilateral rostral maxillectomy

## TABLE OF CONTENTS

1.	<b>INTRODUCTION</b>	1
2.	<b>REVIEW OF THE RESULTS OF PREVIOUS RESEARCH</b>	2
2.1.	Canine and feline skull anatomy	2
2.2.	Anatomy and physiology of the canine and feline oral cavity	9
2.3.	Canine oral tumors - classification, prevalence, predisposition	15
2.4.	Feline oral tumors - classification, prevalence, predisposition, risk factors	17
2.5.	Diagnosis and staging	18
2.6.	Decision making	20
2.7.	Surgical principles	20
2.8.	Mandibulectomy	22
2.9.	Maxillectomy	26
2.10.	Post-operative care and assessment	27
2.11.	Appearance	28
2.12.	Complications	29
2.13.	Prognosis	32
3.	<b>MATERIALS AND METHODS</b>	35
4.	<b>RESULTS</b>	36
5.	<b>DISCUSSION</b>	47
6.	<b>CONCLUSION</b>	51
7.	<b>REFERENCES</b>	52
8.	<b>SAŽETAK</b>	53
9.	<b>ABSTRACT</b>	54
10.	<b>CURRICULUM VITAE</b>	55

## 1. INTRODUCTION

Over the years, the perception of animals and our relationship with them evolved. Nowadays, pets have become an integral part of our lives and hold a significant place in our society. For this reason, veterinary medicine, keen to respond to owner's concerns and to maintain animal's welfare, never ceased to study their pathologies and to research treatment options capable of treating them.

Among these, there are dental pathologies which have a direct impact on the general health of animals; dogs and cats, as regards to our study topic. As a result, veterinary dentistry evolved drastically, moving from a time where the only interventions were scaling dental plaque to more invasive and complex interventions such as mandibulectomy and maxillectomy. As stated by VERSTRAETE et al. (2020) these heavy procedures are mainly indicated and performed to remove oral tumors which are the 4th most common type of tumor in dogs ROLLINGS (2022).

Indeed, according to CRAY et al. (2020), the percentage of oral tumors in dogs accounts for 6-7% and 3% in cats. These numbers underline the importance of veterinary dentistry and highlight the reason for its constant progress.

Consequently, the goal of this retrospective study is to conduct and analyze statistical data regarding dental pathologies affecting the mandibular and maxillary region in dogs and cats from the Veterinary Faculty of Zagreb between the years 2012-2022, with emphasis on pathologies that may require any type of mandibulectomy and/or maxillectomy, as well as identifying any overrepresentation of a specific pathology together with the location, examining the prevalence across different breeds, gender, and age groups and number of surgeries performed per cause.

## 2. REVIEW OF THE RESULTS OF PREVIOUS RESEARCH

### 2.1. Canine and feline skull anatomy

The skull is an osseous structure made up of two parts: the neurocranium referring to the bones surrounding the brain and the viscerocranium referring to the bones forming the facial skeleton which surround the ocular, respiratory and digestive system. This latter part is composed of the following paired bones: incisive, nasal, maxilla, dorsal and ventral concha, zygomatic, palatine, lacrimal, pterygoid, mandibule and of one unpaired bone known as the vomer (EVANS and De LAHUNTA, 2013).

Precise knowledge of facial anatomy is essential in veterinary dentistry. In fact, GISIO and CARVALHO (2005) stated that the most significant part of the head for veterinary dentistry is the face, and divides it into three regions: orbital, nasal and oral.

Parts of the frontal bones, along with the zygomatic and lacrimal bones form the orbital region while the nasal bones, along with the maxillary, incisive and palatine bones make up the boundary of the nasal airway. The olfactory organs and nearby blood vessels are supported by osseous laminae known as nasal turbinates, located within the nasal cavity. As for the oral region, it consists of a long surface which serves as a support to bear the teeth (GISIO and CARVALHO, 2005).

Although the incisive bone, maxilla and mandibule constitute the main osseous structure of the oral cavity, a number of bones still contribute to its framework.

#### 2.1.1. Incisive bone

Small in size, the paired incisive bone completes the paired maxillae thus forming the rostral part of the upper jaw and subsequently the hard palate. Each half is composed of a body and three processes. The paired alveolar processes bear the six superior incisors lodged in dental alveoli, which are themselves separated by bony prominence known as interalveolar septa. As for the rostromedial wall of each canine alveolus, it is formed by a laterally oriented concavity, also present on the alveolar surface. The nasal process represents the dorso-caudal part of the incisive while the palatine process represents the caudal part extending from the body. Soft palpable structures known as palatine fissure, represent the two openings in the



incisive bones. This structure comprises blood vessels and the incisive duct from which the vomeronasal organ emerges. As to the palatine process, it provides structural support to the septal cartilage (EVANS and De LAHUNTA, 2013; GISIO and CARVALHO, 2005).

#### 2.1.2. Nasal bone

Despite the variations in the shape and length of the dorsal surface of the nasal bone across the different breeds, the anatomical organization and associated structures remain the same. The nasal bone constitutes the roof of the nasal cavity and articulates bilaterally with the maxilla, incisive and frontal bones forming respectively the nasomaxillary, nasoincisive and frontonasal sutures. On the medial plane, the two halves articulate with each other to form externally and internally the internasal and nasoethmoidal suture correspondingly. The nasal cavity is made of two uniform halves divided in the middle by the nasal septum. The majority of each nasal cavity is occupied rostrally by the ventral nasal conchae and caudally by the ethmoturbinates. Attached to the ethmoid crest, the dorsal nasal concha extends into the dorsal portion of the nasal cavity. As for the ventral nasal conchae, it is attached to the conchal crest. Additionally, the conchae located in each nasal cavity separates this latter into four main passages known as meatus and include the following: dorsal, middle, ventral and common (EVANS and De LAHUNTA, 2013; GISIO and CARVALHO, 2005; KÖNIG and LIEBICH, 2014).

#### 2.1.3. Maxilla

Although its size and shape vary depending on the breed, the maxilla remains the largest bone of the face. Each maxilla is composed of a large maxillary body and several parts known as processes and include the following: palatine, zygomatic, frontal and alveolar processes. Similarly to the incisive bone, the alveolar process of each maxilla represents the surface holding the teeth, which in this case are the canines, premolars and molars. The insertion of their roots into the bone result in the formation of smooth prominences known as alveolar juga. The frontal process arches dorsally from the nasal bone to the orbit overlapping the frontal bone with a squamous suture. As for the zygomatic process, it is mostly invisible due to the presence of the zygomatic bone located laterally, and mitered into the maxilla both above and below the main part of the zygomatic process. The palatine process of the maxilla forms, with its fellow, the majority of the hard palate, thus separating the respiratory and

digestive pathways. Contributing to the formation of a portion of the roof of the oral cavity, the ventral surface of the palatine process is grooved on both sides by the palatine sulcus. Each one begins rostrally from the major palatine foramen, which comprises the vessels and nerve of the same name. In some animals, these sulcus may attain the palatine fissures. Along the maxillary body, runs an infraorbital canal which begins at the maxillary foramen and ends at the infraorbital foramen, allowing the passage of the infraorbital artery and nerve emerging from the pterygopalatine fossa. Coming from the lacrimal fossa and ending at the nasal cavity, the lacrimal canal, responsible for the drainage of the lacrimal fluid is also present in the maxilla (EVANS and De LAHUNTA, 2013; GISIO and CARVALHO, 2005).

#### 2.1.4. Palatine bone

Toothless, the palatine bone is situated caudomedial to the maxilla, and comprises horizontal and perpendicular laminae. The caudal third of the hard palate is formed by the bilateral horizontal laminae. As for the perpendicular laminae, it forms on the medial side, the lateral wall of the nasopharyngeal meatus, and on the lateral side, the medial wall of the pterygopalatine fossa. This latter represents the commencement of the palatine canal which travels into the palatine bone and ends at the major palatine foramen, allowing the passage of the major palatine vessels and nerve. Caudal to the major palatine foramen, a variable number of small openings known as minor palatine foramen exists allowing as well the passage for the major palatine vessels and nerve (EVANS and De LAHUNTA, 2013; GISIO and CARVALHO, 2015).

#### 2.1.5. Mandibule

The inferior jaw is composed of the right and left mandibule, which are joined rostrally forming the mandibular symphysis or intermandibular joint. Bilaterally, the mandibule articulates with the temporal bone forming the temporomandibular joints.

Each mandibule consists of a horizontal body and a vertical ramus. The horizontal body is additionally divided into the pars incisive holding the incisors and pars molaris holding the molars. As for the vertical ramus, it contains the following three prominent processes; coronoid process, condyloid process and angular process. Within the mandibule is the mandibular canal containing the inferior alveolar nerve and vessels supplying the mandibular soft tissues and lower teeth. This canal starts at the mandibular foramen and opens rostrally by dint of the

mental foramina which differ in size and location, yet, serving the same purpose, that is, giving rise to the mental vessels and nerves.

The intermandibular space is defined as the space between the two horizontal rami and include the following elements: tongue, pharynx, cranial portion of larynx and hyoid apparatus. This latter function as a suspensory mechanism for the tongue and larynx and is composed of several bones as well as cartilages (EVANS and De LAHUNTA, 2013; GISIO and CARVALHO, 2005).

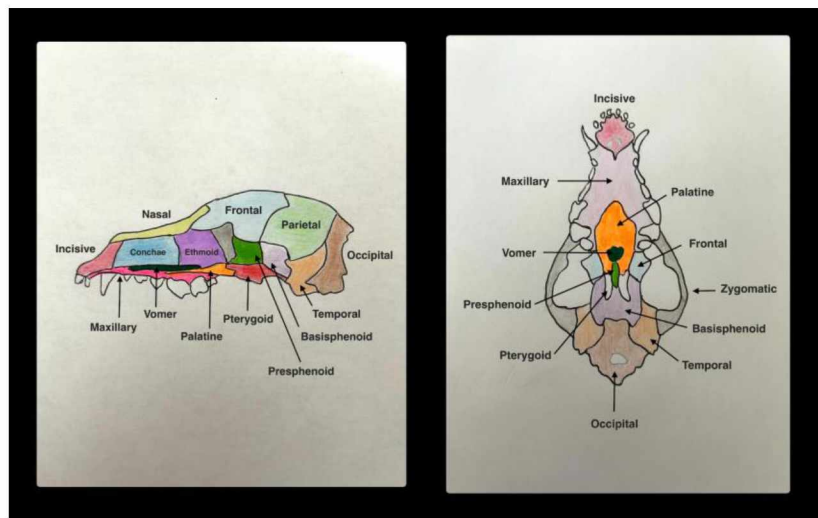


Figure 1. Canine skull anatomy - cross section and ventral view (Drawing by Ines Demoor).

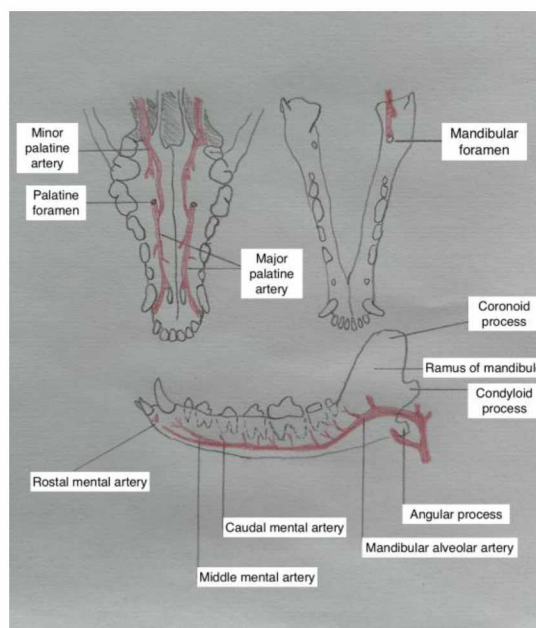


Figure 2. Anatomy of the canine mandible and associated vascular system (Drawing by Ines Demoor).

### 2.1.6. Muscles

EVANS and De LAHUNTA (2013) organize the muscles of the head into nine categories. These include, among others, the facial, masticatory, tongue, pharyngeal, soft palate and hyoid musculature. The first four are innervated respectively by the facial nerves, mandibular nerves, hypoglossal nerves, glossopharyngeal and vagus nerves. The soft palate musculature is innervated by the trigeminal, glossopharyngeal and vagal nerves. As for the hyoid musculature, it is innervated by the trigeminal, hypoglossal and cranial cervical nerves.

As stated in KÖNIG and LIEBICH (2014), the muscles of the lips and cheeks, among others, belong to the superficial layer of the facial musculature. As they are in charge of facial expression, among others, they are also referred as the mimic musculature. These include the orbicular muscle (closes the mouth), incisive muscle (raises the upper lip and pulls lower lip down), nasolabial levator muscle (raises the upper lip and increase the diameter of external nares), levator muscle of the upper lip (raises and draws back upper lip), canine muscle (increase diameter of external nares and draws back upper lip), levator muscle of the chin (movement of the chin), zygomatic (draws back the angle of the mouth) and buccinator muscle (narrow cheek pouch).

Responsible for the movements of the jaw, which are indispensable for mastication, the mandibular muscles consist of the mastication muscles and mandibular space superficial muscles. The mastication muscles include the masseter muscles (raises and draws mandibule sideways), lateral pterygoid muscle (raises, pushes and draws mandible forward), medial pterygoid muscle (raises mandibule) and temporal muscle (raises mandibule). As for the muscle of the mandibular space, they include the digastric muscle which draws the mandibule downwards and the mylohyoid muscle which lifts and supports the tongue (KÖNIG and LIEBICH, 2014).

### 2.1.7. Nerves

The trigeminal nerve or fifth cranial nerve, represents the most important cranial nerve of the face. It is divided into three main branches: ophthalmic, maxillary and mandibular nerves.

The ophthalmic nerve is responsible for the sensory perception of the eyelids, eyeball, nasal mucosa and skin of the nose. Within the periorbita, it splits into the frontal, lacrimal and nasociliary nerves.

The maxillary nerve is in charge of the sensory perception of the upper lip, cheek, nose, upper teeth, gingiva, soft and hard palate. It gives rise to the zygomatic, pterygopalatine and infraorbital nerve. In the pterygopalatine fossa, the pterygopalatine nerve give rise to the minor palatine nerve reaching the soft palate and the major palatine nerve which gives rise to the accessory palatine nerve supplying the caudal portion of the hard palate. As for the major palatine, it gives off a branch to the caudal nasal nerve before entering the palatine canal through the caudal palatine foramen and supplies the majority of the hard palate mucosa.

The pterygopalatine nerve continues by the mean of the caudal nasal nerve which leaves the fossa through the sphenopalatine foramen to enter the nasal cavity allowing sensory innervation to a part of the nasal mucosa. As for the infraorbital nerve, it represents a direct prolongation of the maxillary nerve but takes his name once inside the infraorbital canal by the mean of the maxillary foramen. Within the canal, it gives off alveolar branches supplying the superior teeth and once it exits the canal, it gives off multiple fasciculi.

The mandibular nerve provides motor function to the mandibular muscles and muscles changing the mouth opening and include, among others, the masticator nerve, the lateral and medial pterygoid nerve, tensor veli palatini nerve, buccal nerve, inferior alveolar nerve, mental nerves, mylohyoid nerve, lingual and sublingual nerve. It also has sensory function to the cheek, inferior lip, tongue and to the teeth of the mandibule.

The facial nerve also known as the seventh cranial nerve is another important nerve. It provides motor innervation for the superficial muscles of the head and face among others. It also includes visceral afferent neurons innervating the taste buds of the palate and first two thirds of the tongue. It also acts on the dorsal buccal, mandibular and sublingual salivary glands as well as the nasal, buccal and lingual glands (EVANS and De LAHUNTA, 2013; GISIO and CARVALHO, 2005).

#### 2.1.8. Vascular system

The external carotid artery gives off different branches to the head, thus representing the vascular system of the head. These branches include the occipital, cranial laryngeal, ascending pharyngeal, facial, caudal auricular, parotid, superficial temporal, lingual, and maxillary arteries. This latter gives off additional branches and are divided into the mandibular, pterygoid and pterygopalatine portion.

The mandibular portion corresponds to the portion of the artery that runs from the site where the superficial temporal artery splits off from the carotid artery to the alar canal. From this portion, the subsequent blood vessels arise: temporomandibular joint branch, inferior alveolar, caudal deep temporal, rostral tympanic, middle meningeal and pterygoid.

The inferior alveolar artery enters the mandibular canal via the mandibular foramen, and exits the bone as the mental artery which splits into three branches (caudal, middle, rostral) supplying the soft tissues of the mandible located rostrally.

The pterygoid portion of the maxillary artery has no branches. As for the pterygopalatine portion, it gives off, among others, the pterygoid (supplies the lateral and medial pterygoid muscles), buccal (larger rami runs to masseter, temporal, buccinator muscles, and ends in the soft palate region and pterygomandibular fold), minor palatine (supplies palatine glands, musculature and mucosa), infraorbital and descending palatine arteries. This latter gives off the major palatine (supplies the mucosa of the hard palate and periosteum) and sphenopalatine arteries (supplying the mucoperiosteum of the nose) (EVANS and De LAHUNTA, 2013; GISIO and CARVALHO, 2005).

## 2.2. Anatomy and physiology of the canine and feline oral cavity

The oral cavity represents the first part of the digestive system and is referred to the space and associated structures delimited rostrally and laterally by the lips and cheeks, ventrally by the tongue and underlying mucosa, dorsally by the hard palate and soft palate extending caudally to join the oropharynx (HUDSON and HAMILTON, 2010; TOBIAS and JOHNSTON 2012).

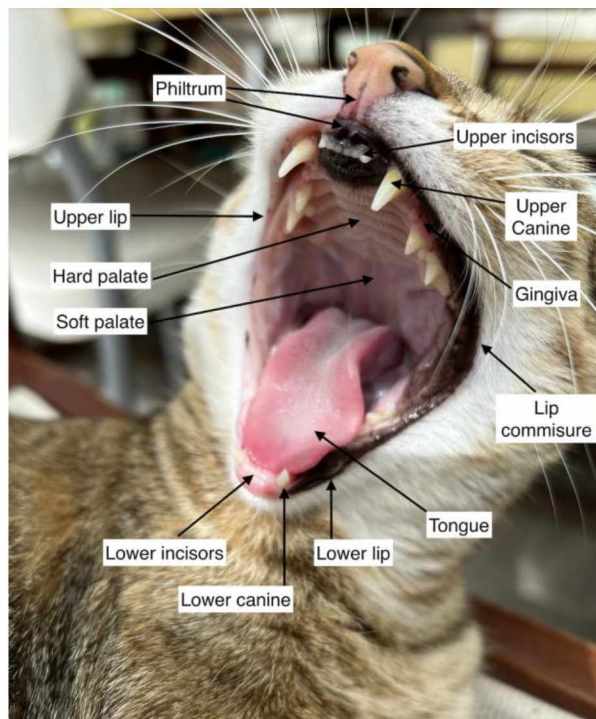


Figure 3. Picture of the feline oral cavity (Picture by Ines Demoor).

As stated in KÖNIG and LIEBICH (2014), the oral cavity consists of two parts : the oral vestibule and the proper oral cavity. This latter is referred to as the space within the maxillary and mandibular dental arcades. The oral vestibule is additionally divided into the labial vestibule, defined as the space between the lips and the teeth and into the buccal vestibule, defined as the space between the teeth and the cheeks.

As explained by TOBIAS and JOHNSTON (2012), the oral cavity encompasses a range of specialized tissues and organs responsible for the prehension, gustation, mastication, digestion and deglutition of the food and water as well as for communication, socialization and protection.

### 2.2.1. Lips and cheeks

Forming the rostral and the majority of the lateral external boundaries of the oral vestibule, the superior and inferior lip frame the mouth opening and unite with each other at the oral commissure (EVANS and DE LAHUNTA, 2013). Present in carnivores and small ruminants, the philtrum, a vertical groove, divides the upper lip. As for the form of the lips, subtle differences exist among the different species responding adequately to each species diet and feeding habits (KÖNIG and LIEBICH, 2014). As described by KÖNIG and LIEBICH (2014), the lips of cats are small and less mobile as the prehension of food is mostly performed by the teeth and tongue. In the dogs, they largely extend caudally allowing behavioral display such as aggression but are unable to perform food prehension. In fact, as explained by TOBIA and JOHNSTON (2012), the lips together with the cheeks are not typically involved in food prehension or water intake. As regards to the cheeks, they represent the caudal portion of the lateral walls of the vestibular cavity and are formed essentially of the buccinator muscle and comprise the zygomatic salivary gland (EVANS and DE LAHUNTA, 2013; KÖNIG and LIEBICH, 2014). Histologically, the lips and the cheeks are composed of an inner mucosal layer which can be partially or totally pigmented, an intermediate muscular layer with fibroelastic tissue and an outer skin layer. As part of the mimetic musculature, these muscles receive motor innervation from the facial nerve, while the outer skin and inner mucosa receive sensory innervation from the trigeminal nerve. As regard to the vascularisation, it is provided by branches of the infraorbital artery for the upper lip and cheek and by branches of the facial artery for the lower lip and cheek (TOBIAS and JOHNSTON, 2012).

### 2.2.2. Palate

Partly osseous, partly membranous, the palate divides the respiratory and digestive passages within the head. The osseous hard palate is located rostrally while the membranous soft palate lies caudally (EVANS and DE LAHUNTA, 2013). The hard palate is composed of parts of the incisive, maxillary and palatine bones. Various numbers of transverse ridges and depressions are present on the oral side. The incisive papilla, which appears as a small median elevation located just behind the incisor, communicates with the nasal cavity and vomeronasal organ by the means of the incisive ducts also known as the nasopalatine ducts and its branches (EVANS and DE LAHUNTA, 2013; KÖNIG and LIEBICH, 2014). The soft palate extends from the hard palate to the intrapharyngeal opening. Bilaterally, the caudal border of the soft



palate is continued to the dorsolateral wall by the palatopharyngeal arch. This latter serves as a portion of the boundary between the nasal pharynx and laryngopharynx. Ventrally, the soft palate is covered by an oral mucosa while a respiratory mucosa covers the dorsal surface. In between, the layer contains muscles and their aponeurose, as well as salivary glands which are packed closely together (EVANS and DE LAHUNTA, 2013; KÖNIG and LIEBICH, 2014).

### 2.2.3. Sublingual floor

The prefrenular region represents the largest area of the sublingual floor, and is located rostral to the frenulum. This latter allows the attachment of the tongue on the medial plane. Just rostral to the frenulum and on each side lie two elevations known as the sublingual caruncles, carrying the common openings of the mandibular duct and major sublingual salivary duct which drains the mandibular salivary gland and major sublingual salivary glands respectively. As for the opening of the minor sublingual salivary gland, it is carried by the longitudinal fold of the lateral sublingual recesses (KÖNIG and LIEBICH, 2014).

### 2.2.4. Tongue

The tongue occupies the majority of the oral cavity and is known for its remarkable versatility. In fact, due to its predominantly skeletal composition and movable tip, it is responsible for the following functions: lapping liquid, licking, sucking, swallowing, vocalization, grooming, tasting and heat regulation, particularly in dogs (TOBIAS and JOHNSTON, 2012). In addition to these functions, TOBIAS and JOHNSTON, 2012; KÖNIG and LIEBICH 2014, states that the tongue is also responsible for food prehension, however, HUDSON and HAMILTON (2010), contends this claim.

The tongue is made up of three parts: a root that secures it to the oropharynx, a body extending rostrally to the root and connected to the floor of the oral cavity by a mucosal fold known as the frenulum, and an apex, the most rostral part which is not connected to the frenulum (TOBIAS and JOHNSTON, 2012). A longitudinal median groove divides the dorsal surface of the dog into halves (EVANS and DE LAHUNTA, 2013).

The different movements of the tongue are made possible by the presence of extrinsic and intrinsic muscles. Adhering firmly to this underlying muscular layer, a thick lingual

mucosa composed of cornified squamous epithelium covers the dorsal and lateral surfaces of the tongue. Structures known as papillae are also present within the lingual mucosa. According to their functions, they are divided into mechanical papillae, more numerous, and gustatory papillae, containing taste buds. Assisting in functions such as licking, water and food prehension, mechanical papillae also shield deeper structures from harmful objects entering the mouth. They include the filiform papillae which are the smallest but most common ones, the marginal papillae, present in neonate as they assist in suckling and the conical papillae. The latter are widely distributed onto the feline tongue, facilitating grooming (TOBIAS and JOHNSTON, 2012). According to their shape, the gustatory papillae are divided into the fungiform, vallate and foliate papillae. In order to ease their functions, a small number of salivary glands located nearby facilitate the removal of food particles allowing the papillae to become accessible for new food particles (KÖNIG and LIEBICH, 2014).

As for the ventral surface of the tongue, it is covered with a looser and thinner lingual mucosa allowing occasionally, visible appearance of the lingual vein. Located parallel to this latter, and arising from the internal carotid artery, the paired lingual artery represents the principal vascular supply of the tongue. Additionally, present along the medial ventral surface of the tongue, the lyssa, a tube-shaped structure, made of muscle, fat and occasionally cartilage and encapsulated by a dense layer of connective tissue acts hypothetically as a stretch receptor (TOBIAS and JOHNSTON, 2012).

#### 2.2.5. Salivary glands

Salivary glands are glandular structures with an exocrine secretion, thus secreting saliva. By means of their ducts, the saliva is secreted into the oral cavity whose role is to keep the oral mucosa moist, lubricate the food, thus facilitating its passage, and initiating chemical digestion. They are classified into the minor and major salivary glands. Present in the mucosa of the lips, cheeks, tongue, palate and sublingual floor, the minor salivary glands secrete a mucous secretion. The buccal minor salivary glands develop larger aggregates located above and below it. In carnivores, the dorsal aggregate is known as the zygomatic gland. As opposed to the minor salivary gland, the majority of major salivary glands secrete a serous secretion while a few secrete a serous-mucous secretion. In addition, these glands are situated at a distance from the oral cavity and include the following: parotid, mandibular and sublingual salivary glands (KÖNIG and LIEBICH, 2014).

## 2.2.6. Teeth

Dogs and cats are diphyodont animals meaning they develop two successive sets of dentition throughout their lives. The first set is known as the deciduous dentition found in young animals which is followed by the permanent dentition found in adult animals. Dogs and cats are also heterodonts meaning they have teeth which differ in size, shape and functions. Consequently, there are four types of teeth; incisors (mainly used for nibbling), canines (used for puncturing and grasping), premolars and molars. In dogs and cats, the upper fourth premolars and the first lower molars are known as carnassial or sectorial teeth and have a shearing function (KÖNIG and LIEBICH, 2014).

As explained by EVANS and DE LAHUNTA (2013), the teeth are organized as maxillary or superior dental arch and mandibular or inferior dental arch. In dogs, there are 28 deciduous teeth (14 maxillary teeth and 14 mandibular teeth) compared to 42 permanent teeth (20 maxillary teeth and 22 mandibular teeth). In cats, there are 26 deciduous teeth (14 maxillary teeth and 12 mandibular teeth) compared to 30 permanent teeth (16 maxillary teeth and 14 mandibular teeth). In cats, the first premolar as well as the second and third molars of the upper and lower jaw are absent. Additionally, the second premolar in the lower jaw is also absent in cats.

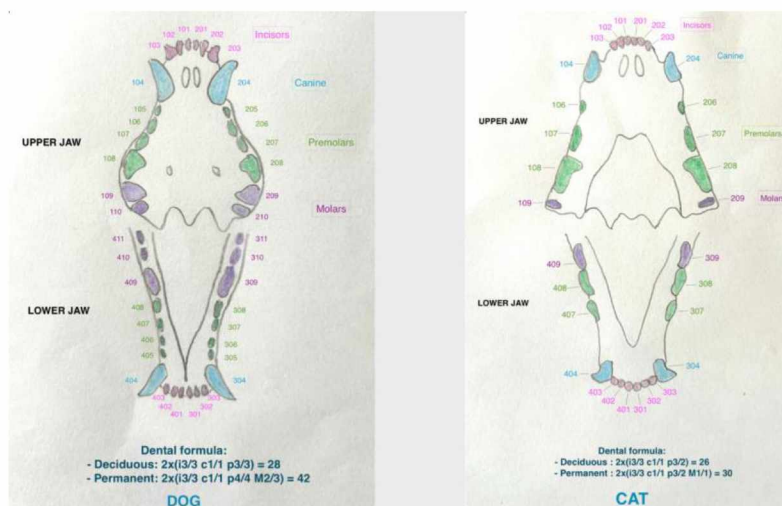


Figure 4. Adult canine and feline dental chart with dental formula (Drawing by Ines Demoor).

Despite the differences between the teeth, all teeth are highly specialized structures and have a similar basic structure. Each tooth is composed of a crown (visible part of the tooth), a neck (small constriction situated at the gum line) and a root (portion embedded in the alveolar bone). As for the chemical composition, each tooth is composed of three mineralised substances: enamel, dentin and cement. The enamel is the pearly-white layer covering the teeth. It represents the hardest substance in the body with no possible regeneration. The dentin makes up the bulk of the tooth and surrounds the pulp cavity containing the pulp which consist of connective tissue holding arteries, veins, lymphatic capillaries and sensory nerves. As opposed to enamel, dentin is apt to regenerate. As for the cement, it covers the root and serves as an anchor point for the periodontal ligament on the root (EVANS and DE LAHUNTA, 2013; KÖNIG and LIEBICH, 2014).

### 2.2.7. Periodontium

The periodontium corresponds to the tissues supporting the tooth which include the alveolar bone, the cement on the root, the periodontal ligament and the gum or gingiva. The alveolar bone, as mentioned earlier, corresponds to the portion formed by parts of the maxilla and mandible which support the dental alveoli. Each tooth is attached to the alveolar bone by the periodontal ligament. The latter consist of a connective tissue composed of oriented fibers “filling” the space” between the root and the alveolar bone, thus attaching each tooth in their socket and suspending the teeth in a sling aiding to support the forces occurring during mastication. As for the gingiva, it corresponds to the pinkish mucous membrane surrounding the teeth (EVANS and DE LAHUNTA, 2013; KÖNIG and LIEBICH, 2014).

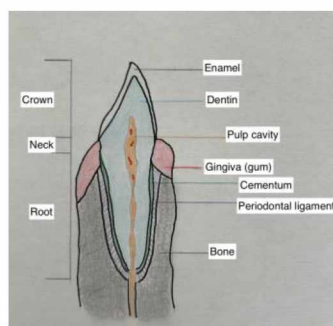


Figure 5. Basic anatomy of a tooth (Drawing by Ines Demoor).

### 2.3. Canine oral tumors - classification, prevalence, predisposition

According to TOBIAS and JOHNSTON (2012), the most common canine oral tumors, in order of decreasing frequency, are malignant melanoma, squamous cell carcinoma, fibrosarcoma, osteosarcoma and canine acanthomatous ameloblastoma. Additionally, by means of their study, CRAY et al. (2020), concluded that the majority of dogs affected by oral tumors belong to nonspecific breeds, followed by labrador retriever, golden retriever, and boxer and that the median age was 10 years old.

The probability of these tumors spreading to surrounding tissues, including bone, is very high but the percentage of invasion differs from one tumor to another. In fact, the metastatic rate to or beyond regional lymph nodes is 81% for MM, 82% for SCC, and 35% for FS (TOBIAS and JOHNSTON, 2012).

Commonly arising from the gingiva, MM usually affects older (10.5-12 years) small breeds such as Cocker spaniels, miniature poodles and less often, larger breeds like golden retrievers, Chow Chows and Gordon setters. As regards to sex predisposition, males are more susceptible with a male-to-female ratio of 3:1-6:1. Beside the gingiva, MM can also affect the tongue, palate, buccal and labial mucosa. MM usually appears firm and darkly pigmented but can be amelanotic. MM grows rapidly, with a relatively rapid development of metastasis to the regional LNs and/or lungs, along with ulceration and hemorrhage. In a study of 43 dogs affected with oral MM, 23 of them were autopsied and revealed that metastases in regional LNs reached a percentage of 74%, compared to 65% for lung metastases (TOBIAS and JOHNSTON, 2012; VERSTRAETE et al. 2020).

Oral SCCs can be classified into tonsillar and non-tonsillar SCC. The latter represents 50-78% of oral SCCs and presents a low metastatic rate, that is up to 10% for regional lymph node metastasis and up to 36% for lung metastasis. On the contrary, tonsillar SCC, which mostly affects smaller breeds, presents a high metastatic rate, with recurrent local tumors after surgery or radiation therapy. Depending on the tumor location within the oral cavity, examples of non-tonsillar SCC include mandibular/maxillary SCC, lingual/sublingual SCC, and papillary SCC. Although non-tonsillar SCC usually affects older large breeds (9 years old), no sex or breed predisposition is reported. These carcinomas mostly appear as a flat, ulcerative region with minimal formation of an external mass. Affected animals tend to drool excessively,

have oral discharge, unpleasant breath odor, difficulty in swallowing and signs of pain when opening the mouth. (GRIER and MAYER, 2007; TOBIAS and JOHNSTON, 2012; VERSTRAETE et al.2020).

Referred to as the third most common canine tumor, fibrosarcoma tends to affect large breeds, especially golden and labrador retrievers. As regards to the age, it usually affects middle to older animals, with an average age of 8 years old. Generally proliferative, FS develops in the gingiva close to the maxillary carnassial tooth and may extend to the hard palate. In fact, in a study, results showed that out of the 76 dogs affected with oral FS, 66 of them had FS in the gingiva and 5 of them on the hard palate. The rest of the involvement sites were the labial mucosa (N=3), soft palate (N=1) and tongue (N=1) (TOBIAS and JOHNSTON, 2012; VERSTRAETE et al. 2020).

As claimed by TOBIAS and JOHNSTON (2012), osteosarcoma and acanthomatous ameloblastoma tend to affect medium and large breeds. As regard to CAA, VERSTRAETE et al. (2020) indicated that Golden retrievers, Akitas, Cocker spaniels and Shetland sheepdogs are the most affected breeds. Although these tumors may develop anywhere in the maxilla and mandibule, CAA usually arises in the rostral portion of these bones; 41% affected the rostral mandibule compared to 6% affecting the caudal maxilla. Additionally, CAA clinically resembles as SCC (TOBIAS and JOHNSTON, 2012; VERSTRAETE et al. 2020). As to mandibular OS, a 12 years period retrospective study was conducted, stated by VERSTRAETE et al. (2020), and concluded that the average age of animals with mandibular OS was 9.5 years old and showed a slight gender predisposition towards females. Additionally, it has been noted that exposure to ionizing radiation can lead to the development of oral OS (VERSTRAETE et al. 2020).

Beside MM, SCC, FS, OS, CAA, peripheral odontogenic fibroma is also common in dogs. In fact, it represents the second most prevalent odontogenic tumor in dogs after CAA. POF is characterized as a slow growing benign neoplasm which tends to affect the rostral maxilla, and tends to affect castrated dogs (VERSTRAETE et al. 2020).

#### 2.4. Feline oral tumors - classification, prevalence, predisposition, risk factors

The oral cavity represents the third most common site of tumor involvement in cats with non-tonsillar SCC being the most common feline oral tumor followed by fibrosarcoma. On the other hand, tonsillar SCC, MM, OS, and POF are uncommon in cats (TOBIAS and JOHNSTON, 2012; VERSTRAETE et al. 2020). Additionally, by means of their study, CRAY et al. (2020), concluded that the majority of cats affected by oral tumors belong to nonspecific breeds and the median age was 12.8 years.

According to PAVLIN et al. (2018), SCC accounts for 60%-70% of all feline oral tumors and affects older cats. The average age was concluded at 12.5 years and no gender or breed predisposition was reported (PAVLIN et al. 2018). SCC may develop in the gingival or sublingual mucosa and are characterized as malignant and highly invasive making successful therapy challenging. As to its metastatic potential and rate, it is often limited to the regional LNs, accounting for 20-30% (TOBIAS and JOHNSTON, 2012; VERSTRAETE et al. 2020). However, evident estimation of the metastatic disease is challenging as SCC has a high mortality rate (PAVLIN et al. 2018). Additionally, one study focused on identifying the risk factors of developing oral SCC, and concluded that there is an increased risk of developing oral SCC with the use of flea collars. The risk was not negligible as it was increased by five. Beside flea collars, the consumption of canned food, particularly canned tuna fish and exposure to household tobacco smoke also increase the risk of developing SCC (TOBIAS and JOHNSTON, 2012; VERSTRAETE et al. 2020).

Based on two surveys, fibrosarcoma represents, respectively, 13% and 22% of feline oral tumors giving it second place among the most common oral tumors. The tumor is characterized as being locally invasive, with a low rate of distant metastases. These characteristics are also applied to oral OS. On average, animals affected with FS are 10.3 years old (TOBIAS and JOHNSTON, 2012; VERSTRAETE et al. 2020).

## 2.5. Diagnosis and staging

As explained by VERSTRAETE et al. (2020), oral neoplasms are often noticed by owners when the tumor has reached a more advanced stage and still may be mistaken with non neoplastic tumors as they may appear as non-healed, ulcerated lesions, rather than notable masses. For those reasons, it is essential to perform a detailed clinical assessment of the patient in order to determine an accurate diagnosis and offer the most adequate and successful treatment.

Along with a thorough patient history, and general physical assessment, inspection and palpation of the tumor should be carefully performed to evaluate its macroscopic appearance, location, size, consistency, and the degree of mobility or fixation. The latter often imply bone infiltration. Similarly, regional lymph nodes are examined. LN involvement is often characterized by two findings: irregular enlargement and loss of mobility (TOBIAS and JOHNSTON, 2012; VERSTRAETE et al. 2020).

Conventional radiography is often represented as the first line screening tool for the detection of tumors and metastasis; however it does not provide sufficient details to assess the characteristics and nature of the tumor despite the presence of three-view radiographs. Ultrasound may be added to assess the LN and/or detect any abdominal metastasis; however more advanced imaging is indicated (TOBIAS and JOHNSTON, 2012).

Computed tomography provides a three dimensional visualization of the location of the tumor and its extend into adjacent structures; for instance the involvement of the intranasal and/or periorbital region when the tumor affects the maxilla and/or the involvement of the TMJ when the mandibule is affected. Consequently, CT provides a detailed tumor assessment, necessary for an eventual biopsy and surgical resection. Additionally, contrast computed tomography can be used to determine LN involvement and in such case, fine-needle aspirate or excisional biopsy is recommended (TOBIAS and JOHNSTON, 2012; VERSTRAETE et al. 2020).

As noticed, imaging represents a primordial tool to evaluate the characteristics of neoplasms, but cannot determine a definitive diagnosis. Consequently, biopsy followed by histopathology should be performed. However, the clinical staging of tumors can be



determined by the history, clinical findings and images obtained prior allowing veterinarians to evaluate and plan different treatment options adapted to each case (TOBIAS and JOHNSTON, 2012; VERSTRAETE et al. 2020).

The most common clinical staging system used in veterinary medicine is the World Health Organization’s tumor-node-metastasis (TNM) system where “T” stands for the extent of the primary tumor, “N” for the regional LN’s involvement and “M” for the presence or absence of distant metastasis.

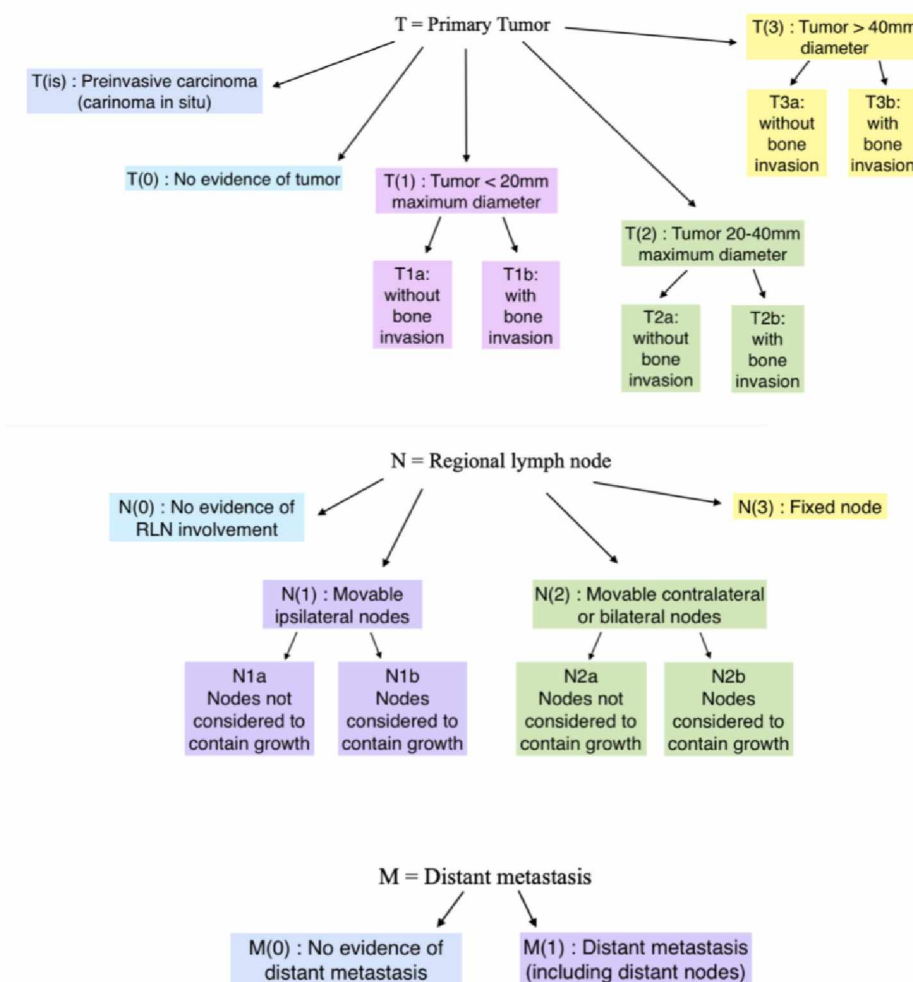


Figure 6. Diagram representing the World Health Organization’s TNM grading system (VERSTRAETE et al. 2020).

## 2.6. Decision making

The clinical and imaging findings, together with the stage and nature of the tumor determine the most appropriate choice of treatment. If surgery is chosen, the type and the extent of the surgical intervention will also be determined by the aforementioned. If surgery is impractical or not elected by the owners, alternative treatments are available. However, surgery remains the most indicated and effective method of treatment. Despite this statement, all treatment options should be discussed with the owners, along with the expectations regarding the aesthetic appearance, complications and prognosis (VERSTRAETE 2005; VERSTRAETE et al. 2020).

## 2.7. Surgical principles and excisions

Surgical oral oncology intends to achieve one of the following goals: to cure, to cytoreduced, to control locally, or to palliate. The purpose of curative surgery is to remove benign and malignant tumors entirely. This is made possible only if the following criteria are applied: absent metastasis, no cancerous cells left behind during the surgery and tumor free surgical margins. Cytoreduction or debulking followed by radiation therapy is elected when large neoplasms cannot be completely excised. Local control is another surgical objective which is elected for animals affected by malignant oral neoplasms like MM, as this tumor is known to have a significant rate for early metastasis. Adjunctive therapy such as radiation treatment may then be applied. If the severity of the disease is too important and cannot be cured by any treatment method, palliative surgery can be performed. The purpose here is to temporarily reduce the pain and improve their quality of life (VERSTRAETE 2005; VERSTRAETE et al. 2020).

Surgical excisions are categorized based on the width of the surgical margins and include intracapsular excision, marginal excision, wide excision and radical resection. Tumors are surrounded by a pseudocapsule, defined as the visible membrane which is made of normal and neoplastic cells and a reactive zone mostly made of inflammatory cells. Although rarely recommended, intracapsular excision which removes the tumor from inside its pseudocapsule may be permitted for well-differentiated odontoma that can be curetted out of the bone. Marginal excision is indicated for well-differentiated benign tumors like POF or for non-neoplastic growths like focal fibrous hyperplasia. However, it is not recommended for

malignant tumors known to be infiltrative. Consequently, for such tumors, wide excision is indicated. The latter consist of removing the tumor en bloc, the pseudocapsule, the reactive zone as well as a wide margin of normal tissue. The width of the margin will depend on the nature of the tumors ; narrower margin for less invasive tumors, wider margins for highly infiltrative tumors like FS. These wide margins are obtained by partial maxillectomy or mandibulectomy which are appropriate for the treatment of small to medium size malignant tumors with or without bone infiltration. For malignant tumors with significant infiltration, radical resection is indicated as it removes the tumor together with its supporting tissue compartment. Performing a total mandibulectomy is an example of such (VERSTRAETE 2005; VERSTRAETE et al. 2020).

## 2.8. Mandibulectomy

VERSTRAETE (2005), defines a mandibulectomy as the en bloc excision of a mandible, or part of one or both mandibles. Mandibulectomy is generally indicated for the removal of malignant and benign oral tumors but may be performed in case of complex mandibular fractures, periodontitis and osteonecrosis. The surgical defects caused by the procedure are closed by means of buccal and alveolar mucosal-submucosal flaps (VERSTRAETE 2005; VERSTRAETE et al. 2020).

The different terms used to describe the type of mandibulectomy are based on the part of the mandible that is removed. Consequently, a *rim excision*, also known as a marginal mandibulectomy, denotes the partial segmental excision leaving the ventral border of the mandible intact. The term *hemimandibulectomy* refers to the complete excision of one of the two mandibles; however, *total* or *unilateral mandibulectomy* is more suitable. In fact, *hemimandibulectomy* should only be used when half of one mandible is excised; nevertheless, the term *partial mandibulectomy* is more appropriate and should be complemented with the part that is removed; rostral, central or caudal. The term one-and-one-half mandibulectomy is preferable over three-quarter mandibulectomy when one entire mandible and half of the other mandible is excised.

### 2.8.1. Rim excision

As previously mentioned, a rim excision is defined as a partial thickness excision of the dorsal two thirds of the mandible, thus, leaving the ventral border intact. As a result, the mandibular canal together with its content and the ventral cortex remain intact conserving the mandible continuity. This approach is appropriate for marginal excision of benign lesions like small benign odontogenic tumors or for wide excision of small and minimally invasive tumors located on the alveolar margins (VERSTRAETE 2005; VERSTRAETE et al. 2020)

### 2.8.2. Unilateral rostral mandibulectomy

According to WITHROW and MACEWEN (2001), URMN is indicated for lesions confined to the rostral half of one mandible not crossing the midline and give SCC and adamantinoma that do not require the removal of the entire affected bone as the most common

example. In dogs, the procedure commonly removes the incisors, the canine as well as the first and second premolars. The osteotomy is performed as such since the root of the canine tooth reaches up to the level of the distal root of second premolars. In cats, the incisor and canine tooth are removed. The removal of the incisor teeth alone, leaving a part of the mandibular symphysis intact, may be performed, however, this is rarely indicated due to the close proximity with the canine tooth and the need for appropriate surgical margins (VERSTRAETE 2005; VERSTRAETE et al. 2020)

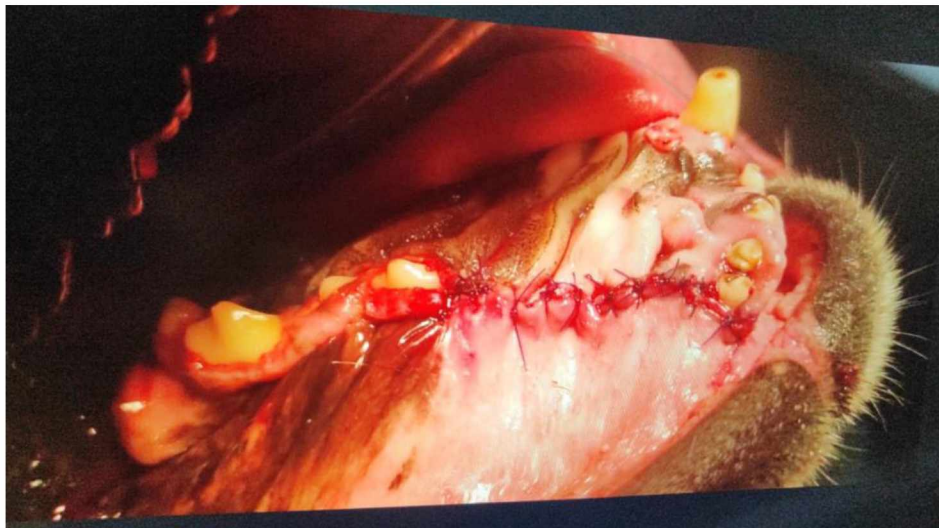

Figure 7. Picture of a dog after rostral mandibulectomy (Courtesy of Mirta Vučković).

### 2.8.3. Bilateral rostral mandibulectomy

BRMN is indicated for bilateral rostral lesions crossing the mandibular symphysis. The osteotomy is performed between the second and third premolar teeth on both mandibule allowing the removal of the canine teeth alveoli entirely. The osteotomy can extend as far as in between the fourth premolar and first molar and still maintain appropriate functionally and cosmesis. However, the sublingual and mandibular salivary ducts are ligated if the latter is performed. The insertion of orthopedic implants to stabilize the remaining mandibles following surgery has been documented, but is rarely performed as it is commonly acknowledged that it is unnecessary (VERSTRAETE 2005; VERSTRAETE et al. 2020).

#### 2.8.4. Segmental mandibulectomy

This type of procedure removes a full-thickness part of the body of the mandible located caudal to the second premolar. Segmental mandibulectomy is appropriate for small tumors that have not infiltrated into the mandibular canal rostrally or caudally nor into the ramus of the mandible. Consequently, following the surgery, the remaining rostral teeth held by the rostral fragment of the mandible are devitalized and an endodontic treatment may be needed VERSTRAETE (2005).

#### 2.8.5. Caudal mandibulectomy

During a caudal mandibulectomy, the ramus of the mandible together with the coronoid, condylar and angular processes are removed. The caudal part of the body of the mandible may or may not be included in the excision. This procedure is sometimes indicated for small neoplasms that have not infiltrated into the mandibular canal VERSTRAETE (2005).

#### 2.8.6. Total unilateral mandibulectomy

According to VERSTRAETE (2005), this type of mandibulectomy is indicated for large and infiltrative neoplasms. Here, the complete mandible on one side is removed, together with the surrounding soft tissue included in the surgical margins. The surgical procedure may be performed in the sternal recumbency through an intraoral approach but positioning the animal in the lateral recumbency in order to incise the commissure is more recommended, as this position allows a better exposure of the ramus of the mandible.

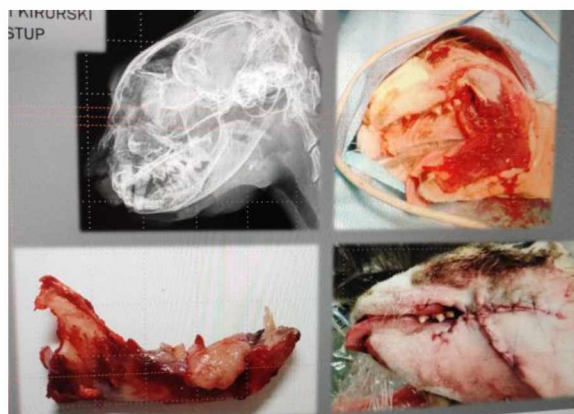


Figure 8. Picture of a cat after total mandibulectomy (Courtesy of Mirta Vučković).

### 2.8.7. Reconstruction

Over the years, reconstruction following mandibulectomy was rarely performed. However, a few methods exist and all show good results. One example of such is the use of an ulnar autograft associated with rigid internal fixation to connect a central mandibulectomy site after the excision of a central benign tumor. Another example include the use of orthopedic pins, screw and bone graft to try and stabilize the remaining lower jaw after a BRMN. Recently, the use of rhBMP-2 to reconstruct the mandible after segmental and bilateral rostral mandibulectomy has been described VERSTRAETE et al. (2020).

## 2.9. Maxillectomy

VERSTRAETE et al. (2020) defines maxillectomy techniques as the removal of various parts of the incisive, nasal, maxilla, palatine, vomer, lacrimal and zygomatic bones bearing the tumors together with adjacent normal soft tissues and teeth. During the surgery, the nasal cavity is entered and the defects caused by the procedure are closed by means of vestibular (i.e., alveolar and buccal) mucosal-submucosal flaps that may be associated with palatal mucoperiosteal flaps. Similarly to mandibulectomy, maxillectomy is generally indicated for the removal of malignant and benign oral tumors but may be performed in case of complex maxillary fractures and osteonecrosis

In the veterinary literature, the term *premaxillectomy* is often used to describe an excision restricted to the incisive bone despite the fact that the term premaxilla is not accepted in the veterinary nomenclature. As a result, the term incisivectomy is more appropriate. The term *hemimaxillectomy* is similarly misleading and incorrect if used to describe the surgical removal of one maxilla. In fact, the appropriate term for the latter procedure is known as a *complete* or *total maxillectomy*. The term *hemimaxillectomy* could be applied to describe the surgical removal of half of one maxillary bone, however, the term *partial maxillectomy* is more appropriate. *Central and caudal maxillectomy* are a type of *partial maxillectomy* in which the midportion or the caudal portion of the maxilla is respectively removed. The latter can be associated with an orbitectomy, which involves the removal of parts of bone forming the orbit (VERSTRAETE 2005; VERSTRAETE et al. 2020).

### 2.9.1. Incisivectomy

Considering that 10mm surgical margins is required for most oral tumors, incisivectomy is infrequently indicated. The surgical procedure involves the incision of soft tissue and the exposure of the bone. The osteotomy is then performed on the distal line angle of the third incisors with extreme caution to avoid any damage to the canine teeth. The procedure results in the exposure of the ventrolateral nasal cartilages but does not enter the nasal cavity VERSTRAETE (2005).



### 2.9.2. Unilateral and bilateral rostral maxillectomy

During a URMX, the incisive bone and the rostral segment of the maxilla are removed. In the dog, the procedure commonly includes the incisors, canine as well as the first and second premolars, while in the cats, the incisors and canine are the teeth involved. This type of maxillectomy is occasionally applied for small tumors located on the buccal aspect of the canine tooth. As opposed to URMX, BRMX is frequently performed. During the procedure, the incisors, canines as well as the first and second premolars are removed in the dog while in the cats, the teeth removed are the incisors, canines and the second premolar VERSTRAETE (2005).

### 2.9.3. Central, caudal, and total maxillectomy

The presence of the infraorbital canal and associated nerves and blood vessels complicates central, caudal and total unilateral maxillectomy, and in particular the two latter. In fact, it is often required to transect the major palatine artery, vein and nerve during a central and caudal maxillectomy. In addition, these procedures result in a temporary communication between the nasal and oral cavity (VERSTRAETE 2005; VERSTRAETE et al. 2020).

## 2.10. Post-operative care and assessment

After the operation, the majority of animals remain under observation for 1 to 3 days. The extent of the surgical procedure correlates with the pain intensity and consequently pain management. Most pain is readily perceived in the first 24 to 72 hours post surgery. Tachycardia, hypertension, salivation, pale mucous membranes and vocalization are among the signs suggesting continuous pain. The latter, however, can also be caused by fear and anxiety. As a result, pain management is achieved by administering opioids. Non steroidal anti-inflammatory drugs are indicated later on for the management of so-called residual discomfort VERSTRAETE et al. (2020).

Multi-electrolyte intravenous fluids are continuously administered until oral intake is normal, that is, 24 hours post-surgery since oral water is offered at that time which is then followed by soft food usually given by hand at the beginning. For debilitated animals and

animals reluctant to eat for more than 3 days, an enteral feeding tube is considered. However, this is rarely performed VERSTRAETE et al. (2020).

To avoid any complications, and thus promote healing, a soft diet is continued at home for 2 to 3 weeks and the removal of chew toys including sticks is highly recommended. A follow-up visit is scheduled 2 weeks following the operation in order to examine the surgical site and remove any skin sutures. A second control visit is scheduled one month after the operation. Then, for one year, at an interval of three months, a complete physical examination, as well as an examination of the surgical site, is carried out in order to monitor the patient's general condition and detect any recurrence VERSTRAETE et al. (2020).

#### 2.11. Appearance

The aesthetic appearance varies as it depends on the extent of the surgery but the results are generally considered to be good and acceptable by most owners. Swelling of the surgical site decreases progressively and is usually resolved within a week. Following a maxillectomy, subcutaneous emphysema and sero-hemorrhagic nasal discharge may be seen while swelling and edema of the sublingual tissues may be present following a mandibulectomy. Regrowth of hair is important as it conceals many facial asymmetries caused by the surgical procedure (VERSTRAETE 2005; VERSTRAETE et al. 2020).

When the mouth is closed, the deformity from most mandibulectomy is concealed by the upper lips. The results are minimalist after a unilateral rostral mandibulectomy with the mandibular canine tooth still being present. However, when the latter is removed, the tongue hangs out from the affected side when the animal is panting. After a bilateral rostral mandibulectomy, the tongue hangs out when panting and the shortened jaws results in a visible mandibular brachygnathism. Facial concavity with the protrusion of the tongue from the affecting side occurs following caudal and total mandibulectomy (VERSTRAETE 2005; VERSTRAETE et al. 2020).

A slight facial concavity and elevation of the lip margin may appear after a unilateral incisivectomy. Drooping of the nose occurs following a bilateral incisivectomy, together with the possibility of the rostral lip margin to retract caudally. A more evident facial concavity with lip elevation appears after a unilateral rostral maxillectomy with the possibility of an additional

unaesthetic appearance, that is, having the mandibular canines lateral to the upper lips. Mandibular prognathism, together with the drooping of the nose occurs following extensive bilateral rostral maxillectomies. As for central and caudal maxillectomies, the degree of the facial concavity with lip margin elevation depends on the extent of the surgical procedure (VERSTRAETE 2005; VERSTRAETE et al. 2020).

## 2.12. Complications

Surgical complications can arise during or after the surgery. The most common intraoperative complication is hemorrhage, which occurs after the unintentional transection of one of the main arteries. Consequently, careful temporary ligation of the carotid artery before maxillectomy has been reported to help in controlling blood loss, however, this is rarely done. Other methods used to control hemorrhage include digital pressure, ligation, focal use of electrocoagulation and hemostatic agent. Knowing that a standard gauze (10cm x 10cm) holds 12mL of blood when saturated and 15mL when supersaturated, blood loss can therefore be estimated by counting all blood-soaked gauze which are placed in a sponge counter bag. Blood typing and cross-matching is therefore recommended prior to surgery in case blood transfusion is needed. In fact one study showed that 42.7% of dogs received an intraoperative blood transfusion out of the 53.4% dogs which experienced abundant bleeding during a maxillectomy procedure. Hemorrhage may also occur postoperatively, as a result, careful monitoring during the first 24 hours is essential (VERSTRAETE 2005; VERSTRAETE et al. 2020).

Infection, wound dehiscence and dysfunction are among the postoperative complications. Although the incidence of infections is low due to excellent vascularisation enhancing rapid wound healing, it may still occur and is higher in animals suffering from immunosuppressive illnesses, undergoing chemotherapy or in animals in which the surgical site has been exposed to radiation. In order to prevent infections, different measures are applied and include scaling and polishing teeth prior to surgery allowing cleaner surgical fields and less inflamed tissues, the use of intraoperative and postoperative antibiotics, and performing appropriate surgical technique under aseptic conditions (VERSTRAETE 2005; VERSTRAETE et al. 2020).

Wound dehiscence after maxillectomy is a relatively common complication. In fact, the incidence rate stands between 7-33%, in which caudal maxillectomies are overrepresented.

Wound dehiscence can however be prevented by achieving correct surgical technique together with a tension-free closure of the flaps and little use of electrocoagulation. Wound dehiscence following mandibulectomy is less common, but may occur at the rostral end of the mandible, in particular at the alveolar margin, and causes the exposure of the bone.

Dehiscence should be debrided if needed and closed surgically in case healing by second intention is not successful. Additionally, wound dehiscence may occur due to the recurrence or persistence of a tumor (VERSTRAETE 2005; VERSTRAETE et al. 2020).

As regard to functional complication, it is frequent for the tongue to hang out laterally or ventrally depending on the type of mandibulectomy. The former often occurs after a unilateral rostral or total mandibulectomy, while the latter occurs following a bilateral rostral mandibulectomy. As a result, food prehension may be affected and drooling may be notable. Drooling can be reduced by raising the lower lip during reconstruction following a bilateral rostral mandibulectomy, while commissurorrhaphy may help the tongue to remain in the mouth as well as reducing drooling following total unilateral mandibulectomy. A period of assisted feeding may be necessary after a bilateral rostral mandibulectomy in the case the surgery goes beyond the second premolar, allowing time for the tongue to regain normal function. Significant postoperative malocclusion often occurs following a segmental, caudal or total unilateral mandibulectomy. Generally, the non operated mandibule and the rostral of the operated mandibule, if there, move toward the resected side. The presence of both mandibular canine teeth tends to injure the hard palate and causes ulceration. Consequently, the reduction of the crown, extraction of one or both mandibular canine may be indicated. In cats, malocclusion can be extremely severe. Therefore temporary maxillomandibular fixation by means of interdental bonding may help in the prevention of malocclusion (VERSTRAETE 2005; VERSTRAETE et al. 2020).

Despite the significant deformity created by the nose drop following a bilateral rostral maxillectomy, nasal breathing does not appear to be impaired. However, the ability of picking and retrieving objects or toys can be affected. Ulceration can also occur following maxillectomy when few mandibular teeth may occlude with the vestibular flap (VERSTRAETE 2005; VERSTRAETE et al. 2020).

Interference with the natural cleaning process of mastication occurs when premolar and molar teeth are extracted during maxillectomy and mandibulectomy causing plaque and

calculus to build up quickly on the teeth located in the opposite quadrant. Consequently, regular periodontal treatment is recommended (VERSTRAETE 2005; VERSTRAETE et al. 2020).

Compared to dogs, cats that underwent extensive oral surgery are more likely to display significant morbidity. Tongue protrusion, malocclusion, dehiscence, drooling, pain and difficulty in eating and/or grooming are among the signs in which 98% of cats experience during the first 4 weeks post mandibulectomy. Among the 98%, more than three-fourths will continue to display one or more of the mentioned signs for the rest of their lives (VERSTRAETE et al. 2020).

Despite the aforementioned dysfunctions, 85% of dog owners reported to be satisfied after mandibulectomy or maxillectomy. The percentage was similar for cat owners although 76% of the surviving cats experienced persistent adverse effects (VERSTRAETE et al. 2020).

Additionally, one study focused on the quality of life of 45 dogs following partial maxillectomy or mandibulectomy. The result demonstrated that 90% of owners would choose the same treatment again suggesting a good quality of life after the surgery despite the potential dysfunctions. In fact, 95% of the owners witness more good than bad days. Here, 71% of owners noted that their dog prehended food and water normally within 4 weeks post surgery (BULL et al. 2023)

### 2.13. Prognosis

According to VERSTRAETE et al. (2020), the majority of clients are satisfied with the results regarding the surgical procedure, reconstruction as well as post-operative physical appearance. It is important to emphasize that this satisfaction correlates with the dexterity and experience of the surgeon, the level of technical performance of the surgery but also the realistic expectations defined and announced to the owners before the operation. This owner satisfaction which reaches 85% is however lower when patients have larger tumors and require more invasive surgery.

Despite these surgical feats, the cure is unfortunately not always definitive and recurrences for both benign and malignant tumors occur. VERSTRAETE et al. (2020) classifies the percentage of recurrences for the following tumors as follow; FS (46%), Melanoma (25%), OS (25%), SCC (15%) and benign neoplasms (0- 4%).

Several articles and studies have made it possible to more precisely quantify the prognosis, recurrences and post-operative life expectancy for each type of tumor in dogs and cats.

With regard to SCC in dogs, one study showed that 94% of the 21 dogs that underwent surgery were still alive one year after the operation. This result correlated with the result of another study. The latter showed that 84% of 19 dogs that underwent mandibulectomy or maxillectomy were still alive after one year, although 11% had metastases and 5% had a local recurrence. For dogs with non-operable SCC, the alternative treatment is radiotherapy in which the success depends on the age and location of the tumor. In fact, the average life expectancy is 39 months for dogs no older than 6 years compared to 9.8 months for dogs over 6 years. With regard to the location of the tumor, if it is placed rostrally, life expectancy is 28.1 months compared to 10 months when it is caudal. It is clear that recurrence reduces life expectancy; 7.1 months with recurrence compared with 28.8 months without recurrence. In cats, studies show that the results of treatment do not live up to expectations. Surgical treatment fails to stop the progression of SCC, and in the short term results in the death of the animal whose owner has no option but to choose euthanasia. The results alone are enough to prove the limits of the treatment. In 5 cats treated by mandibulectomy, the average life expectancy was 6 months while the life expectancy was 1.5 months in 7 cats treated with removal of the tumor alone. Given

the seriousness of this tumor, only a double therapy (surgery and radiotherapy) can achieve better results: in 7 cats treated this way the average life expectancy was 14 months (VERSTRAETE et al. 2020).

Among the most common tumors in dogs, MM comes in first place, and the chances of survival at one year being only 5% with surgery alone. Paradoxically, a study found that the combination of two therapies (surgery and immunotherapy with *Corynebacterium parvum*) has no significant impact on the survival percentage. However, it demonstrated that the stage of the disease plays a major role in the life expectancy of dogs. At stage 1, for tumors smaller than 2cm, the average life expectancy was 511 days. At stage 2 and 3, for tumors between 2 and 4 cm or more, life expectancy reaches a range between 160-168 days.

In cats, where this type of tumor is rare, few studies make it possible to analyze the prognosis. Out of 13 cats with tumors located on the lips or in the oral cavity, 7 of them underwent surgery and 5 out of the 7 cats had a local recurrence. Additionally, the study shows an average life expectancy of 120 days (VERSTRAETE et al. 2020).

Regarding the prognosis of FS which represents the third most common tumor in dogs, two studies demonstrated that the life expectancy at one year after mandibulectomy or maxillectomy was 50%. Furthermore, one of them highlights that out of 14 dogs, 36% of them were affected by local recurrence and 14% by metastases. On the other hand, a third study notes that the location, stage of the tumor, and type of surgery have an impact on life expectancy. Indeed, the best chances of survival concern dogs whose FS is located in the mandibular or maxillary region compared to those with FS affecting the palate. The same is true for those whose FS is only at stage 1 and for those who have undergone wide excision surgery. In cats, for whom FS represents the second most common tumor, the life expectancy prognosis is 1 to 2 years according to a study based on 5 cats having undergone a mandibulectomy and 1 cat having undergone a mandibulectomy associated with chemotherapy (VERSTRAETE et al. 2020).

As for OS in dogs, two studies led to the conclusion that depending on the type of surgery and the location of the tumor, life expectancy increased or decreased considerably. This was 223 days after complete surgery compared to 87 days after partial surgery and 165 days for tumors located in the mandible compared to 105 days for tumors located in other regions. On the other hand, the study highlighted the fact that cisplatin chemotherapy combined

with surgery had no obvious impact on life expectancy. Another study shows that life expectancy at one year is 59%, and that the average is 17.6 months. On the other hand, it highlights a rate of local recurrence and metastases of 28%.

In cats, there are few documented studies that make it possible to quantify the prognosis of life expectancy (VERSTRAETE et al. 2020).

As for the prognosis for dogs with CAA or POF, it is considered to be excellent if the tumor is completely excised. Indeed, two studies show that life expectancy at one year, following this type of surgery, is 100% and 97% respectively for dogs with CAA. However, one author stated that death can occur in dogs affected with POF which underwent an incomplete excision and/or had a local recurrence. The mortality is usually due to malnutrition as the tumor causes difficulty in the prehension and mastication of food (VERSTRAETE et al. 2020).



### 3. MATERIALS AND METHODS

For the objective of this study, all dogs and cats presented with a problem affecting the mandible and/or maxilla between January 1, 2012 and December 31, 2022 were collected. This was achieved by searching retrospectively into the database of the Department of Radiology, Ultrasound Diagnostics and Physiotherapy at the Faculty of Veterinary Medicine in Zagreb, Croatia, using the following keywords and combination: dog mandible, cat mandible, dog maxilla, cat maxilla, dog osteosarcoma mandible, cat osteosarcoma mandible, dog osteosarcoma maxilla, cat osteosarcoma maxilla, dog mandible tumor, cat mandible tumor, dog maxilla tumor, cat maxilla tumor. In total, 568 and 218 cases for dogs and cats respectively were recorded.

Among the 568 cases of dogs and the 218 cases of cats, in agreement with my mentor, only those who were more likely to undergo a surgical intervention (mandibulectomy or maxillectomy) were retained, that is, 127 for the canine cases and 80 for the feline cases.

A table containing the following information; owner and animal name, breed, age, gender, and diagnosis of the 127 canine cases and 80 feline cases was produced and then sent to my mentor who used the database of the Clinic for Surgery, Orthopedics and Ophthalmology at the Faculty of Veterinary Medicine in Zagreb, Croatia, in order to check whether or not these animals had undergone an operation. Surprisingly, neither dogs nor cats mentioned had undergone any type of mandibulectomy or maxillectomy. Nevertheless, knowing that this type of surgery had indeed taken place in the clinic during that time frame, my mentor searched for additional cases using the same database, excluding the cases listed from the radiology file. Subsequently, 58 additional cases were found, which included 47 dogs and 11 cats.

To carry out the overall study and analysis, the 47 dogs were therefore added to the 127 dogs cases and the 11 cats to the 80 cats in an excel table, and specific criteria were chosen including the race, age, gender, tumor type and whether a surgical intervention was realized or not. This made it possible to establish statistics concerning the cases listed at the university according to the criteria defined above. The results are illustrated by tables and graphs.

#### 4. RESULTS

As presented in Figure 9 out of the 91 cats included in the study, a total of 86 belonged to the non-specific breed category referred to as “domestic cats”, thus, representing the majority of the cases (94,51%). Only three specific breeds were involved; Main Coon, British Shorthair and Chartreux and respectively included 3 cats (3,29%), 1 cat (1,099%) and 1 cat (1,009%). Additionally, as presented in table 1, domestic cat is the overrepresented breed for all the diagnoses beside tumefaction.

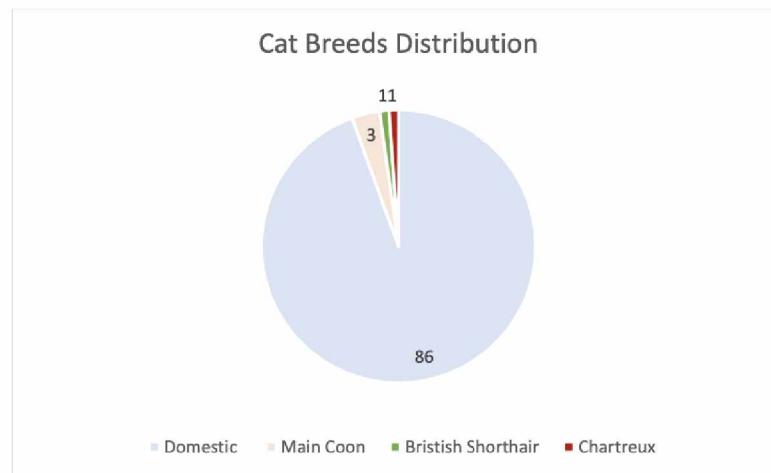


Figure 9. Cat breeds distribution.

Table 1. Case count per cat breed according to the diagnosis.

Diagnosis	Domestic Cat	Main Coon	British Shorthair	Chartreux	Total of cases
Osteosarcoma	27	1	-	-	28
Osteomyelitis	1	-	-	-	1
Rarefying osteitis	15	-	-	-	15
Osteolysis	1	-	-	-	1
Tumefaction	-	1	-	-	1
Ameloblastoma	1	-	-	-	1
Squamous Cell Carcinoma	3	-	1	-	4
Oedema	13	1	-	1	15
Fracture	5	-	-	-	5
Periodontitis	11	-	-	-	11
Other neoplasia	8	-	-	-	8

As presented in Figure 10 the most common reported diagnosis/pathological process affecting the maxilla and/or the mandible in cats was OS (28 cases) followed by oedema and rarefying osteitis (15 cases respectively), periodontitis (11 cases), unspecified neoplasia (8 cases), fracture (5 cases), SCC (4 cases), osteomyelitis (2 cases), osteolysis (1 case), tumefaction (1 case) and ameloblastoma (1 case).

Considering that mandibulectomy and maxillectomy are mainly indicated for the removal of benign and malignant neoplasms, and that none of the cases in which the diagnosis was osteomyelitis, rarefying osteitis, osteolysis, tumefaction, oedema, and periodontitis underwent surgery, only the diagnoses describing a specific and unspecified neoplasia will be emphasized. Therefore, when considering this criteria, the classification is as follows; OS (28) remaining in first place, followed by unspecified neoplasia (8), SCC (4) and ameloblastoma (1).

Along with the different types of diagnoses, Figure 10 additionally demonstrates the location together with the frequency for each diagnosis. The most common location reported for OS was the mandible (20 cases out of 28). For unspecified tumors, no location was overrepresented. In fact, 2 cases affected the mandible and 2 cases affected the maxilla. Similar results were found for SCC (2 cases affected the mandible, 2 cases affected the maxilla). As for ameloblastoma, only 1 case was found and affected the mandible.

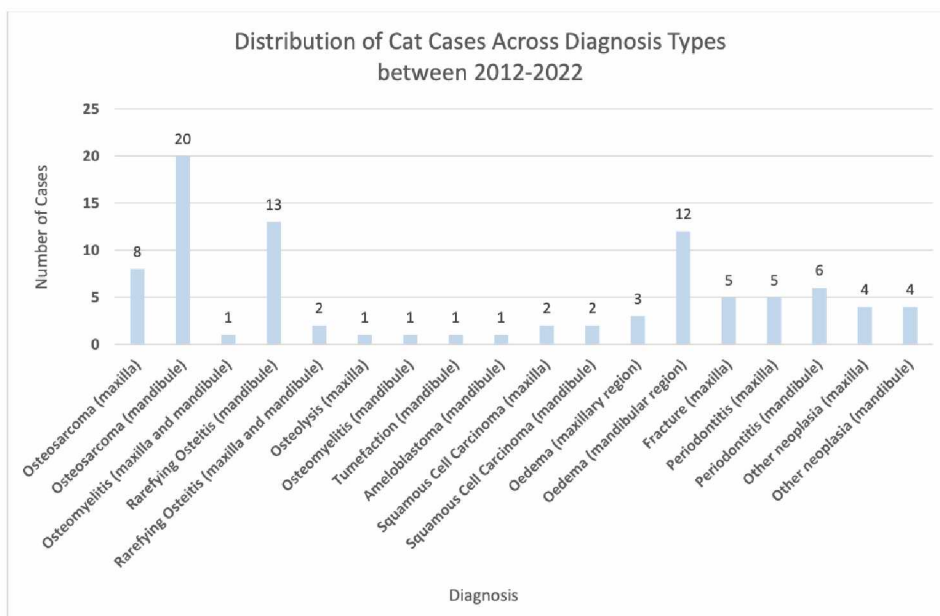


Figure 10. Distribution of Cat Cases Across Diagnosis Types between 2012-2022.

The distribution of the male and the female according to each diagnosis between the same time frame is presented in Figure 11. When considering all the diagnoses types, a total of 51 cats affected were females compared to 40 males. Similarly to the previous analysis, only the results comprising a tumor as a diagnosis will be emphasized. Therefore, when considering this criteria, female cats were still more affected than male cats (27 affected by oral neoplasms vs 14 males). By analyzing each neoplasia individually, females were again overrepresented for OS, as the female male sex ratio was 23:5. For the unspecific tumors, males were overrepresented (7 males compared to 1 female). As for SCC, equal findings were found for the gender, thus, no specific sex were overrepresented (2 males and 2 females). Lastly, the cat affected by ameloblastoma was a female (Figure 11).

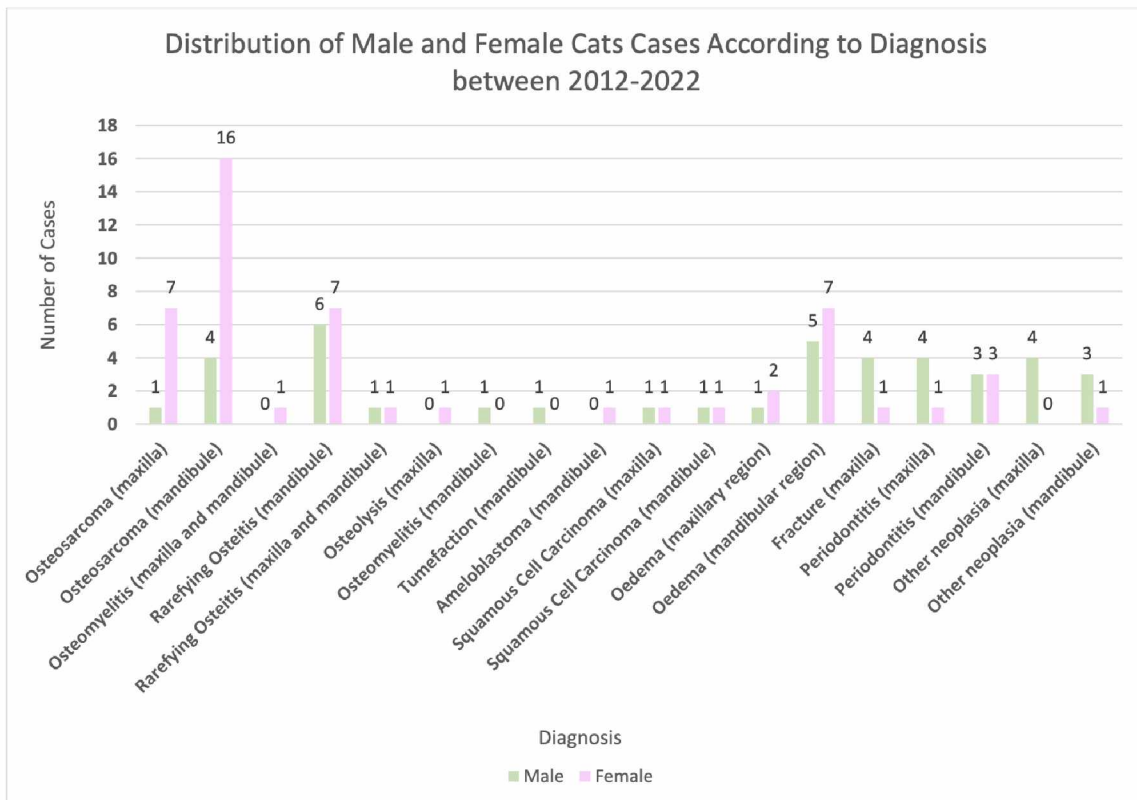


Figure 11. Distribution of Male and Female Cats Cases According to Diagnosis between 2012-2022.

When considering only the cases where the age was given and thus excluding the 28 cases with an unknown age, but including all types of diagnoses, the results showed that the majority of animals affected were above 8 years old (59 out of 63 cats) (Figure 12). When considering only the cases affected by a specific and unspecific type of neoplasia with the given age, the median age was 11 years old. The median age of cats diagnosed with OS was 10 years old. Additionally, the median age of cats diagnosed with unspecified tumors and SCC was 12 years old. The median age was not possible to determine for the diagnosis of ameloblastoma as only one case was recorded. The latter was 10 years old.

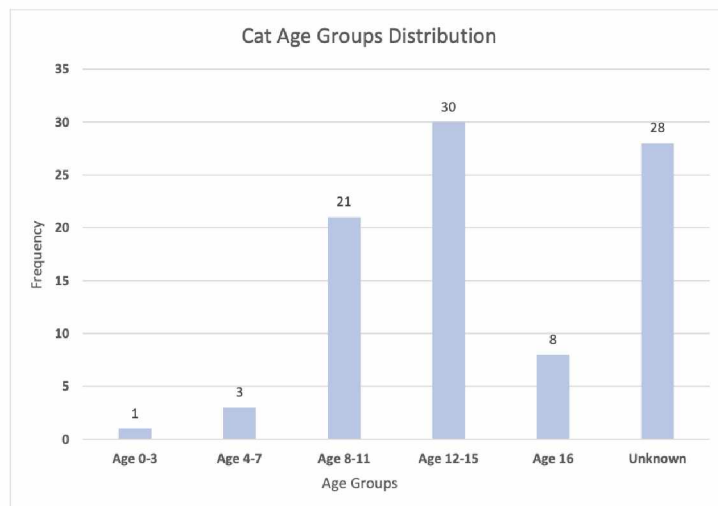


Figure 12. Cat Age Groups Distribution.

Out of the 91 cases, only one cat underwent a surgery. However, when only considering the diagnoses describing a specific and unspecific type of neoplasia, the ratio becomes 1 surgery out of 41. Unilateral total mandibulectomy was performed due to the presence of ameloblastoma (Figure 13).

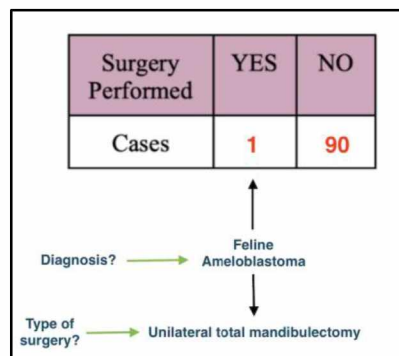


Figure 13. Surgical intervention, type, number.

According to the numbers given by the World Canine Federation and the Cat Fanciers association, dogs have a higher number of established breeds compared to cats, explaining why there are more dog breeds represented in Figure 14 than in Figure 9.

Out of the 174 dogs included in the study, a total of 62 belonged to the mixed breed category, representing the majority of the cases (35,63%). The second most represented breed was Labrador retriever with 12 dogs, followed by German boxer, Poodle and Maltese, comprising 7 animals each. Following that, in third and fourth place respectively, American Stafford with 6 dogs and Bull terrier with 5 dogs. In the fifth position comes the French bulldog, Beagle, Golden Retriever, Shih-Tzu, Pekingese, Bernese mountain dog and German shepherd including each 4 animals. Including 3 animals, the Vizsla and Westie come in the sixth position. Next, in the seventh position, including each 2 animals comes the Bullmastiff, Mastiff, Pug, Scottish terrier, Yorkshire terrier, Boxer, English Cocker Spaniel, Pinscher and Bobtail. In the last position, comes the Tibetan Spaniel, Spitz, Bichon frisé, Irish soft coated terrier, Schnauzer, Border Collie, Lagotto Romagnolo, Rhodesian ridgeback, Dobermann, Samoyed, Havanese dog, Basset, Bull terrier, American Stafford, Saint Bernard, Gordon setter, English setter, and Shiba Inu including only one animal per category (Figure 14).

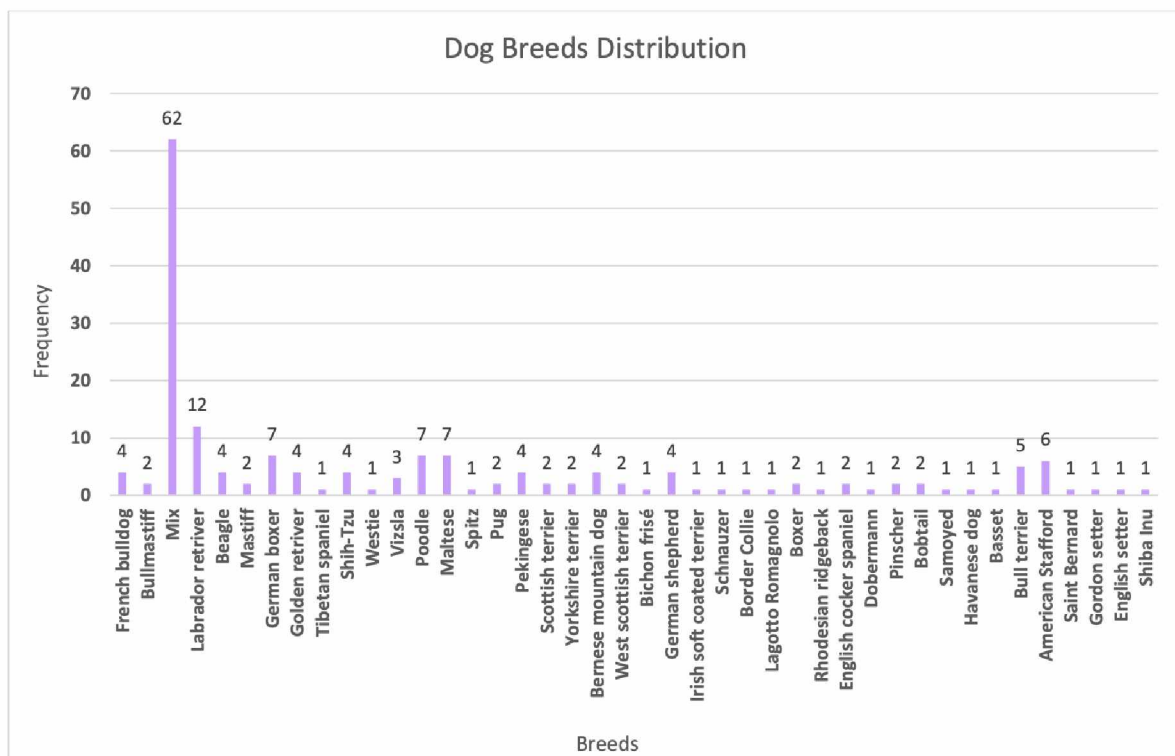


Figure 14. Dog Breeds Distribution.

As presented in Figure 15, and when including all diagnoses, the most common reported cause affecting the maxilla and/or the mandible in dogs was periodontitis (33) followed by OS and oedema (25 and 24 respectively), unspecified neoplasia (23), POF (13), fracture (9), tumefaction (8), rarefying osteitis (7), craniomandibular osteopathy (7), MM (5), SCC (5), amelanotic MM (4), acanthomatous ameloblastoma (4), fibrosarcoma (2), osteolysis (2), osteomyelitis (1) ameloblastoma (1), and anaplastic sarcoma (1).

Similarly to cats, only the diagnoses describing a specific and unspecific type of neoplasia will be emphasized. Therefore, when considering this criteria, the classification is as follows OS (25), unspecified neoplasia (23), POF (13), MM (5), SCC (5), amelanotic MM (4), acanthomatous ameloblastoma (4), fibrosarcoma (2), ameloblastoma (1), and anaplastic sarcoma (1). Figure 7. additionally demonstrates the location together with the frequency for each diagnosis. The most common location reported for OS was the mandible (17 cases out of 23). For two dogs, OS affected the mandible and the maxilla and were therefore excluded in the previous calculation. For unspecific tumors, the maxilla was slightly more affected (11 cases) compared to the mandible (10 cases). Two dogs were excluded from the cases aforementioned as the mandible and maxilla were affected. For POF, the most common location was the maxilla (11 cases out of 13). Similar results were found for MM and amelanotic MM. In fact, the maxilla was the only location reported for all dogs affected by MM. Additionally, 3 dogs had amelanotic MM in the maxilla while only one case of amelanotic MM was reported affecting the mandible. The maxilla was overrepresented for SCC (4 out of 5 dogs). As for acanthomatous ameloblastoma, 3 out of 4 dogs had it on the mandible. As regards fibrosarcoma, both cases reported affected the mandible. The mandible was the reported location for both ameloblastoma and anaplastic sarcoma.

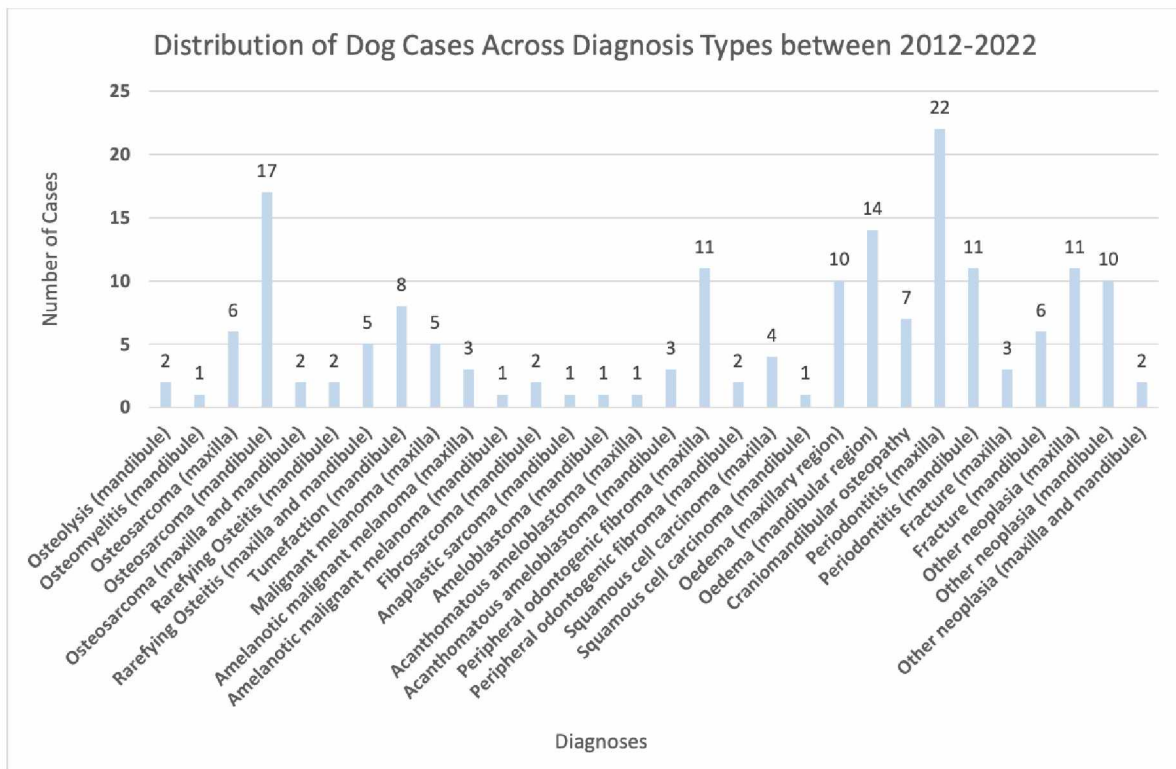


Figure 15. Distribution of Dog Cases Across Diagnosis Types between 2012-2022.

As presented in Figure 16, a total of 120 dogs affected were males while 54 dogs were females. This was calculated by considering all the diagnoses types. Males dogs were still more affected compared to females when comparing the number for the diagnosis only describing a specific and unspecific type of neoplasm. By analyzing each neoplasia individually, females are slightly more affected by OS than males (14 females vs 11 males). The opposite situation occurs for the unspecified tumors where males are slightly more affected (14 males vs 9 females). For POF, 8 males and 5 females were reported indicating again a slight overrepresentation towards males. Only male animals were affected when referring to MM, amelanotic MM, ameloblastoma, and anaplastic sarcoma. There is an equal number of males and females affected by acanthomatous ameloblastoma (2 males and 2 females) and fibrosarcoma (1 male and 1 female). The male and female ratio is however not balanced for SCC (4 males vs 1 female).



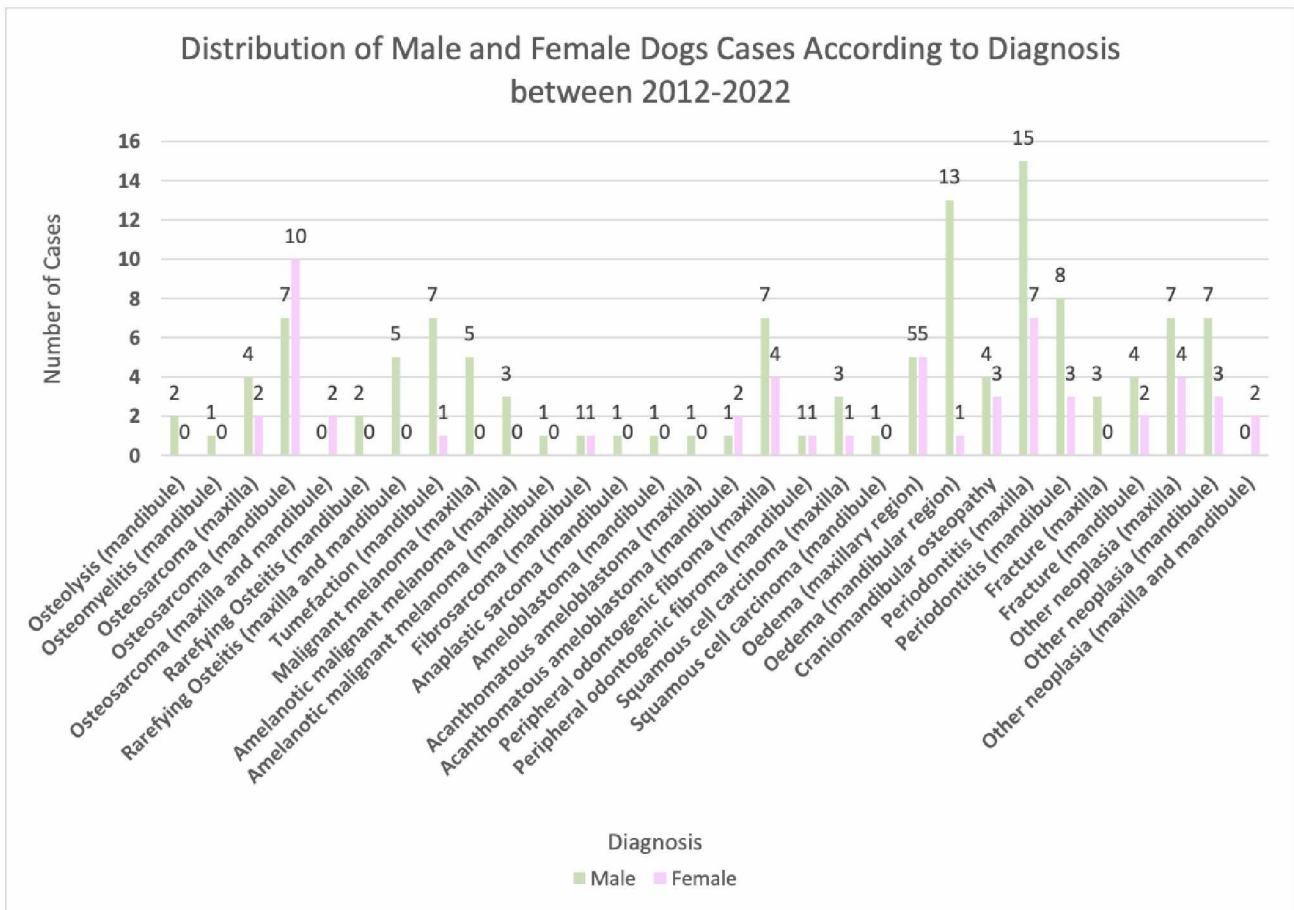


Figure 16. Distribution of Male and Female Dogs Cases According to Diagnosis between 2012-2022.

The breed count per diagnosis is presented in table 2 allowing a better overview of potential breed predisposition per diagnosis based on the data obtained from the Veterinary Faculty of Zagreb, Croatia.

Table 2. Dog breed count per diagnosis

Diagnosis	Breeds affected and number
<b>Periodontitis (33)</b>	23 mix - 2 pekingese - 2 poodle - 1 german boxer - 1 american stafford - 1 english setter - 1 labrador retriever - 1 maltese - 1 pinscher
<b>Osteosarcoma (25)</b>	6 mix - 3 poodle - 3 vizsla - 2 labrador retriever - 2 maltese - 1 bullmastiff - 1 beagle - 1 mastiff - 1 german boxer - 1 shih-tzu - 1 westie - 1 spitz - 1 pug - 1 french bulldog
<b>Malignant melanoma (5)</b>	3 labrador retriever, 1 beagle, 1 rhodesian ridgeback,
<b>Amelanotic malignant melanoma (4)</b>	1 mix - 1 pinscher - 1 english cocker spaniel - 1 shih-tzu
<b>Fibrosarcoma (2)</b>	1 labrador retriever, 1 lagotto romagnolo
<b>Anaplastic sarcoma (1)</b>	1 mix
<b>Ameloblastoma (1)</b>	1 labrador retriever
<b>Acanthomatous ameloblastoma (4)</b>	1 mix - 1 german boxer - 1 french bulldog - 1 golden retriever
<b>Peripheral odontogenic fibroma (13)</b>	2 bobtail - 2 german boxer, 2 boxer, 1 bernese mountain dog - 1 doberman - 1 bullmastiff - 1 maltese - 1 bull terrier - 1 border collie - 1 mix
<b>Squamous cell carcinoma (5)</b>	2 mix - 1 basset - 1 samoyed - 1 scottish terrier
<b>Craniomandibular osteopathy (7)</b>	3 bull terrier - 2 german shepherd - 1 westie - 1 american stafford
<b>Oedema (24)</b>	11 mix - 3 labrador retriever - 3 american stafford - 1 pekingese - 1 mastiff - 1 saint bernard - 1 german boxer - 1 english cocker spaniel - 1 gordon setter - 1 bull terrier
<b>Fracture (9)</b>	5 mix - 1 shiba inu - 1 pug - 1 shih-tzu - 1 german boxer
<b>Osteolysis (2)</b>	1 mix - 1 labrador retriever
<b>Osteomyelitis (1)</b>	1 french bulldog
<b>Tumefaction (8)</b>	3 mix - 2 golden retriever - 2 bernese mountain dog - 1 irish soft coated terrier
<b>Rarefying osteitis (7)</b>	3 maltese - 1 yorkshire terrier - 1 westie - 1 poodle - 1 german shepherd
<b>Other neoplasia (23)</b>	7 mix - 2 beagle - 1 golden retriever - 1 pekingese - 1 scottish terrier - 1 bernese mountain dog - 1 bichon frisé - 1 poodle - 1 shih-tzu - 1 schnauzer - 1 french bulldog - 1 german shepherd - 1 havanese dog - 1 american stafford - 1 yorkshire - 1 Tibetan spaniel

The type and number of surgery performed for the different diagnosis is presented in table 3. Only the diagnosis in which surgery was known to be performed was included. Additionally, the count of total animals affected by each diagnosis was compared to the count of animals which underwent a surgery.

Table 3. Type and number of surgery performed per diagnosis.

Diagnosis	Type and number of surgery performed	Total of animals affected vs how many underwent surgery
<b>Peripheral odontogenic fibroma</b>	<ul style="list-style-type: none"> <li>- Rostral maxillectomy : 7 surgeries</li> <li>- Rostral mandibulectomy: 1 surgery</li> <li>- Central maxillectomy : 2 surgeries</li> <li>- Segmental maxillectomy : 2 surgeries</li> <li>- Segmental mandibulectomy : 1 surgery</li> </ul> <p>Total : 13 surgeries</p>	<p>13 dogs affected</p> <p>→ All 13 dogs underwent a surgery</p>
<b>Fibrosarcoma</b>	<ul style="list-style-type: none"> <li>- Total mandibulectomy : 2 surgeries</li> </ul> <p>Total : 2 surgeries</p>	<p>2 dogs affected</p> <p>→ Both dogs underwent a surgery</p>
<b>Malignant melanoma</b>	<ul style="list-style-type: none"> <li>- right maxillectomy (104-209) : 1 surgery</li> </ul> <p>Total : 1 surgery</p>	<p>5 dogs affected</p> <p>→ Only 1 dog underwent surgery</p>
<b>Amelanotic malignant melanoma</b>	<ul style="list-style-type: none"> <li>- Rostral maxillectomy : 1 surgery</li> </ul> <p>Total : 1 surgery</p>	<p>4 dogs affected</p> <p>→ Only 1 dog underwent surgery</p>
<b>Acanthomatous ameloblastoma</b>	<ul style="list-style-type: none"> <li>- Rostral mandibulectomy : 3 surgeries</li> </ul> <p>Total surgeries: 3 surgeries</p>	<p>4 dogs affected</p> <p>→ 3 dogs underwent surgery</p>
<b>Anaplastic sarcoma</b>	<ul style="list-style-type: none"> <li>- Total mandibulectomy : 1 surgery</li> </ul> <p>Total: 1 surgery</p>	<p>1 dog affected</p> <p>→ The dog underwent surgery</p>

When considering only the cases where the age was given and thus excluding the 39 cases with an unknown age, but including all the types of diagnosis, the results show that the majority of animals affected were within the 8 - 15 years old range. 31 animals were within the range 4 to 7 years old while only 3 animals were 3 years old or below (Figure 17).

The median age of dogs diagnosed with OS was 11 years old. The median age of dogs diagnosed with unspecified tumors was 12 years old. As for SCC, MM, amelanotic MM and POF, the median age was respectively 13, 11, 9, 7. The median age for dogs affected by acanthomatous ameloblastoma or fibrosarcoma was 7 years old. The dog affected by ameloblastoma was 13 years and the dog with anaplastic sarcoma was 10 years old.

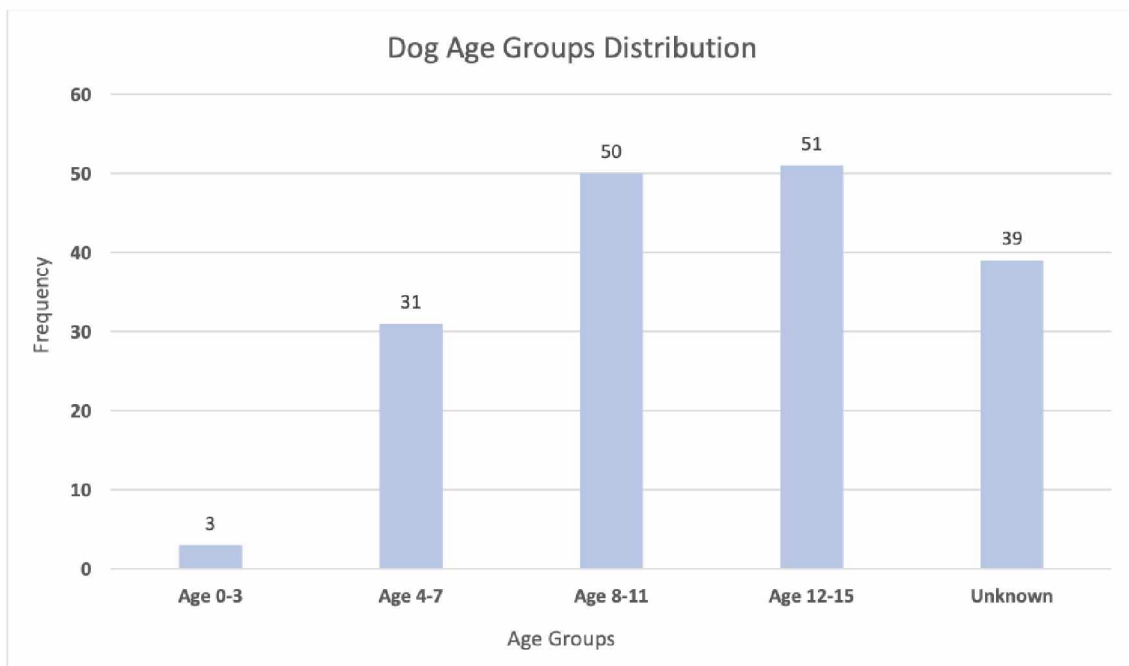


Figure 17. Dog Age Groups Distribution.

## 5. DISCUSSION

In the 10 years interval, the most common dental pathologies/pathological process affecting the maxilla and/or mandible of dogs and cats at the Veterinary Faculty of Zagreb, Croatia were periodontitis, oedema, rarefying osteitis, tumefaction, fracture, osteolysis, osteomyelitis, OS, MM, amelanotic MM, ameloblastoma, FS, SCC, other neoplasia, anaplastic sarcoma, acanthomatous ameloblastoma, POF, craniomandibular osteopathy.

As stated by VERSTRAETE et al. (2020), mandibulectomy and maxillectomy are primarily indicated for the removal of benign and malignant neoplasms. The data obtained from this retrospective study support this statement. Therefore, only the diagnoses describing a specific and unspecific neoplasia, and consequently their data will be discussed and compared with the literature.

Similarly to the report by CLAY et al (2020), the majority of cats affected by oral neoplasia belonged to nonspecific breeds, which is understandable, as there are less established cat breeds compared to dogs breeds according to the World Canine Federation and the Cat Fanciers Association.

As reported in the literature, the most common feline tumor is non tonsillar SCC, followed by FS, while tonsillar SCC, MM, OS and POF are less common. Surprisingly, in this retrospective study, OS was the most common neoplasia (28 out of 41) followed by SCC (4 out of 41) and ameloblastoma (1 out of 41). Nevertheless, 8 cats out of the 41 affected by a neoplasia were identified as “other neoplasia” without specifying the specific type of neoplasm, thus, preventing any comparison to the literature.

As for the age of cats diagnosed with oral tumors (specific and unspecific), the median age in our study was 11 years old which correlates with the literature as it was reported to be 12.8 years old.

Given the fact that OS, MM, POF, and tonsillar SCC are rare in cats according to the literature, only the data obtained from the cases affected by SCC will be discussed and compared to the literature. No sex predisposition was reported, as 2 females and 2 males were affected which complies with the findings reported by PALVIN et al. (2018). Similarly, the

median age of cats affected by SCC in our study was 12 years old and PALVIN et al. (2018) concluded a median age of 12.5 years.

Additionally, as regards to the number of surgeries performed, only one surgery was performed out of 41 cases (specific and unspecific neoplasia). It would be interesting to investigate the reasons behind the owner's decision to not opt for surgery.

The majority of dogs affected by oral neoplasia were mixed breed dogs with 19 out of 87 dogs representing 21,83%, followed by Labrador retrievers accounting for 7 out of 87 dogs representing 8,046%. Similarly findings were reported by CLAY et al. (2020). However, these findings were only coherent for the first two breeds, that is, mixed breed and Labrador retrievers. In fact, our study demonstrated that the German boxer, Beagle and Poodle equally arrive in third position with 4 dogs each, while the Golden retriever ranked third in the CLAY et al. (2020) report.

The most common canine oral tumors reported by the literature, in order of decreasing frequency, are MM, SCC, POF, FS, OS and CAA. Similarly to cats, OS was the most common neoplasia (25 dogs out of 83; 30.12%), followed by POF (13 out of 83; 15,66%), MM (5 out of 83; 6.02%), SCC (5 out of 83; 6.02%), amelanotic MM (4 out of 83; 4.82%), acanthomatous ameloblastoma (4 out of 83; 4.82%), FS (2 out of 83; 2.41%), ameloblastoma (1 out of 83; 1,20% and anaplastic sarcoma (1 out of 83; 1,20%). These results are therefore not fully in line with the literature. Moreover, 33 dogs out of the 83 affected by a neoplasia were identified as “other neoplasia” without specifying the specific type of neoplasm, thus, preventing any comparison to the literature.

If we compare the different criteria selected for this study to those obtained in the literature for OS, we can conclude that the breed category (medium and large), the median age (11 years) and the sex predisposition (slight gender predisposition towards females) obtained in our study complies with the literature. In fact, TOBIAS and JOHNSTON (2012) described a higher tendency towards medium and large breeds, and (VERSTRAETE et al. 2020) concluded a median age of 9.5 years and a sex predisposition towards females.

Knowing that the median age ranges between 10.5-12 years old and that males are more susceptible as stated by TOBIAS and JOHNSTON, 2012; VERSTRAETE et al. 2020), we can

conclude that our data regarding MM complies with the literature given the fact that the median age in our study was 11 years and that only males were affected. However, it is interesting to see that our study showed different results from the aforementioned literature, as it showed that large breeds were affected.

As for SCC, the literature indicates a tendency towards older (9 years) large breeds, with no sex or breed predisposition. This complies more or less with our data as the median age was 13 years old and that no specific breed was overrepresented. Interestingly, our data showed a gender predisposition towards males (4 males, 1 female). However, only 5 animals were affected by SCC, which is not enough to make a conclusive statement, and consequently, additional studies are needed.

Regarding FS, one Labrador retriever and one Lagotto romagnolo were the affected breed in our study, which aligns with the findings in the literature indicating that larger breeds are more susceptible to FS and in particular Golden and Labrador retriever. The median age was 7 years old which again supported the literature finding (8 years old).

In the case of CAA, our study showed that medium and large breed dogs were the most affected breeds, with the mandibule being the most commonly affected location, supporting the findings in the literature that indicate a tendency towards medium and large breeds, and affecting more commonly the rostral mandibule.

As reported by (VERSTRAETE et al. 2020), POF tends to affect the rostral maxilla and castrated dogs. The former complies with our data, as the maxilla of 11 dogs were affected compared to 2 dogs being affected on the mandibule. Interestingly, one owner had both of her Bobtails affected by POF. One was a male of 6 years old and the second was a female of 7 years. Similarly, one owner had both of her Boxers affected by POF. One was a female of 8 years old and the second was a female of 10 years old. It would be interesting to know if these dogs were from the same breeder suggesting a genetic inheritance.

Additionally, as regards the number of surgeries performed per diagnosis, it is interesting to see that all dogs affected by POF or FS or anaplastic sarcoma underwent surgery. Close results were found for CAA where 3 dogs out of 4 underwent surgery. However, this was not the case for MM (1 dog out of 5 underwent surgery) and amelanotic MM (1 dog out

of 4 underwent surgery). Additionally, none of the dogs affected by OS, or SCC, or other neoplasia and unspecified ameloblastoma underwent a surgery. It would be interesting to investigate the reasons behind the owner's decision to not opt for surgery.



## 6. CONCLUSION

- Oral neoplasms account for 6-7% in dogs and 3% in cats.
- The most common oral tumors reported in cats are non tonsillar SCC and FS and less commonly MM, OS, POF. In this study, cats were affected by either OS, unspecified neoplasia, SCC or ameloblastoma.
- The common oral tumors reported in dogs are MM, non tonsillar SCC, POF, FS, OS, CAA. In this study, dogs were affected by either OS, unspecified neoplasia, POF, MM, SCC, amelanotic MM, CAA, FS, ameloblastoma or anaplastic sarcoma.
- The majority of cats affected by oral neoplasia were mixed breeds.
- The majority of dogs affected by oral neoplasia were mixed breed dogs followed by Labrador retrievers.
- The median age of cats affected by oral tumors was 11 years old.
- The median age of dogs affected by oral tumors was within the range 7-13 years old.
- Female cats were more affected by oral neoplasia than male cats.
- Male dogs were more affected by oral neoplasia than female dogs.
- In cats, the mandibule was more affected by oral neoplasia than the maxilla.
- In dogs, the maxilla was more affected by oral neoplasia than the mandibule.
- Maxillectomy and mandibulectomy are commonly indicated for the removal of malignant and benign oral tumors and remain the most indicated and effective method of treatment for oral neoplasm. In this study, oral neoplasia was the only reason for the surgeries performed. 1 cat and 21 dogs underwent surgery.
- The prognosis differs from each oral tumor and the aesthetic appearance together with complications vary depending on the extent of the surgery.

## 7. REFERENCES

1. BULL, I., M. L. ZIENER, S. H. STORLI, M. L. ARENDT (2023): Quality of Life After Partial Mandibulectomy or Maxillectomy in 45 Dogs With Oral Tumors. *J. Vet. Dent.* 40(4), 329-337. doi:10.1177/08987564231164483
2. CRAY, M., L. E. SELMIC, A. RUPLE (2020): Demographics of dogs and cats with oral tumors presenting to teaching hospitals: 1996-2017. *J. Vet. Sci.* doi: 10.4142/jvs.2020.21.e70
3. EVANS, H. E., A. De LAHUNTA (2013): *Miller's Anatomy of the Dog*. 4th edition, Elsevier, Saint Louis
4. GIOSO, M. A., V. G. G. CARVALHO (2005): Oral Anatomy of the Dog and Cat in Veterinary Dentistry Practice. *Vet. Clin. Small Anim.* 35, 763-780. doi: 10.1016/j.cvsm.2004.10.003
5. GRIER, C. K., M. N. MAYER (2007): Radiation therapy of canine non tonsillar squamous cell carcinoma. *Can. Vet. J.* 48(11), 1189-1191.
6. HUDSON, L. C., W. P. HAMILTON (2010): *Atlas of Feline Anatomy for Veterinarians*. 2nd edition, Teton NewMedia, Jackson.
7. KONIG, H. E., H. G. LIEBICH (2014): *Veterinary Anatomy of Domestic Mammals*. 6th edition, Schattauer, Germany.
8. PALVIN, D., T. DOLENŠEK, T. ŠVARA, A. NEMEC (2018): Solid Type Primary Intraosseous Squamous Cell Carcinoma In A Cat. *BMC Veterinary Research* doi: 10.1186/s12917-018-1344-0.
9. ROLLINGS, D. S. (2022): Identifying Malignant Oral Tumors. *dvm360.* 53(4).
10. TOBIAS, K. M., S. A. JOHNSTON (2012): *Veterinary Surgery Small Animal, Vol 1*. Elsevier, Saint Louis.
11. TOBIAS, K. M., S. A. JOHNSTON (2012): *Veterinary Surgery Small Animal, Vol 2*. Elsevier, Saint Louis.
12. VERSTRAETE, F. J. M. (2005): Mandibulectomy and Maxillectomy. *Vet. Clin. Small Anim.* 35, 1009-1039. doi:10.1016/j.cvsm.2005.03.005
13. VERSTRAETE, F. J. M., M. J. LOMMER, B. ARZI (2020): *Oral and Maxillofacial Surgery in Dogs and Cats*. 2<sup>nd</sup> edition, Elsevier, Saint Louis.
14. WITHROW, S. J., E. G. MACEWEN (2001): *Small Animal Clinical Oncology*. 3rd edition. Saunders, Elsevier, Saint Louis.

## 8. SAŽETAK

Inès Solédad Titaina Demoor

### Mandibulektomija i maksilektomija u pasa i mačaka

Oralna neoplazija je četvrti najčešći tumor kod pasa i čini 6-7% i 3% kod mačaka. Mandibulektomija i maksilektomija ostaju najindiciraniji i najučinkovitiji tretman za uklanjanje benignih i malignih tumora usne šupljine. Klinički nalazi, snimanje i biopsija bitni su alati potrebni za dijagnosticiranje i postavljanje stadija oralne neoplazije. Prognoza se razlikuje od jedne do druge oralne neoplazije, a estetski izgled i moguće funkcionalne komplikacije variraju ovisno o opsegu operacije. Općenito, većina klijenata izjavila je da je zadovoljna rezultatima. Ova retrospektivna studija ima za cilj analizirati najčešće uzroke, zajedno s najčešće prijavljenom pasminom, dobi, spolom i lokacijom, koji mogu dovesti do potrebe za mandibulektomijom i/ili maksilektomijom u pasa i mačaka na Veterinarskom fakultetu u Zagrebu, Hrvatska tijekom i razdoblje od 10 godina.

Ključne riječi: mandibulektomija, maksilektomija, oralna neoplazija, psi, mačke.

## 9. ABSTRACT

Inès Solédad Titaina Demoor

### Mandibulectomy and maxillectomy in dogs and cats

Oral neoplasia are the fourth most common tumors seen in dogs accounting for 6-7% and 3% in cats. Mandibulectomy and maxillectomy remain the most indicated and effective treatment for the removal of benign and malignant oral tumors. Clinical findings, imaging and biopsy are essential tools needed to diagnose and stage oral neoplasia. The prognosis differs from one oral neoplasia to another and the aesthetic appearance and possible functional complications vary with the extent of the surgery. Overall, most clients reported to be satisfied with the results. This retrospective study aims to analyze the most common causes, together with the most reported breed, age, gender and location, that may lead to the need for mandibulectomy and/or maxillectomy, in dogs and cats at the Veterinary Faculty of Zagreb, Croatia over a 10 years period.

Key words: mandibulectomy, maxillectomy, oral neoplasia, dogs, cats.

## 10. CURRICULUM VITAE

I was born on May 7th 1997 in Fort-De-France, Martinique (France). From 2001-2005, I attended preschool and primary school at Ecole Française du Nord, Mapou (Republic of Mauritius). Following this from 2005-2009, I attended primary and middle school at Ecole Belge de Kigali, Kigali (Rwanda). From 2009-2013, I attended middle and high school at International Community School of Addis Abeba, Addis Abeba (Ethiopia). From 2013-2015 I attended the last two years of high school at School Europa III d'Ixelles, Brussels (Belgium), where I graduated and obtained my European baccalaureate.

Through traveling, I had the opportunity to explore different countries, visit national parks and immerse myself in different cultures. Moreover, it allowed me to improve my English Skills. Passionate about animals and their well being, in 2015, I applied for a summer student job at the pet shop “Tom & Co”, Auderghem, Belgium where I worked for 3 weeks. I enrolled at the Faculty of Veterinary Medicine in Zagreb, Croatia in September 2017, and began attending classes in October 2017. In 2023, I completed an internship for 6 weeks at the Veterinary Hospital “Centre Hospitalier Vétérinaire AniCura NordVet”, La Madeleine, France.