

# Prevalence of different types of corneal ulcers in dogs-retrospective study

---

Loire, Capucine Fanny Justine

Master's thesis / Diplomski rad

2024

Degree Grantor / Ustanova koja je dodijelila akademski / stručni stupanj: **University of Zagreb, Faculty of Veterinary Medicine / Sveučilište u Zagrebu, Veterinarski fakultet**

Permanent link / Trajna poveznica: <https://um.nsk.hr/um:nbn:hr:178:526858>

Rights / Prava: [In copyright](#) / [Zaštićeno autorskim pravom.](#)

Download date / Datum preuzimanja: **2024-07-16**



Repository / Repozitorij:

[Repository of Faculty of Veterinary Medicine -  
Repository of PHD, master's thesis](#)



THE UNIVERSITY OF ZAGREB  
FACULTY OF VETERINARY MEDICINE

INTEGRATED UNDERGRADUATE AND GRADUATE  
UNIVERSITY STUDIES IN *VETERINARY MEDICINE*

MASTER'S THESIS

Capucine Loire

Prevalence of different corneal ulcers in dogs – Retrospective study

Zagreb, 2024

Capucine Loire

University of Zagreb

Faculty of Veterinary Medicine

Clinic for Surgery, Orthopedics and Ophthalmology

Head: Prof. Dražen Vnuk

Mentor: dr. sc. Valentina Plichta

Members of the Committee for the defense of Master's thesis:

1. prof.dr.sc. Dražen Vnuk
2. doc.dr.sc. Andrija Musulin
3. dr.sc. Valentina Plichta
4. izv. prof. dr. sc. Ozren Smolec (substitution)

The paper contains 59 pages, 10 figures, 8 tables, 108 literature citations.

## ACKNOWLEDGMENTS

I would start by thanking my mentor Valentina Plichta for the enthusiasm she showed from the very first minute of this project and for her help in the redaction of this thesis, especially during the last weeks of writing.

Many thanks to my mother who always had been my number one fan. Thank you for being so supportive through good and bad moments during all these years of studying, I am so grateful for having the best mother ever.

Thanks to my dad for his support since the beginning.

Thanks to my brother Yann for the three hours long conversations every week, for always being on my side and listening to all my boring stories about people you don't know, and you will probably never meet. Thanks for being my best friend and support me in all my choices.

Thanks to my brother Mathieu and his wife Claire for asking weird questions about veterinary medicine and asking me four times a year when you should deworm your animals. Thanks for being so supportive and ready to be my first clients.

Thanks to my stepfather Pascal for always sharing interest in my studies and trusting me with his own little baby doggo Othello.

Thanks to my grandfather for speaking with me every week about the articles and TV shows you see about animals and Croatia. Thanks for being one of my greatest support.

Thanks to all the rest of family for being by my side through all these years.

Thanks to Anja, Cam, Lou, Zoé and Eunhee for being my friends through Vet school and staying my friends even though I am always grumbling. I hope we stay in touch with each other and continue to be friends even if we don't live in the same country.

Thanks to my best friend Audrey. Even if we see each other once a year, you always have been there for me, I am so glad you are in my life.

Thank you to all the clinics and their staffs who welcomed me for externships and taught me so much. A very special thank you to Dr Caroline Delabre, Dr Jean François Guillon, Dr Eric Meyer and Dr Carol Tinel-Meyer for being the first vets to welcome me in your clinics and always being ready to welcome me again. Thank you for all the things you taught me, I hope we stay in contact and our relationships grow to friendships.

I would like to dedicate this manuscript to my friend Tiani who left us too early, it was an honor to live and study by your side.



## FIGURES

Figure 1. Schirmer tear test (source: archives of Clinic for Surgery, Orthopedics and Ophthalmology, Faculty of Veterinary Medicine University of Zagreb) .....	6
Figure 2. Schiottz tonometer (source: archives of Clinic for Surgery, Orthopedics and Ophthalmology, Faculty of Veterinary Medicine University of Zagreb) .....	8
Figure 3. Tono-pen® (source: archives of Clinic for Surgery, Orthopedics and Ophthalmology, Faculty of Veterinary Medicine University of Zagreb) .....	9
Figure 4. TonoVet® (source: archives of Clinic for Surgery, Orthopedics and Ophthalmology, Faculty of Veterinary Medicine University of Zagreb) .....	9
Figure 5. Sterile fluorescein impregnated paper strip (source: archives of Clinic for Surgery, Orthopedics and Ophthalmology, Faculty of Veterinary Medicine University of Zagreb) .....	13
Figure 6. Halo effect in Indolent ulcer (source: archives of Clinic for Surgery, Orthopedics and Ophthalmology, Faculty of Veterinary Medicine University of Zagreb).....	18
Figure 7. Infected stromal ulcer (source: archives of Clinic for Surgery, Orthopedics and Ophthalmology, Faculty of Veterinary Medicine University of Zagreb) .....	19
Figure 8. Hypopyon (source: archives of Clinic for Surgery, Orthopedics and Ophthalmology, Faculty of Veterinary Medicine University of Zagreb) .....	19
Figure 9. Example of keratomalacia (source: archives of Clinic for Surgery, Orthopedics and Ophthalmology, Faculty of Veterinary Medicine University of Zagreb) .....	20
Figure 10. Distribution of sampled population according to breeds .....	40

## TABLES

Table 1. Classification of corneal ulcers according to depth .....	14
Table 2. Adnexal defects causing corneal ulcers .....	22
Table 3. Breeds of 25 dogs with corneal ulcer .....	39
Table 4. Types of ulcers distribution.....	40
Table 5. Primary causes detected.....	41
Table 6. Isolated bacteria and their antimicrobial susceptibilities.....	41
Table 7. Treatments applied and their time of application .....	42
Table 8. Length of therapy in days according to the type of ulcer .....	42

## ABBREVIATIONS

KCS: Keratoconjunctivitis sicca

CKC: Cavalier king Charles spaniel

ST: Shih tzu

STT: Schirmer tear test

PLR: Pupillary light reflex

ERG: Electroretinography

IOP: Intraocular pressure

TFBUT: Tear film break-up time

CT: Computed Tomography

MRI: Magnetic Resonance Imaging

SCCED: Spontaneous chronic corneal epithelial defects

NSAID: Non-steroidal anti-inflammatories

CN: Cranial nerve

CHV-1: Canine herpesvirus - 1

CDV: Canine Distemper virus

CAV: Canine adenovirus

RGTA: ReGeneraTing Agent

UV A: Ultraviolet A

DBD: Diamond burr debridement

PLR: Pupillary light reflex

## TABLE OF CONTENTS

1.	INTRODUCTION.....	1
2.	LITERATURE REVIEW .....	2
2.1.	Anatomy, histology and physiology of the cornea.....	2
2.2.	Ophthalmological examination .....	4
2.2.1.	History.....	4
2.2.2.	Initial physical assessment and neuro-ophthalmic examination .....	5
2.2.3.	Schirmer Tear Test.....	6
2.2.4.	Ocular sampling .....	7
2.2.5.	Tonometry .....	8
2.2.6.	Anterior segment examination .....	9
2.2.7.	Posterior segment examination .....	11
2.2.8.	Fluorescein tests and additional tests (dyes and imaging) .....	12
2.3.	Corneal ulcers in dogs .....	14
2.3.1.	Definition of corneal ulcers.....	14
2.3.2.	Diagnosis of simple superficial corneal ulcers.....	15
2.3.3.	Different types of complicated corneal ulcers and their patterns during diagnosis	16
2.3.3.1.	Indolent corneal ulcers .....	17
2.3.3.2.	Infected corneal ulcers.....	18
2.3.3.3.	Melting stromal ulcers.....	19
2.3.3.4.	Descemetocelles and perforated ulcers.....	20
2.3.4.	Causes of corneal ulcers.....	21
2.3.4.1.	Mechanical factors.....	21
2.3.4.1.1.	Anatomical defects of the adnexa .....	22
2.3.4.1.2.	Corneal endogenous defects.....	23
2.3.4.1.3.	Tear film deficiencies.....	23
2.3.4.1.4.	Neurogenic causes.....	25

2.3.4.1.5. Traumatic exogenous causes.....	25
2.3.4.2. Infectious etiologies.....	26
2.3.4.2.1. Viral etiologies .....	26
2.3.4.2.2. Mycotic keratitis .....	27
2.3.4.2.3. Bacterial infections .....	27
2.3.4.3. Breed predilections.....	29
2.3.5. Treatments.....	30
2.3.5.1. Medical treatment.....	31
2.3.5.1.1. Basis of medical management of superficial ulcers.....	31
2.3.5.1.2. Medical management of infected ulcers .....	31
2.3.5.1.3. Medical management of deep and melting ulcers.....	32
2.3.5.1.4. Medical management of indolent ulcers .....	33
2.3.5.1.5. Medical management of pain in corneal ulcers .....	33
2.3.5.1.6. Adjunctive therapies and novel therapies .....	34
2.3.5.2. Surgical treatment.....	35
3. MATERIALS AND METHODS.....	38
4. RESULTS.....	39
5. DISCUSSION .....	43
6. CONCLUSION .....	46
7. REFERENCES.....	47
8. SUMMARY .....	57
9. SAŽETAK.....	58
10. CURRICULUM VITAE.....	59

## 1. INTRODUCTION

Corneal ulcers are one of the most often encountered pathologies in canine patient on a daily basis (MILTCHALIEV, 2022; PATEL et al., 2020; O'NEILL et al., 2017; KIM et al., 2009). They can range from a simple ulcer to a complicated condition leading to globe perforation, and can arise from different etiologies, alone or combined, such as trauma, genetic defects or infections. They usually lead to great discomfort of the animal and potential loss of vision. They are usually diagnosed and classified thanks to the anamnesis and a thorough ophthalmological examination, including a Schirmer tear test and fluorescein staining. Therapeutic approach may be medical regardless of cause or severity of condition or may be a combination of surgical procedure and medical approach (SANCHEZ, 2014; LEDBETTER and GILGER, 2013).

The aim of this study is to determine the prevalence of the different types of corneal ulcers in dogs admitted at the Clinic for Surgery, Orthopedics and Ophthalmology Of Veterinary Faculty University of Zagreb from the 24<sup>th</sup> of January 2024 to the 14<sup>th</sup> of June 2024. To the author's knowledge, this is the first study of this type in Croatia and could contribute to a better understanding of the prevalence of corneal ulcerations in populations of dogs in the country and guide future research around this pathology. A systematic diagnostic protocol for data collection has been established including anamnesis, Schirmer tear test 1 and intraocular pressure measurements, and fluorescein staining of the cornea, aiming to unveil the type of ulcers and all their surrounding factors.

## 2. LITERATURE REVIEW

### 2.1. Anatomy, histology and physiology of the cornea

The eyeball is composed of three concentric layers, or tunicae, enclosing three chambers. The different layers of the eyeball are (from outermost to innermost): the fibrous layer, the vascular layer and the inner layer. The chambers are (from anterior to posterior): the anterior chamber between the cornea and iris, the posterior chamber between the iris, ciliary body and lens; and the vitreous chamber or vitreous body, surrounded by the retina and behind the lens.

The cornea is part of the fibrous layer of the eyeball in association with the sclera (LABELLE, 2017). The opaque sclera composes the posterior two third to three quarter of this external layer (BALJIT, 2016) and meets the transparent anterior cornea at the corneal limbus, or corneoscleral junction (LABELLE, 2017; MAGGS, 2008c). The cornea is the anterior transparent part of the eye, making up to one third of the outermost layer, and bulges forward (KONIG et al., 2014). It is mainly made of parallel collagen fibers arranged in lamellar form ensuring absolute transparency essential for optimal vision. The cornea of carnivores in general is rounded and composed of four distinct layers (STARTUP, 1984; LABELLE, 2017).

The anterior epithelium ( $\approx 0.08$  mm) (STARTUP, 1984) is a stratified non-keratinized squamous epithelium, continuous with bulbar conjunctiva (BALJIT, 2016; KONIG et al., 2014), and forms a protective barrier of the stroma by reducing water absorption. The different 'strata' of this epithelium are (from outermost to innermost) the surface cells (flattened polyhedral cells), the intermediate polyhedral wing cells and the basal cells attached to the basement membrane by hemidesmosomes (MAGGS, 2008c), representing 5 to 7 layers (HAMOR et al., 2024; LABELLE, 2017) in dogs. It is kept moist by the precorneal film distributed all over the cornea by eyelids movements and made of serous, mucoid and fatty components (KONIG et al., 2014) and every 5 to 7 days is completely renewed and consequently has a great regenerative potential (LABELLE, 2017). This renewal is made possible by division of basal cells which will force the daughter cells toward the surface as they flatten and lose their organelles, as they will be replaced at limbus by stem cells which will undergo mitosis and migrate centripetally constantly (MAGGS, 2008c).

The stroma ( $\approx 0.5$ mm) is continuous with the sclera (BALJIT, 2016), composed of organized collagen fibers and a few keratocytes, arranged as lamellae, and a watery matrix

(KONIG et al., 2014) containing glycosaminoglycans and other components (LABELLE, 2017). Keratocytes are modified fibroblasts. In between those organized collagen fibers is a dense network of non-myelinated sensory and autonomic nerve fibers arising originally from ophthalmic branch of the trigeminal nerve (BALJIT, 2016). These nerve fibers act primarily as pain receptors on superficial cornea; while those deep in stroma act more as pressure receptors; explaining why more superficial corneal injuries are more painful than deeper injuries (HAMOR et al., 2024). In the stroma we can also find a few scarce lymphocytes, macrophages and neutrophils (MAGGS, 2008c).

Descemet's membrane ( $\approx 14\mu$ ) is the basement membrane of corneal endothelium (KONIG et al., 2014) and so, lies between stroma and corneal endothelium. This membrane is constantly secreted by endothelium (STARTUP, 1984) and consequently thickens with age. It is composed of collagen type IV fibers and laminin which makes it a very elastic structure, but it can still rupture in some pathologies.

The endothelium of cornea is a single cell layer of cuboidal epithelium (STARTUP, 1984; LABELLE, 2017) which acts as a physical barrier between the stroma and the anterior chamber. Similarly to epithelium, it controls diffusion of water from and to the stroma to maintain ideal transparency of the cornea and excretes proteins for the construction of Descemet's membrane (KONIG et al., 2014). Contrary to surface epithelium, corneal endothelium is postmitotic and has almost no ability to replicate or regenerate (LABELLE, 2017). It will be lost with age and the stroma will become thicker owing to subtle edema with aging. Normal canine endothelial cell density is around 2800 cells/mm<sup>2</sup> and corneal decompensation (inability to remove water from stroma) happens when cell density falls below 500-800 cells/mm<sup>2</sup>, causing permanent corneal edema and opacity (MAGGS, 2008c).

The cornea does not contain any blood vessels and gets its supply in nutrients and other elements as they permeate the stroma from limbus' vessels and from the surface of the cornea in lacrimal fluid and aqueous humor, and from bulbar and palpebral conjunctiva (BALJIT, 2016; KONIG et al., 2014). Its thickness is approximately 0.5 to 0.8 mm and depends on region of the cornea and age of the animal, center of the cornea being thinner than periphery (HAMOR et al., 2024; LABELLE, 2017).

Transparency of the cornea (LABELLE, 2017; MAGGS, 2008c) is an essential element for a clear vision. It is enabled by the continuous surface created by corneal nonkeratinized/nonpigmented epithelium and tear film, collagen fibers of stroma and their lamellar arrangement and spacing, and the level of water in the stroma and its avascular nature (MAGGS, 2008c). The dehydrated state of the stroma by epithelium and endothelium act to

exclude water from tear film and anterior chamber (BALJIT, 2016; MAGGS, 2008c). The continuous surface between corneal epithelium and tear film is due to the presence of microvillous projections on surface cells of the epithelium anchoring mucin layer of the tear film (MAGGS, 2008c). The precorneal tear film which is made of mucin, aqueous and the lipid layers, will nourish and lubricate corneal surface, also cleaning it (HAMOR et al., 2024).

## 2.2. Ophthalmological examination

Ophthalmological examination should be complete and detailed to make sure that we are identifying and treating the cause rather than only the clinical signs as soon as possible in the process. It is also important to process to a complete physical examination before focusing on the eye as many systemic diseases may first manifest ocularly (BROOKS, 2005a). The order of the ophthalmological examination is also essential because some procedures and products applications might change the values obtained from procedures/tests (MAGGS, 2008a).

An ophthalmological examination requires some basic supplies and instruments (MAGGS, 2008a; LEWIN, 2021) such as a focal light source, an ophthalmoscope (or lopes – lenses 20D), STT strips and fluorescein strips, a tonometer, 1% tropicamide to induce mydriasis, topical anesthetic such as proparacaine and a sterile eye wash.

### 2.2.1. History

Anamnesis should first aim to determine major problems that have caused the client to present the patient. It is advisable to have a problem-oriented approach, as this will help create an initial list of differentials and will direct the continuation of examination and questioning for further relevant information (MAGGS, 2008a). Habitat, lifestyle and diet are the first concerns of the medical history. Of course, past injuries/diseases come next, this is especially relevant if it is recent or if it is ocular, as well as past or current treatment for the problem addressed or any other chronic treatment and for how long those treatments have been going on.

Vision deficiencies of the patient should be investigated through several questions are they worse at different light settings (day and night)? In familiar or unfamiliar environments? For how long these difficulties have been noticed? Is it improving, deteriorating or stable, and was it sudden or did it progress? (MAGGS, 2008a)

Abnormalities of the eye and of the periocular area should be addressed next: did the owner noticed any discharge from the eye, and if so, what kind? Is the eye seeming painful? Does it look changed in color, transparency or in any other way? (MAGGS, 2008a).



Medical history should also aim to determine if the problem might be of some other origins, especially neurological, so we need to find out if any other clinical signs non ocular might be relevant like recent behavioral or locomotor disturbances. In a multiple pet household, it is important to ask about other animals' medical history and more specifically ophthalmological (MAGGS, 2008a).

### 2.2.2. Initial physical assessment and neuro-ophthalmic examination

The aim of assessment from a distance is to observe any changes in mental status or to notice any deviations in what is considered 'normal' for the dog: asymmetry of the face and all parts of the eyes (resting pupil size and shape, eyelids ...), dermatological problems, changes in visual axis, discharge or dryness of nose and/or eyes, size of openings between eyelids, color changes of the eye and its surrounding, corneal clarity on moistness, evaluation of orbits according to breed's norms. Orbits and eye position can also be evaluated by looking at the animal from above, checking the orbit floor from inside the mouth or palpating orbital rim (BROOKS, 2005a; LEWIN, 2021). During this part of examination, we also assess vision, using tracking of non-smelly and silent items or performing maze test. A neuro-ophthalmic exam should also be performed during this first part of examination. These examinations test the functions of II, III, IV, V, VI and VII cranial nerves. To evaluate these functions we perform: the pupillary light reflex (PLR), the menace response, dazzle and palpebral reflexes as well as the oculocephalic reflex (eyeball movement) (MAGGS, 2008a; LEWIN, 2021).

Aim of PLR is evaluation of reflex constriction of pupils in response to light striking the retina as well as symmetry of the pupils. PLR is tested in both eyes individually but evaluated together as constriction of both eyes should be immediate and almost equal (constriction of directly illuminated eye is slightly greater than that of contralateral eye) (BROOKS, 2005a; MAGGS, 2008a).

The menace response is the eyelid closure in response to a 'threatening' gesture from the examiner. Each eye should be tested individually as unilateral sighted animal will usually close both eyes in response to menace from sighted side. In puppies younger than 10-14 weeks old, menace response will be absent as it is a learned behavior (LEWIN, 2021; MAGGS, 2008a).

Dazzle reflex (as the PLR, is a subcortical reflex and will not help evaluation of visual impairment directly. It consists in the partial or complete closure of eyelids when a very bright light is directed fast into the eye (LEWIN, 2021; MAGGS, 2008a).

The palpebral reflex also consists in closure of eyelids in response to touching skin at medial and lateral canthus. It can be overridden in very fearful animals and decreased/absent if pathologies of the neural arc exist. (LEWIN, 2021; MAGGS, 2008a).

The oculocephalic reflex is evaluated by moving the head to the sides and up and down and analyzing eyeball movements. After and during stimulation, eyes should return in central position and show a physiological and symmetrical nystagmus (MAGGS, 2008a).

### 2.2.3. Schirmer Tear Test

STT is a semiquantitative method to measure production of the aqueous part of tear film (MAGGS, 2008a, LEWIN, 2021). The test is performed with sterile, individually packed paper strips with a 5mm notch on one end used as a mark to fold the strip and hook it at middle to lateral third of lower eyelid for a minute to avoid protection of cornea from third eyelid (cf. Figure 1). There are three types of Schirmer tear tests. STT-1 is the most commonly used and is performed without topical anesthetics. It measures the trigeminal reflex tearing added to physiological secretion (OLLIVIER et al., 2008). Normal STT-1 values in dog are 12-25 mm/min. STT-2 (OLLIVIER et al., 2008) is similar to STT-1 except that cornea and conjunctiva will be topically anesthetized to estimate only basal secretion of tears. It is usually only used in experimental settings. STT-3 can be done with or without topical anesthesia, but its main characteristic is that there is simultaneous stimulation of the nasal mucosa with an alcohol soaked cotton to maximize reflex tearing. It is commonly named nasolacrimal reflex as lacrimation is stimulated through ocular surface reflex but also activation of trigeminal innervation (IWASHITA et al., 2023; TSUBOTA, 1991). A faster method for assessment of tear production is the Phenol Red Thread. This test is thought to be more accurate than STT because it causes minimal stimulation of tear production for a shorter time (BROOKS, 2005a).

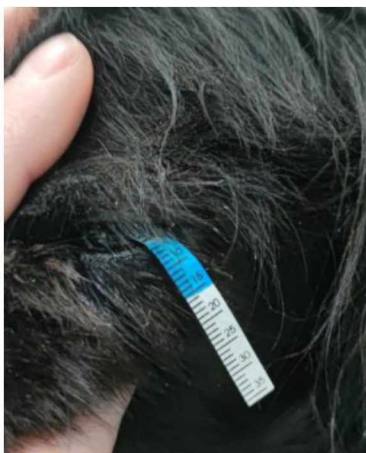

Figure 1. Schirmer tear test (source: archives of Clinic for Surgery, Orthopedics and Ophthalmology, Faculty of Veterinary Medicine University of Zagreb)

#### 2.2.4. Ocular sampling

Ocular sampling by swab or by scraping is used to evaluate presence of microbial pathogens by cytology and culture. The material collected can also be used for other tests such polymerase chain reaction or immunofluorescence. It helps in the diagnosis and classification of corneal and conjunctival diseases and infections as well as their treatment. Any topical products application or rinsing may affect those tests, especially microbial culture so, in ideal conditions, the sampling is done without any topical anesthesia. Even if they contain preservatives, topical anesthetics such as a drop of tetracaine 1% are used for a safe and humane collection of samples (BOTT et al., 2023; MAGGS, 2008a; BROOKS, 2005a).

Cytology provides useful information to start treatment while waiting for microbiology results. A first etiological distinction can be made with it: which type of microorganisms is present, how many are they, are they intracellular or extracellular, is there any type of inflammation. For conjunctival diseases and for most of corneal diseases, cytology is usually not helpful, however cytology can be helpful in case of ulcerative keratitis thought to be of bacterial or fungal nature. Cytological samples can be taken with a swab (premoistened with sterile saline or not), blunt end of a surgical blade (scraping), a cytobrush or a Kimura spatula. Impression smear can also be used by directly applying the glass slide on palpebral lesions or by applying a disc filter-paper specifically treated on corneconjunctival lesions. Cytobrush sampling is considered superior as it will provide superior cellularity of sample, better preservation of cells morphology, less overlapping of cells and collection from deeper layers (BOTT et al., 2023; FEATHERSTONE and SCURRELL, 2015; MILTCHALIEV, 2022).

Microbiology sampling should be done before cytology sampling from primary lesion. To interpret results correctly, clinician must be aware of normal flora present on the eye surfaces. Sample can be collected by gentle rubbing or rolling of a sterile swab (dry or premoistened) on conjunctiva/corneal lesion. Corneal lesions can also be sampled through scraping with Kimura spatula or with the blunt part of a surgical blade followed by collection of the 'accumulation of cells' on the tip of a sterile swab (FEATHERSTONE and SCURRELL, 2015; MILTCHALIEV, 2022).

Any equipments/products used for collection and preservation and growth of sample should be sterile. Indications for sampling ocular surface include purulent inflammation, chronic/unresponsive/severe corneal or conjunctival lesions, deep corneal ulcers melting, severe blepharitis and periocular dermatitis (MAGGS, 2008a).

### 2.2.5. Tonometry

Tonometry is the measurement of intraocular pressure (IOP) which physiologically in dogs are 10-20 mmHg, with similar values between both eyes (no more than 20% variation). IOP measure is essential procedure in diagnose and treatment follow-up in cases of uveitis (reduced IOP) and glaucoma (increased IOP). Four methods can be used to evaluate and measure IOP. If a tonometer is not available, a transpalpebral palpation of the globe might be used but this method is extremely unreliable and may lead to false diagnosis and inappropriate therapy (MAGGS, 2008a).

Indentation tonometry can be performed by applying Schiøtz tonometer (cf. Figure 2) with a standard force to the cornea. Indentation tonometers rely on gravity for an accurate reading and should be placed vertically on horizontal placed corneal surface. Due to restraint of patient and the awkward head positioning, it is very difficult to perform it on small animals, plus ocular rigidity can vary a lot in dogs and influence accuracy of measurement. (MAGGS, 2008a). Tono-pen<sup>®</sup> (cf. Figure 3) and TonoVet<sup>®</sup> (cf. Figure 4) tonometers are both used in everyday practice (LEWIN, 2021). Advantages of the Tono-pen include the ease of use, the accuracy, the head of the patient does not need to be held vertically and so repeated measurements are easier to take, the probe tip is small so it can be covered with a disposable latex cap and it can be applied to non-diseased part of the cornea, also IOP is directly displayed in mmHg on the instrument. Applanation tonometry relies on that force required to flatten surface of a sphere is equal to the pressure inside the sphere. It is performed by gently touching corneal surface with the tip of the instrument through multiple light ‘blotting’ movements.



Figure 2. Schiøtz tonometer (source: archives of Clinic for Surgery, Orthopedics and Ophthalmology, Faculty of Veterinary Medicine University of Zagreb)



Figure 3. Tono-pen® (source: archives of Clinic for Surgery, Orthopedics and Ophthalmology, Faculty of Veterinary Medicine University of Zagreb)



Figure 4. TonoVet® (source: archives of Clinic for Surgery, Orthopedics and Ophthalmology, Faculty of Veterinary Medicine University of Zagreb)

Tono-pen should be held perpendicular to corneal surface and coefficient of variance displayed on the screen should be 5%. Rebound tonometry relies on the time a small probe ejected from tonometer takes to come back to the TonoVet and does not require topical anesthesia. In both cases, the lowest value obtained after repeated measurements should be considered the most accurate (MAGGS, 2008a; LEWIN, 2021).

#### 2.2.6. Anterior segment examination

Anterior segment examination concerns eyelids (including third eyelid), conjunctiva, nasolacrimal apparatus, sclera and cornea, anterior chamber, iris and pupil, and lens (BROOKS, 2005a; LEWIN, 2021). A dim ambient light, a magnifying loupe and a focal light source (ideally Finoff transilluminator) are ideal for a good examination of the anterior segment. This magnification and focal lighting should be used at variable angles to be able to evaluate all the transparent structures of the eye. A simple ophthalmoscopic device is usually enough and found in every practice (MAGGS, 2008a).

When examining eyelids particular attention should be paid to periocular skin (alopecia, scaling, swelling ...), any ocular discharge, eyelid margins and its position, palpebral fissure

size and shape, and disorders of the meibomian gland orifices. Also, disorders of the cilia and periocular hairs should be addressed (e.g. ectopic cilia, distichiasis, trichiasis) (MAGGS, 2008a) gentle digital retropulsion of the globe through upper eyelid is used for examining the third eyelid anterior face. To inspect posterior surface eversion and protrusion with a pair of fixation forceps under local anesthesia is used. During examination of the third eyelid particular attention is made for increased prominence (orbital mass, enophthalmos, Horner's syndrome ...), increase in tissue mass (cherry eye, neoplasia), irregular edges, foreign bodies presence, change in color, moistness and discharge, any abnormalities with the cartilage.

Conjunctival of eyelids and globe (palpebral and bulbar) should be examined by eversion of eyelids. They should be checked for change in color, edema (chemosis), irregularities or masses, moisture, discharges, emphysema or subconjunctival bleeding, obstructed tarsal and/or Meibomian glands (BROOKS, 2005a; MAGGS, 2008a).

Nasolacrimal apparatus is the link between eyes and nose which role is to evacuate tears. It is mostly not visible at examination of eye, only visible parts are the ventral and dorsal puncta are 1-2mm in palpebral conjunctiva in lower and upper eyelids respectively, seen as vaguely raised, but any pathologies of this apparatus may result in ocular and periocular signs (BROOKS, 2005a).

Cornea should be transparent and uncolored. Opacity can be caused by fibrosis, edema, and any types of infiltration, changes in the diameter of the cornea (microphthalmos, buphthalmos or phthisis) should be observed and also the contour and any surface irregularities. Vascularization of the cornea is noted as it is an abnormal finding (MAGGS, 2008a; BROOKS, 2005a). Corneal reflex is also tested by gently touching corneal surface with a sterile cotton eliciting a blink (this should be done before topical anesthesia) (LEWIN, 2021; BROOKS, 2005a).

Sclera naturally comes next into examination being in continuation to cornea, but only the anterior is seen directly (BROOKS, 2005a). For this part, we should look for thinning or thickening, irregularities, changes in contour or in color, visibility and enlargement of small episcleral blood vessels (MAGGS, 2008a).

Anterior chamber of the eye is situated between iris and cornea and is filled with aqueous humor. It is assessed by looking 'across' it from lateral side with focal light. We should assess it from different sides and help ourselves with the focal light source to evaluate its clarity and Sanson-Purkinje images (MAGGS, 2008a). While evaluating anterior chamber, attention should be made to any alterations in depth of the chamber, and also to any abnormal contents due to for example foreign body or hypopyon or increased protein content which will give a



smoke-like impression (aqueous flare) and indicate presence of uveitis (BROOKS, 2005a; LEWIN, 2021).

Iris and pupil are evaluated together before and after pupil dilation. Iris anterior part is better assessed before dilation while posterior iris abnormalities are usually better seen after dilation. We pay particular attention to dyscoria (abnormally shaped pupil) and corectopia (abnormally positioned pupil), if there is more than one aperture in the iris or if the pupil size is abnormal, irideal masses and change in the color of the iris should also be noticed (MAGGS, 2008a).

Last part of examination of the anterior segment of the eye is the examination of the lens. To examine lens, we can use a direct ophthalmoscope with a slit beam and evaluate the Sanson-Purkinje images on the anterior and posterior part of the lens. Most important pathologies of the lens are related to an altered clarity and an altered position. Particular attention should be paid to changes in size, shape and position of the lens, as well as any lens opacity and its progress (different types and causes of cataracts) (MAGGS, 2008a).

#### 2.2.7. Posterior segment examination

At this stage of the ophthalmological examination, we can identify major ocular pathologies present in general practice, but a thorough ophthalmological examination should also include posterior segment, consisting of vitreous, retina, tapetum lucidum, choroid, posterior part of sclera and head of the optic nerve. Posterior segment of the eye, also called fundus, is examined through ophthalmoscopy (direct, indirect, or monocular indirect ophthalmoscopy) after application of tropicamide to induce mydriasis. At this point, focal light and magnification device are necessary for precise examination (MAGGS, 2008a).

The vitreous should be transparent and unnoticeable during the examination, therefore, particular attention should be paid to visible opacities (ex: persistent hyaloid artery, inflammatory exudates ...), aqueous flares (increased protein content), swirling of the vitreous moving with movement of the globe (syneresis), retinal abnormalities (MAGGS, 2008a; BROOKS, 2005a).

Fundus in dog usually as both tapetal and non-tapetal areas with an irregular junction. Tapetum has finely granular appearance and can be gold, blue-green or orange-ish, rest of the fundus being deep brown to black and homogenous. Choroid may be visible in dogs with a subalbinotic non-tapetal fundus part, or in lightly colored or merle dogs (MAGGS, 2008a).

Optic disc (head of optic nerve) is usually situated ventrolaterally to posterior pole of the globe, next to the of junction of the tapetum and is white to pink because of myelin and

capillaries being together. It is important to know the specific patterns of each species for the optic disc to evaluate disorders of each individual. We should pay attention to the size and prominence of the nerve head and any vascular changes (MAGGS, 2008a).

The retinal parts important for fundus examination are the retinal pigmented epithelium, the retinal vessels (seen as fine dark red branching vessels from optic disc) and the neurosensory retina (translucent structure not seen directly but may reduce tapetal reflection dorsally). Diseases of the retina are usually seen as changes in other structures like retinal pigmented epithelium, the tapetal and non-tapetal parts, and the choroid and can be detected by paying attention to changes in color (ex: inflammatory cells, lipid accumulation ...), in reflectivity of the tapetum, and in the vascularization (ex: enlargement, degeneration, hypertension ...) (MAGGS, 2008a).

#### 2.2.8. Fluorescein tests and additional tests (dyes and imaging)

Ophthalmological examination can be completed by additional tests according to findings during examination, history and differentials list. These additional tests can be vital dyes tests to stain eyeball tissues and detect pathologies such as corneal ulcers, and it can also be imaging techniques such as ultrasound or X-rays. Gonioscopy to examine iridocorneal angle or electroretinography (ERG) to evaluate electrical response of the retina to light stimuli are also possible additional tests (MAGGS, 2008a).

Vital dyes such as Rose bengal and fluorescein are used to stain live and dead tissues and very often used in veterinary ophthalmology. Rose Bengal will stain corneal erosion in a brilliant red color. It is also retained by the surface cells of epithelium when their characteristics are changed or when the mucoid part of the tear film is changed. It is mostly used for the diagnosis of keratoconjunctivitis sicca (KCS), mucin tear film deficiency, or early dendritic ulcer with desquamation of the epithelium (MAGGS, 2008a; BROOKS, 2005a).

Fluorescein will stain all hydrophilic structures as it is water-soluble, it will react to slightly alkaline media such as tear film and turn green. As its name states, it is a fluorescent substance to be visible with blue light on ophthalmoscope. Its use is the main way to detect corneal ulcers as it will be retained by stroma. After application of the fluorescein to the cornea, it should be rinsed with saline to avoid artificial stain retention and misdiagnosis. When a cobalt blue light is oriented towards it, fluorescein will fluoresce, making detection of small lesions easier (MILTCHALIEV, 2022; HEINRICH, 2014; STARTUP, 1984; MAGGS, 2008a; BROOKS, 2005a). It is available as an impregnated paper strip (cf. Figure 5) or as a single-use vial (HEINRICH, 2014; FAMOSE, 2018). The paper strip is preferred to avoid an overload of



fluorescein on the cornea which can lead to false positive result, also because of higher propensity to bacterial contamination (especially from *Pseudomonas* species) (HEINRICH, 2014; KERN, 1990). To implement the fluorescein test, the strip is wetted with sterile saline and applied to the conjunctiva of the dorsal fornix without touching the cornea directly as it may lead to false positive. The eyelids are blinked forcibly to distribute the dye on corneal surface (HEINRICH, 2014). As a solution, fluorescein is administered as single use vial at concentration of 0.5% directly on the cornea. The eyelids are again forcibly blinked to distribute fluorescein solution over the cornea. The cornea is then thoroughly rinsed with physiological serum to avoid false positive results (FAMOSE, 2018).



Figure 5. Sterile fluorescein impregnated paper strip (source: archives of Clinic for Surgery, Orthopedics and Ophthalmology, Faculty of Veterinary Medicine University of Zagreb)

The fluorescein is used for three more tests being Seidel and Jones test and the tear film break-up time (TFBUT). In the Seidel test, fluorescein is used to evaluate corneal wounds for perforation and ‘opening’ of the anterior chamber. The concentrated fluorescein is applied to the cornea and not rinsed to follow aqueous humor pattern. If there is a perforation blue light will reveal dark rivulet made by aqueous on the cornea or a dark rivulet inside the chamber anterior due to penetration of the dye through the wound. In Jones test, fluorescein is used to evaluate patency of the nasolacrimal duct. It is applied to the cornea and after 5-10 minutes, the dye should appear at the nostril or in the mouth sometimes. If the Jones test appears negative, flushing the duct with a soft catheter is indicated. TFBUT is used to evaluate stability of the tear film by applying fluorescein to the cornea. After closing eyelids, with magnification and blue light the dorsolateral quarter the tear film is monitored. Time for the tear film to ‘break up’ is measured until dark spots appear in the green fluorescein area. The aim is to evaluate quality mucin quality and quantity in the tear film, normal time in dogs is around 20 seconds and decreased time is synonym of instability (MAGGS, 2008a; LEWIN, 2021).

Imaging techniques are especially useful to assess the surrounding structure of the eye or the eyeball structures not visible due to some opacities. Radiography, ultrasound, computed tomography (CT) or magnetic resonance imaging (MRI) can be used. Radiography of the skull

can show disturbances in and around the orbit, coming from sinuses or the maxilla. CT and MRI provide cross-sectional images with a lot of details and should be preferred over radiography for a more accurate diagnosis and therapy planning. Ultrasonography allows a two-dimensional cross section of the eye and some of the surrounding structures. Mostly is used when usually transparent structures are opaque or to guide a fine needle aspiration (MAGGS, 2008a; BROOKS, 2005a).

### 2.3. Corneal ulcers in dogs

#### 2.3.1. Definition of corneal ulcers

Corneal ulcer, also called ulcerative keratitis, involves the loss of corneal epithelium, and may also include a portion of the stroma (HAMOR et al., 2024). It is usually classified according to depth and if it is simple or complicated (MILTCHALIEV, 2022). An ulcer is histologically described as exposure of the stroma or basement membrane. On the other hand, an erosion is histologically described as a partial loss of epithelial layers without reaching stroma. However, in practice an ulcer is often describe as an epithelial defect involving the stroma, we will prefer this definition (MAGGS, 2018; BOUHANNA et al., 2020). Ulcers can be classified according to their depth as shown in Table 1 (GILGER et al., 2008; MILTCHALIEV, 2022).

Table 1. Classification of corneal ulcers according to depth

Type of ulcer	Description
<b>Superficial</b>	Partial or total loss of corneal epithelium where basement membrane stays intact.
<b>Stromal/deep</b>	Total loss of corneal epithelium and basement membrane and including loss of a part of the stroma, often seen with corneal edema and/or leukocytes infiltration.
<b>Descemetocoele</b>	Deep corneal ulcer where there is a complete loss of epithelium and stroma, revealing the elastic Descemet’s membrane bulging through the lesion
<b>Perforated</b>	Descemet’s membrane and corneal endothelium rupture, leading to leakage of aqueous humor up to an iris prolapsus.

Simple or uncomplicated corneal ulcers are superficial and heal within seven days. They are acute but not infected (HAMOR et al., 2024; MAGGS, 2018) and with well-defined healthy

margins (MILTCHALIEV, 2022). Complicated corneal ulcers are all corneal ulcerations which do not fulfill these requirements. They usually take more than seven days to heal, they can stay superficial with nonadherent reepithelization or get deeper with stromal involvement, they may be infected with microorganisms (HAMOR et al., 2024).

### 2.3.2. Diagnosis of simple superficial corneal ulcers

As with any patient presenting to them, the clinician should start with a thorough physical examination and history which may orientate to primary cause of the lesion such as history of trauma from everyday activities or exposure to materials leading to chemical and/or thermal burns. Causes will be more detailed in the continuation of the text.

Ocular examination is the next step. All parts of the eye should be examined with an ophthalmoscope and a light source that is to say cornea and sclera, anterior and posterior chambers, lens, vitreous chamber and fundus, as well as adnexa. A complete examination is necessary to unveil any clinical signs and lesions of a corneal ulcer and other abnormalities which can be associated to said ulcer (MILTCHALIEV, 2022). To be the most accurate possible, it should be done in a specific order as already stated in the previous part of the text about ophthalmological examination.

Typical clinical sign for superficial corneal ulcers is pain manifested as blepharospasm, attempts to rub the eye with paws or objects (HAMOR et al., 2024), epiphora, enophthalmos and eventually protrusion of third eyelid. Pain is usually more acute in case of superficial ulcers than in deeper ulcers (MILTCHALIEV, 2022; BENTLEY, 2021). During examination, clinician will usually observe serous ocular discharge and hyperemia of conjunctiva in case of simple ulcers (HAMOR et al., 2024). A Schirmer tear test (STT-1) is essential in the diagnosis process of any corneal ulcer (MAGGS, 2018). It should always be performed simultaneously on both eyes. STT-1 results will be increased (>25mm/min) in the eye affected as pain due to the ulcer will lead to reflex tearing and so increase in serous discharge. If the STT-1 result are decreased in one or both eyes, it can be indicative of keratoconjunctivitis sicca (KCS) (HAMOR et al., 2024). Due to fragility of the cornea and pain in deeper ulcers, and the fact that the paper strip can create a slight mechanical irritation of the cornea, STT is sometimes not possible on the affected eye immediately, but it should be performed at least on contralateral eye and/or as soon as possible when the cornea will be more stable (MILTCHALIEV, 2022).

To determine position and type of ulcer, a Fluorescein test is the gold standard (procedure has been describe in Ophthalmological examination) (MILTCHALIEV, 2022; HEINRICH, 2014; STARTUP, 1984). As a hydrophilic dye, fluorescein adheres to hydrophilic

structures of the ocular surface such as intracellular substances between epithelial layers and corneal stroma, but also mucus on corneal surface and on eyelids (KERN, 1990; FAMOSE, 2018). On the other hand, hydrophobic structures like epithelium and Descemet's membrane will not take up fluorescein dye (HEINRICH, 2014; KERN, 1990). Simple superficial ulcers are usually visible with naked eyes as a green staining on the cornea where the lesion happened, but clinician should always confirm with examination with an ophthalmoscope or with a slit lamp, ideally with a blue light source (MILTCHALIEV, 2022; KERN, 1990). Simple superficial ulcers affecting only epithelium will stain quite faintly while deeper ulcers reaching stromal layers will stain more intensely (MILTCHALIEV, 2022). Simple ulcers will show circular, geographic or linear patterns, or a combination of these patterns (BENTLEY, 2021). Location and shape of the lesion may give precious information about the primary cause of the ulcer. A simple ulcer reaching the stroma will with the rest of the epithelium being intact will stain with sharp edges, the zone stained being limited to the zone where epithelium is absent. Also, if this zone is rechecked a bit later during the same consultation, borders should be the same and edges should stay as sharp as before (FAMOSE, 2018).

### 2.3.3. Different types of complicated corneal ulcers and their patterns during diagnosis

Identifying the type of corneal ulcers the patient is suffering from is tremendously important to determine the treatment plan. Complexity of an ulcer is determined by its depth, its chronicity, and its severity. Simple ulcers are usually superficial, without corneal edema and heal quickly. More severe or chronic corneal ulcers are deeper, corneal edema may be seen as a focal blue-gray discoloration. They can also sometimes be vascularized, reach the Descemet's membrane, develop different types of infiltration ... Several types of complicated corneal ulcers exist, and each shows a different pattern at the time of diagnosis according to their causes, or depth, or chronicity, or their clinical course. The basis of diagnosis process of complicated ulcers is the same as for simple ulcers. Fluorescein test and STT should always be performed, additional diagnostic tests can be performed by the clinician according to its suspicion (for example, a microbiological sampling in suspected infected lesion). The different types of complicated corneal ulcers are the following (HAMOR et al., 2024): indolent corneal ulcers or spontaneous chronic corneal epithelial defects (SCCED), malacic (also called melting ulcers) or infected stromal ulcers, descemetocoele when the full thickness of the stroma is absent, and corneal rupture which follow the descemetocoele quickly due to the thinness of the Descemet's

membrane. Fluorescein test will reveal difference in staining of the cornea which will orientate the identification of the type of corneal ulcer (MILTCHALIEV, 2022).

#### 2.3.3.1. Indolent corneal ulcers

Indolent corneal ulcers, also known as Boxer corneal ulcers or more commonly as Spontaneous Chronic Corneal Epithelial Defect (SCCED), are a type of superficial uninfected corneal ulcer. The stroma stays intact but the new epithelium does not adhere to it, leading to the persistence of the erosion. Superficial corneal ulcerations are considered SCCED when they fail to heal within two weeks through normal wound healing process and can persist up to months (WEBB and CAMACHO-LUNA, 2019; BENTLEY, 2005).

SCCED are due to defect of attachment of the basement membrane of epithelium to the stroma. However, the exact mechanism of indolent ulcers is not fully understood even if some morphologic and functional abnormalities have been described (WEBB and CAMACHO-LUNA, 2019). One study found out that the most common feature of specimens was a hyalinized acellular zone on the stroma, acting as a physical barrier between the adhesion complexes of newly produced epithelium and the stromal surface. This was usually combined with newly generated epithelium around the defect exhibiting dysmaturation (BENTLEY et al., 2001; THOMASY, 2020a). Also, in Boxer dogs, epithelial dystrophy is a known causative factor. In epithelial dystrophy, hemidesmosomes of basal epithelium are less numerous and basement membranes are abnormal (BOUHANNA, 2012). Another study, performed on 45 dogs affected by SCCED, investigated alterations in corneal innervation and levels of substance P. An abnormally dense plexus of substance P and calcitonin gene-related peptide immunoreactive nerve fibers had developed in the stroma around the erosion (MURPHY et al., 2001; BENTLEY, 2005). Failure of the epithelium to express some factors (E-cadherin,  $\beta$ -catenin,  $\beta$ -actin, desmoplakin) involved in its migration has been also mentioned (BENTLEY, 2005).

The original corneal lesion can be due to a superficial corneal trauma not always noticed by the owner or can be a spontaneous defect. At examination, epithelium may appear thicker and corneal edema may be noted in the area of the erosion. Fluorescein dye will attach to the stroma underneath the non-adherent epithelium, resulting in a less intense and blurred edges of the staining. Neovascularization can be present with thin and branched blood vessels arising from limbus (BENTLEY, 2005; BOUHANNA, 2012; THOMASY, 2020a).

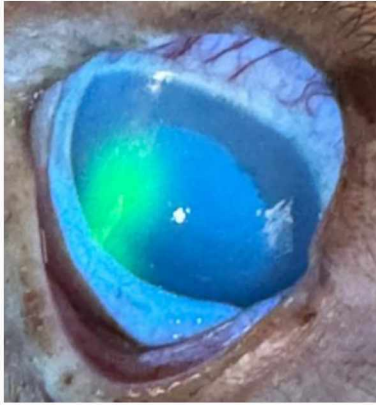

Figure 6. Halo effect in Indolent ulcer (source: archives of Clinic for Surgery, Orthopedics and Ophthalmology, Faculty of Veterinary Medicine University of Zagreb)

#### 2.3.3.2. Infected corneal ulcers

Infected corneal ulcers are usually stromal and can reach up to the Descemet's membrane. They are crater-like defects usually presenting with soft and edematous edges, paste-looking whitish margins (MILTCHALIEV, 2022; KERN, 1990). They are a possible complication of any etiology of corneal ulcers. Main feature of infected ulcers at examination is the stromal infiltration (tan, yellow, or green). It can be accompanied by keratomalacia (melting ulcers).

Normal flora of the cornea is thought to have a role in preventing overgrowth of potentially pathogenic agents through secretion of antimicrobial substances and depriving them from nutrients. Nevertheless, infecting agents can be pathogenic or opportunistic from commensal corneal flora (KERN, 1990; MORALES et al., 2009). Infection of ulcers are usually due to invasion by bacteria, most commonly isolated in dogs being *Staphylococcus*, *Streptococcus*, and *Pseudomonas* species (THOMASY, 2020b) and bacterial ulcers are often accompanied by concurrent anterior uveitis with myosis, aqueous flare and hypopyon (LEDBETTER and GILGER, 2013). Fungal infection is very rare in domestic carnivores but are more and more reported, especially in hot humid environment (THOMASY, 2020b; GOULD and PAPASOULIOTIS, 2013).

In case of infected ulcer, cytological and microbiological sampling should be done (MAGGS, 2008; FEATHERSTONE and SCURRELL, 2015) under topical anesthesia with for example a 1% tetracaine drop is recommended for patient comfort and security (BOTT et al., 2023; THOMASY, 2020b). Sampling is ideally taken from the edges of the lesion and/or from



the stromal infiltrates but can be done from the conjunctival fornix as it demonstrated a 75% correlation (THOMASY, 2020b).

Diagnostic procedure should then be completed with a STT-1 test and fluorescein staining to precisely visualize the extent of damage. In stromal ulcers, infected or not, fluorescein will penetrate through initial epithelial and stromal lesion and will diffuse into area of the cornea where epithelium is intact, it will give a gradually fainting green color to the corneal stroma surrounding the primary defect (HEINRICH, 2014).

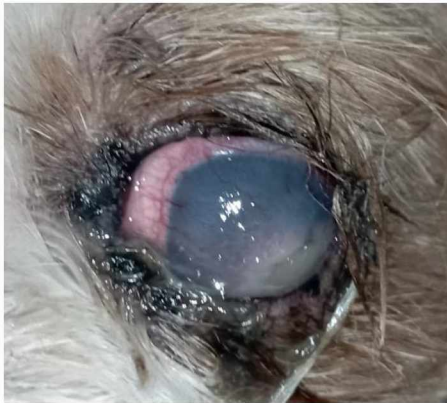

Figure 7. Infected stromal ulcer (source: archives of Clinic for Surgery, Orthopedics and Ophthalmology, Faculty of Veterinary Medicine University of Zagreb)

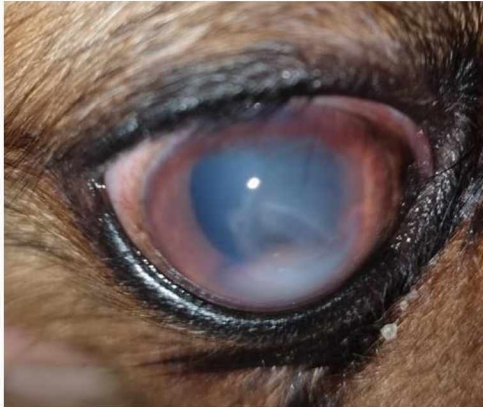

Figure 8. Hypopyon (source: archives of Clinic for Surgery, Orthopedics and Ophthalmology, Faculty of Veterinary Medicine University of Zagreb)

#### 2.3.3.3. Melting stromal ulcers

Melting or malacic stromal ulcers are a complication of stromal ulcers due to a disbalance between proteinases production and their inhibition. These proteolytic enzymes can be normally present in the cornea and produced by keratocytes and epithelial cells, but also inflammatory cells and microorganisms (for example, *Pseudomonas* spp. rarely in dogs,

fungus) and are also present in the tear film (MILTCHALIEV, 2022; ION et al., 2015; OLLIVIER et al. 2007).

Physiological collagenolysis is the balance between production and destruction of the extracellular matrix of the stroma by proteinases. Inhibitors of proteinases are present in the tear film and in corneal cells to avoid a rapidly progressive and uncontrollable lysis of the collagen fibers and proteoglycans of the stroma, leading to corneal perforation (OLLIVIER et al., 2007).

Melting ulcers, or keratomalacia, happen when proteinase inhibitors are overwhelmed by a high presence of activated proteinases usually due to producing microorganisms and inflammatory cells (TSVETANOVA et al., 2021; SANCHEZ, 2014). This type of complication is usually presenting with paste-like, sticky irregular edges of the lesion with white to yellow cellular infiltrates according to cause (MILTCHALIEV, 2022; SANCHEZ, 2014). Even though the appearance of keratomalacia is pathognomonic (TSVETANOVA et al., 2021), its diagnosis should be based on revealing the loss of epithelium accompanied by stromal liquefaction and the presence of cellular infiltrates and corneal edema (ION et al., 2015). As usual, fluorescein test should be performed. In the case of keratomalacia, the hydrophilic dye will stain the degenerative stroma on large areas of the cornea and the ulcer will stain strongly. Care should be taken to rinse thoroughly the lesion and evaluate presence or not of staining at the bottom of the crater-like lesion to avoid the misdiagnosis of a descemetocoele (HEINRICH, 2014; ION et al., 2015).

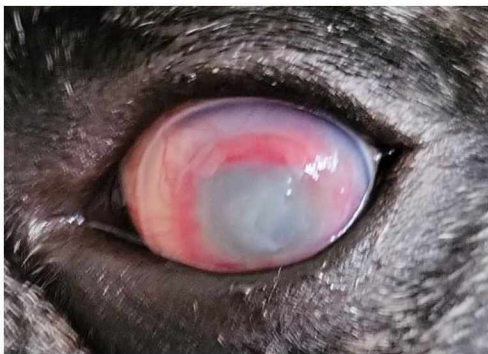

Figure 9. Example of keratomalacia (source: archives of Clinic for Surgery, Orthopedics and Ophthalmology, Faculty of Veterinary Medicine University of Zagreb)

#### 2.3.3.4. Descemetocelles and perforated ulcers

Descemetocoele is a deep corneal ulcer where the entire thickness of epithelium and stroma is absent, reaching the Descemet's membrane secreted by the unique layer of endothelium. It is very thin (3-12  $\mu\text{m}$ ) and can rapidly be breached and lead to corneal perforation



(HAMOR, 2024), therefore it is considered a surgical emergency and should be treated immediately (SANCHEZ, 2014; MILTCHALIEV, 2022). When exposed, Descemet's membrane can bulge under the pressure of aqueous humor (KERN, 1990; BENTLEY, 2021).

Corneal perforation occurs as a complication of any type of ulcer or can be a direct consequence of a traumatic event (MILTCHALIEV, 2022; STRATUP, 1984). It could result in leakage of aqueous humor, iris prolapse and contamination of the anterior chamber (GILGER et al., 2008).

Fluorescein does not stain Descemet's membrane but will stain the surrounding stroma, giving an annular appearance to the ulcer (HAMOR, 2024; FAMOSE, 2018). Center of the ulcer will appear dark and will be surrounded by a 'wall' of edematous stroma staining during the fluorescein test (SANCHEZ, 2014). Thus, when fluorescein is applied and rinsed correctly, descemetocele will have a crater-like appearance like stromal ulcers, but the 'base' of the defect will be dark, and flatten or bulging (BENTLEY, 2021; SANCHEZ, 2014).

Perforated ulcer diagnosis can be straightforward if an iris prolapse is present. Iris will protrude through the corneal lesion and be seen as gelatinous black, gray, or red mass surrounded by edema. With wound healing, iris will merge in the corneal wound, creating an anterior synechia permanently (MILTCHALIEV, 2022; MAGGS, 2018). When perforation is suspected and iris is not prolapsed, fluorescein will be used for the Seidel test to evaluate said perforation and leakage of aqueous humor. As the dye is not rinsed, stroma around the lesion will stain green and aqueous humor is revealed by dark rivulets either on the cornea or in the anterior chamber (HEINRICH, 2014; MAGGS, 2008a).

#### 2.3.4. Causes of corneal ulcers

Etiologies of corneal ulcers are numerous and can sometimes combined. They cause either inadequate corneal protection or excessive corneal irritation and cell loss. Inadequate protection is due to tear film deficiencies, either quantitative or qualitative, or due to eyelids abnormalities of neurological or conformational origins. Excessive cell loss is due to adnexal disease (endogenous causes) or exogenous causes like trauma or infectious agents, the latter rarely being primary cause (MAGGS, 2018; HAMOR, 2024; BENTLEY, 2021).

##### 2.3.4.1. Mechanical factors

Mechanical factors encompass anatomical defects of adnexa and cornea, neurogenic causes, and tear film deficiencies, as well as traumatic exogenous causes.

### 2.3.4.1.1. Anatomical defects of the adnexa

Adnexa of the eye includes everything around and in the orbit except the eye itself and the optic nerve, that is to say: the eyelids, the conjunctival sac, the lacrimal drainage system, the lacrimal gland, and the orbital contents except for the eye and optic nerve (HEATHCOTE, 2021). Adnexal defects able to cause a corneal ulcer are stated in Table 2 (KERN, 1990; HAMOR et al., 2024).

Table 2. Adnexal defects causing corneal ulcers

Adnexal defect	Description
Distichiasis	Single or multiple abnormal hairs growing on the lid margin, adjacent or from meibomian gland orifices (MANNING, 2014; STADES and GELATT, 2008).
Trichiasis	Presence of normally located hairs but abnormally directed to the globe, resulting in chronic corneal irritation (STADES and GELATT, 2008; CARTER, 2021). The misdirected hairs can originate from a cilium from the upper eyelid, a caruncular hair, entropion, or a misaligned eyelid margin (MANNING, 2014).
Ectopic cilia	Atypical form of distichiasis where the abnormal hair arises from follicle inside the meibomian gland through the palpebral conjunctiva and few millimeters from the eyelid margin with cilia always directed to corneal surface and creating ulceration by chronic irritation (STADES and GELATT, 2008; MANNING, 2014).
Entropion	Inversion or rolling in of all or part of the margin of the eyelid causing irritation and ulceration of the cornea through the contact of eyelid hairs directly on the ocular surface (STADES and GELATT, 2008; MANNING, 2014).
Ectropion	Eversion of the lid margin. It is usually seen in combination with an oversized palpebral fissure (macroblepharon or euryblepharon) characterized by a longer lid than normal (STADES and VAN DER WOERDT, 2013).
Lagophthalmos	Incomplete closing of eyelids may be due to facial nerve disorders leading to paralysis of the muscle of eyelids or due to congenital anomalies in breeds with

	prominent eyes. Persistence of the pathology can lead to corneal desiccation due to exposure, leading to ulceration (STADES and VAN DER WOERDT, 2013).
Facial/nasal folds	Cause of corneal ulceration by the same mechanisms as trichiasis, through mechanical irritation of the ocular surface (KERN, 1990; CARTER, 2021; MANNING, 2014). It is mostly seen in brachycephalic breeds but may appear in any animal. When combined with prominent globes and a shallow orbit, it can cause a chronic irritation of the cornea up to ulceration (MAGGS, 2008b).

#### 2.3.4.1.2. Corneal endogenous defects

Defects leading to corneal ulceration can also be endogenous to the cornea and are often resulting in SCCED as they can be challenging to diagnose and cause a recurring erosion if not treated properly. Some of these corneal endogenous defects have been already described in the previous paragraph about “indolent corneal ulcers”. Corneal endogenous defects include abnormalities of the epithelium or of the endothelium of the cornea, commonly called epithelial dystrophy or endothelial dystrophy and are degenerative bilateral pathologies (GRAHN and PEIFFER, 2013).

Epithelial dystrophy as a cause of corneal ulcers has already been proven in Boxer dogs (BOUHANNA, 2012) and affects the basement membrane of the corneal epithelium (GRAHN and PEIFFER, 2013). It displays non-adherent epithelium at the periphery of the lesions due to defects at cellular level manifested by a loss of polarity and disturbed organization of epithelial cells. It is seen at the microscopic level with a clear acellular band on the superficial stroma and an irregular thickened basement membrane. It is thought to result from a lack of hemidesmosomes to attach epithelium to stroma and an increased amount of basement membrane-like material (GRAHN and PEIFFER, 2013; BOUHANNA, 2012; COOLEY and DICE, 1990). Another type of corneal epithelial dystrophy, also known as epithelial erosion syndrome or subepithelial dystrophy, is described in Shetland Sheepdog and occasionally in other breeds. This type is characterized by multifocal circular lesions of 1-3 mm diameters. A metabolic disorder affecting the deposit of lipid around and under epithelial cells is suspected as origin. (GRAHN and PEIFFER, 2013; COOLEY and DICE, 1990; SANCHEZ, 2014).

#### 2.3.4.1.3. Tear film deficiencies

Lacrimal system can also be the origin of ulcerative keratitis by disorder in the production of the tear film, composed of three layers. Decreased production of the aqueous layer of the tear film, most commonly known as keratoconjunctivitis sicca (KCS), is a

quantitative tear film deficiency while decreased production or quality of mucin or lipid layers are considered qualitative tear film deficiencies (BETBEZE, 2022; MOORE, 1990).

Keratoconjunctivitis sicca is a common disease of lacrimal system in dogs and is known by the public as the dry eye disease. It is the deficiency of the aqueous layer of precorneal tear film and get diagnosed with the help of STT-1 under 10mm/minute. It is manifested as drying, desiccation and inflammation of the conjunctiva and the cornea, as well as pain and reduced vision and corneal edema and ulceration (GUILIANO, 2013; BETBEZE, 2022). Due to the lack of aqueous layer, mucin and lipids stay on the cornea and create white sticky discharge on eyelids (BETBEZE, 2022). KCS can have different origins and can be multifactorial (GUILIANO, 2013), it can be: iatrogenic due to drugs or surgery of nictitans glands (MILLER, 2008; HARTLEY, 2014), immune-mediated disorders, infectious disease, breed-related, congenital acinar hypoplasia, trauma or inflammation, age-related, metabolic disease such as diabetes mellitus or hypothyroidism, blepharoconjunctivitis or neurogenic (BETBEZE, 2022; HARTLEY, 2014; MILLER, 2008).

Qualitative tear film deficiencies refer to decreased production or decreased quality of the mucin and/or the lipid layers of the precorneal tear film and their mechanisms are not completely understood yet (BETBEZE, 2022). These impairments are seen with a reduced tear viscosity and a decreased adherence to corneal surface resulting in premature breakdown of the tear film, leading to corneal ulceration by exposure of eye surface (STUCKEY HUEY and CHURCH, 2021). TFBUT is used for initial diagnosis of qualitative tear film deficiencies as STT will often be normal even in the presence of typical clinical signs (BETBEZE, 2022; STUCKEY HUEY and CHURCH, 2021).

Lipid abnormalities are due to disorders of the producing glands and will lead to premature evaporation of the aqueous layer or can be toxic to corneal surface cells. As with KCS, disorders of Meibomian glands are of diverse origins. The inflammation of the mucocutaneous junctions, commonly caused by *Staphylococcus* specie and yeast infections is the most important cause of lipid layer abnormalities. Autoimmune disease affecting mucocutaneous junctions and abnormal development of glands are also described. Margins of eyelids may be swollen and inflamed, and meibomian glands may be seen as beige nodules from which will be excreted a whitish opaque secretion (GUILIANO, 2013; MOORE, 1990).

Mucin layer is responsible for adhesion of the tear to corneal epithelium and has an antimicrobial role (STUCKEY HUEY and CHURCH, 2021). Its deficiency is associated with dysfunction or decreased number of goblet cells (MILLER, 2008; BETBEZE, 2022) after infectious or immune-mediated processes (GUILIANO, 2013). Clinical signs related to this

disorder are a chronic keratoconjunctivitis, corneal ulcers but without ocular discharge and a normal STT value but a decreased TFBUT (under 5 seconds usually) (GUILIANO, 2013; MILLER, 2008; MOORE, 1990).

#### 2.3.4.1.4. Neurogenic causes

Innervation of the cornea arises from the long ciliary nerves, parts of the ophthalmic branch of the trigeminal nerve (CN V) and creates lots of pain receptors in the epithelium. Facial nerve (CN VII) innervates face muscles and eyelids. Deficits or paralysis of CN V and CN VII can lead to corneal erosions and ulcerations (HAMOR et al., 2024; MAGGS, 2008c).

Neurotrophic keratitis/ keratopathy is due to the loss of corneal sensitivity because dysfunction in the CN V. It is seen with abnormal or absent blinking response to stimulus and decreased reflex tearing and so, reduced protection of the eye globe surface (LEDBETTER and GILGER, 2013; MAGGS, 2008c). Sometimes it can be associated with masticatory muscle atrophy and enophthalmos (MAGGS, 2008c). It is a type of chronic keratopathy and a poor corneal healing originating from damage to trigeminal nerve. This lack of sensory innervation will also lead to decreased metabolism of epithelial cells and increased permeability of the corneal surface. Another phenomenon noted in trigeminal nerve deficit is the lack of sensory neuromodulators causing decreased epithelial cell proliferation which can lead to spontaneous epithelial defects (LEDBETTER and GILGER, 2013). Skull conformation, trauma and cavernous syndrome have been evocated as causes of neurotrophic keratitis (SANCHEZ, 2014).

Neuroparalytic keratitis is associated to the paralysis of the facial nerve where there is a lack of blinking, exposing the corneal surface and inadequate distribution of the tear film (SANCHEZ, 2014; MAGGS, 2008c; BROOKS, 2005b). Paralysis of facial nerve is also seen with face muscle flaccid paralysis, unilaterally or bilaterally, giving a ‘droopy’ expression to the dog (LEDBETTER and GILGER, 2013; DE DECKER, 2016). This pathology has been associated with otitis media, trauma, iatrogenic causes after surgery and idiopathic facial neuropathy (SANCHEZ, 2014; MAGGS, 2008c).

#### 2.3.4.1.5. Traumatic exogenous causes

A very common cause of corneal erosion/ulceration is an exogenous traumatic event. Traumas can be from blunt traumas, non-penetrating sharp trauma or penetrating trauma, a corneal foreign body, or a chemical burn (SANCHEZ, 2014; KERN, 1990) and are usually considered emergencies (BJERK, 2004).

Blunt ocular trauma might also cause injuries on other structures of the eye than cornea and consequences can vary from small injuries to severe intraocular hemorrhage or rupture of

the globe. Non-penetrating or penetrating sharp trauma injuries are a common ocular emergency (SANCHEZ, 2014). They are classified as lacerations of the cornea and result from an injury with a sharp object such as nails or blades, but most often they are caused by cat claws in small carnivores (SANCHEZ, 2014; WESTERMEYER, 2013; MAGGS, 2008c). A penetrating injury will be distinguished from a non-penetrating injury by the presence in the anterior chamber of a fibrin clot, and sometimes an iris prolapses (SANCHEZ, 2014).

Corneal foreign bodies are usually from plant material, but any small and sharp material can penetrate or adhere to the corneal surface. Depth of penetration is a very important prognostic factor (SANCHEZ, 2014; WESTERMEYER, 2013). Foreign bodies will cause a great amount of inflammation and pain, especially if they are made of organic matter (SANCHEZ, 2014; MAGGS, 2008c; BJERK, 2004).

Chemical burns of the cornea can be minor or severe, and focal or extensive on cornea. The severity of the injury depends on the chemical content and pH of the product involved in the burn (KERN, 1990). Alkaline products are considered more dangerous than acidic ones because they can penetrate the cornea due to their lipid solubility. Acidic product will provoke coagulation of the corneal collagen which will create a mechanical barrier to the penetration of product. The use of pH strips can be a good diagnostic tool to evaluate possible damage (SANCHEZ, 2014; LEDBETTER and GILGER, 2013; KERN, 1990). Clinical signs of acidic and alkali burns are rather the same and encompass acute blepharospasm, severe corneal opacity, extended corneal erosion, stromal erosion and/or anterior uveitis (LEDBETTER and GILGER, 2013).

#### 2.3.4.2. Infectious etiologies

Primary infectious etiologies of corneal ulcers are very rare in dogs, but a few exist (SANCHEZ, 2014). This part will address the main primary and secondary infectious agents causing ulcerative keratitis or infecting and complicating an already existing lesion.

##### 2.3.4.2.1. Viral etiologies

Even if it is a rarely reported clinical sign, the only virus known to directly cause ulcerative keratitis in dogs is the Canine Herpesvirus-1 (CHV-1) (GOULD and PAPASOULIOTIS, 2013). Ocular signs in adult dogs are mostly a self-limiting conjunctivitis but corneal ulcerations (dendritic, punctate and geographic) after reactivation of virus have also been observed (LEDBETTER et al., 2006; GOULD and PAPASOULIOTIS, 2013) with a self-maintaining nature associated with chronic degenerative corneal disease (LEDBETTER et al., 2012).

Definitive diagnosis of CHV-1 is done through Polymerase Chain Reaction (PCR) or Virus Isolation (GOULD and PAPASOULIOTIS, 2013; LEDBETTER et al., 2006). Corneal ulceration can also be secondary to other primary clinical signs in some viral diseases in dogs even if extremely rare. The two viruses often mentioned in literature are the canine distemper virus (CDV) and the canine adenovirus-1 (CAV-1), however many different viral diseases with a systemic distribution can indirectly lead to corneal ulcerations (GOULD and PAPASOULIOTIS, 2013; AROCH et al., 2008). CDV and CAV-1 have tropism for both epithelial and endothelial cells but will mostly affect endothelial cells in the cornea, causing corneal edema which may predispose to corneal ulceration (VAHLENKAMP, 2017; GOULD and PAPASOULIOTIS, 2013; AROCH et al., 2008) and ocular manifestations usually start with an acute conjunctivitis, following blepharospasm, KCS and consequently possible ulceration of the cornea (AROCHE et al., 2008; GOULD and PAPASOULIOTIS, 2013).

#### 2.3.4.2.2. Mycotic keratitis

As viral keratitis, mycotic keratitis are rare in dogs and can be ulcerative or non-ulcerative (LEDBETTER and GILGER, 2013; THOMASY, 2020b). It is rarely seen in Europe because it develops better in hot and humid environment (tropical and subtropical areas) (GOULD and PAPASOULIOTIS, 2013; MAGGS, 2008c). It is usually secondary infections and fungal microorganisms are usually opportunistic pathogens from the environment even if fungi have demonstrated as part of the normal ocular flora in 22% of dogs (NEWTON, 2012; GRUDON et al., 2010; NEVILE et al., 2016; BROOKS, 2005b). The most commonly isolated fungus is *Aspergillus* spp. *Alternaria*, *Acremonium*, *Cephalosporium*, *Candida*, *Curvularia*, *Hormographiella*, *Pseudallescheria*, and *Scedosporium* spp. have also been mentioned in case reports, with also one mention of *Malassezia pachydermatitis* (LEDBETTER and GILGER, 2013; BEN-SHLOMO et al., 2010; NEWTON, 2012; LEDBETTER and STARR, 2015; PUCKET et al., 2012; GUANDALINI and SAPIENZA, 1996; SCOTT and CARTER, 2014; NEVILE et al., 2016; GRUNDON et al., 2010).

#### 2.3.4.2.3. Bacterial infections

Primary bacterial corneal ulcers are almost impossible because the intact cornea is highly resistant to bacterial invasion however bacterial keratitis is easily happening if there is a breach in anatomic and physiologic defenses of the cornea, usually from opportunistic pathogens of the commensal conjunctival or corneal flora (LEDBETTER and GILGER, 2013; OLLIVIER, 2003). However, bacteria colonizing ulcerative keratitis in animals can also arise

from environment or commensal flora of other part of the body (LEDBETTER and SCARLETT, 2008; TOLAR et al., 2006).

Normal flora of the cornea and conjunctiva is mostly composed of gram-positive microorganisms (*Staphylococcus* spp., *Streptococcus* spp., *Corynebacterium* spp., *Bacillus* spp) and occasionally gram-negative and anaerobic bacteria (*Pseudomonas aeruginosa*, *Escherichia coli*, *Klebsiella*, *Neissaria* spp., *Fusobacterium* spp.) can also be isolated in healthy dogs (MILTCHALIEV, 2022; OLLIVIER, 2003).

Contrary to mycotic ulcerative keratitis, worsening and progression in depth of the lesion is very fast and due to both bacterial products and host defense mechanisms and proteases. Some bacteria possess supplementary virulence factors helping them to invade tissues and destroy them, and escape the immune system (THOMASY, 2020b; LEDBETTER and GILGER, 2013).

The most frequently isolated bacterial microorganisms in dog's ulcerative keratitis are *Staphylococcus* spp., *Streptococcus* spp., and *Pseudomonas aeruginosa* (LEDBETTER and GILGER, 2013; TOLAR et al., 2006; MORALES et al., 2009). Other aerobic bacteria such as *Acinetobacter* spp., *Bacillus* spp., *Corynebacterium* spp., *Enterobacter* spp., *Enterococcus* spp., *Escherichia coli*, etc. Obligate anaerobic microorganism such as *Actinomyces*, *Bacteroides*, *Clostridium*, *Fusobacterium*, *Peptococcus*, and *Peptostreptococcus* spp have also been isolated in infected corneal ulceration even if much rarer (TSVETANOVA et al., 2021; LEDBETTER and GILGER, 2013; LEDBETTER and SCARLETT, 2008; TOLAR et al., 2006). Obligate anaerobes are usually present in combination with aerobes. This can be explained by the fact aerobic bacterial multiplication creates a favorable environment deprived from oxygen and rich in the necessary growth factors for anaerobes development (LEDBETTER and SCARLETT, 2008). Some other bacteria have also been found to colonize corneal ulceration on unique occasion such as *Moraxella canis* in a Bulldog (WANG et al., 2022) or *Salmonella infantis* in mixed-breed dog (ROUTH and McCOOL, 2022). Isolation and susceptibility testing are of tremendous importance in regard to treatment and potential resistance of microorganisms to antibiotics, especially in case of keratomalacia, as prognostic can vary according to microorganisms present. *Pseudomonas aeruginosa* in corneal ulcers are a worsening prognostic factor and can perforate in less than 24 hours because a very fast keratomalacia and a longer healing time (TSVETANOVA et al., 2021; HINDLEY et al., 2015).

Predisposing factors to bacterial keratitis have been identified and include failure of protective mechanisms, corneal trauma or previous ocular surgery, adnexal abnormalities and skull conformation, neurogenic disease, KCS and tear film qualitative deficiencies, SCCED,



decreased corneal sensitivity, topical corticosteroids application. These factors were especially detected in brachycephalic breeds. Geographic localization, climate and direct environment also have a great impact on isolated species from ulcers (TSVETANOVA et al., 2021; AUTEN et al., 2019; HINDLEY et al., 2015; MORALES et al., 2009; TOLAR et al., 2006).

#### 2.3.4.3. Breed predilections

Breed predispositions/predilections to develop corneal ulcers are linked to the primary cause of the initial erosion, this cause being mostly mechanical (O'NEILL et al., 2017; IWASHITA et al., 2020). Usually, a combination of causes due to multiple factors including breed are leading to the different types of corneal ulcers.

Adnexal abnormalities and tear film deficiencies occur more often in breed dogs considered brachycephalic which are consequently more prone to ulcerative keratitis (IWASHITA et al., 2020). They are 2.76 to 20 times more likely than non-brachycephalic breeds to develop corneal ulcers (JAMES-JENKS et al., 2023; PACKER et al., 2015). Those breeds also develop deeper ulcers while non-brachycephalic breeds are more frequently seen with only superficial ulcers. This is due to their skull conformation and length of their muzzles but also due to reduced corneal sensitivity from lower innervation (PALMER et al., 2021; IWASHITA et al., 2020). Skull and face characteristics considered predisposing factors for corneal ulcers in brachycephalic and non-brachycephalic breeds are large eyelid aperture and prominent eyes, short-muzzled skull shape, presence of nasal folds (nasal fold trichiasis) and exposed sclera. These factors usually happen together even if some breeds show only one, for example Shar Peis are mesocephalic dogs but often displaying important nasal folds (PACKER et al., 2015). This abnormal skull conformation creates a physiological exophthalmos very often accompanied by lagophthalmos and incomplete blinking. This is leading to incomplete distribution of the tear film acting as barrier against desiccation and microorganisms, and nourishing the cornea, adding to the risk of developing deep and infected ulcers (PALMER et al., 2021; IWASHITA et al., 2020; AUTEN et al., 2019; O'NEILL et al., 2017; PACKET et al., 2015; TOLAR et al., 2006). Also, dogs with nasal folds are 5 times more likely to develop corneal ulcers. Each 10% of increased in the size of eyelid aperture triples the ulcer risk and same goes for exposure of sclera (PACKER et al., 2015). Several genes have associated with these characteristics and causing disorders (PALMER et al., 2021).

Brachycephalic breeds overrepresented with corneal ulcers are Pugs, Boxers, Bulldogs, Pekingese, Boston terriers, and Shih Tzu (ST) (PALMER et al., 2021), however ST seems to be the most represented breed of all (O'NEILL et al., 2017). Cavalier King Charles Spaniel (CKC),

English Bulldogs, Lhasa Apsos, Pugs, and ST are the brachycephalic breeds most affected by KCS or qualitative tear film disorders, and consequently which have shown incidence of corneal ulcers (PALMER et al., 2021; IWASHITA et al., 2020; PACKER et al., 2015). English Bulldogs tend to present at young age with entropion and distichiasis (PALMER et al., 2021).

Some non-brachycephalic breeds have also been significantly reported with corneal ulcers such as Toy poodle (IWASHITA et al., 2020) or Staffordshire Bull Terrier. Spaniel breeds are also 3 times more likely than other breeds to develop corneal ulceration and it is thought to be also due to skull conformation and large palpebral fissure typical for those breeds (O'NEILL et al., 2017). However, KCS is thought to be one of the main etiology of corneal ulcers in non-brachycephalic breeds (PACKER et al., 2015).

SCCED, also called Boxer ulcers, have a well-known breed predilection in Boxer dogs of course but also in Corgi, Pekingese, Lhasa Apso, Golden Retriever, Staffordshire Bull Terrier, American Bully, West Highland White Terrier (WHWT) and many other breeds and mixed breeds (JAMES-JENKS et al., 2023; LEDBETTER and GILGER, 2013; BROOKS, 2005b; MOORE, 2003), brachycephalic breeds being again overrepresented for this pathology (MICHAUD, 2022). The genetic breed predisposition in Boxers has been investigated. A genetic defect in Noggin, a protein constitutive of the cornea, has been associated with SCCED in this breed (MEURS et al., 2021)

Additionally, endogenous corneal dystrophies can be primary causes of corneal ulceration and usually have a familial basis. Some breeds are therefore 'predisposed' to these disorders. Epithelial dystrophy is often seen in Boxer, Shetland Sheepdog, Siberian Husky, Bichon Frisé, American Cocker Spaniel, Collie, German Shepherd, and CKC. Endothelial dystrophy on the other hand is most commonly diagnosed in Boston terrier, Dachshunds and Chihuahuas (LEONARD et al., 2021; SAPIENZA, 2002; COOLEY and DICE, 1990).

#### 2.3.5. Treatments

In most cases, simple superficial corneal ulcers do not require a huge treatment. Generally, only topical antibiotics are applied three to four times a day to avoid complications by infection and some topical pain medication to reduce discomfort (SANCHEZ, 2014; LEDBETTER and GILGER, 2013). However, when a simple ulcer complicates or is recurrent, treatment is required, and investigation of underlying cause is absolutely necessary for adapted therapy (MAGGS, 2008c; BROOKS, 2005b). Therapeutic goals for complicated ulcers, besides finding and treating primary cause/process, are to avoid or stop microbial growth, stop any deepening and stromal melting, control discomfort and pain, and eventual structural support

(THOMASY, 2020b; BROOKS, 2005b). Medical therapy, except if the ulcer is already too deep or perforated, is always attempted first and can be changed according to evolution of the lesion. Surgery is considered when the ulcer is complicated, long lasting or refractory to medical management (CASSAGNES, 2019) and should be done in combination with medical treatment.

#### 2.3.5.1. Medical treatment

A very important element to remember for topical treatment of the eye and particularly of cornea is that corneal epithelium and endothelium are hydrophobic and lipophilic, while stroma is hydrophilic and lipophobic (HAMOR et al., 2024). Consequently, if the goal for the treatment is to reach the entire corneal thickness, it needs to be both fat-soluble and water-soluble (polar and non-polar moiety) (STARTUP, 1984).

##### 2.3.5.1.1. Basis of medical management of superficial ulcers

In simple superficial ulcers, aim of the treatment is to avoid complications and decrease pain of the patient. Topical antibiotics and pain relief are generally enough. Antibiotics used in first intention should be broad spectrum. The triple antibiotic combining neomycin with polymyxin B and bacitracin or gramicidin is widely used on simple ulcer prophylactically because of its very broad spectrum and the action of polymyxin B against *Pseudomonas* spp. (MILTCHALIEV, 2022; CASSAGNES, 2019; MAGGS, 2008c). Chloramphenicol and fusidic acid are good first choices because of their large spectrum and low toxicity to corneal cells. Gentamicin or tobramycin can also be used as first intention but are not recommended prophylactically because gentamicin has been associated with delayed epithelial healing, and both showed poor efficacy against conjunctival flora (SANCHEZ, 2014; HVENEGAARD et al., 2011; MAGGS, 2008c; SAPIENZA, 2002). On the other hand, tetracyclines may be beneficial due to both their capacity to upregulate some growth factors and stimulate production of new epithelium, and their broad spectrum (MILTCHALIEV, 2022; THOMASY, 2020a).

##### 2.3.5.1.2. Medical management of infected ulcers

When initial signs of infection appear, a more aggressive therapy will be needed. In those cases, an antibiogram is important to determine the best antimicrobial therapy to do and avoid creating resistance of microorganisms. Even if they should be avoided as much as possible due to human use, fluoroquinolones (for e.g. ofloxacin or ciprofloxacin) have shown high efficacy against many bacteria and can be administered topically or systematically (marbofloxacin, enrofloxacin) if neovascularization is present (CASSAGNES, 2019; MAGGS, 2008c). Furthermore, topical fluoroquinolones will delay corneal healing (MILTCHALIEV,

2022). One study shows the best coverage in bacterial stromal ulcers is offered by a combination of the triple antibiotic combined with either ofloxacin or amikacin (JOKSIMOVIC et al., 2023; GUYONNET et al., 2020). Subconjunctival injections of antibiotics are possible but cannot replace the efficacy of a frequent topical therapy (MAGGS, 2008c).

If infection is due to fungus, a wide spectrum antibiotic therapy should be combined with antifungal treatment as mycotic ulcers usually show presence of both fungus and bacteria. Voriconazole, natamycin, itraconazole and miconazole are used to treat corneal fungal infection, however voriconazole is considered the best choice because of its broad spectrum and its good corneal penetration and its low toxicity (THOMASY, 2020b; NEVILE et al., 2015; SCOTT and CARTER, 2014).

#### 2.3.5.1.3. Medical management of deep and melting ulcers

Basis of the medical therapy stays the same with deeper stromal ulcers but the frequency of topical application of antibiotics and mydriatics should be highly increased (hourly at least the first two days) because all stromal ulcers are considered infected and highly susceptible to melting until proven otherwise (SAPIENZA, 2002). In case of already melting ulcer, some studies recommend a combination of an aminoglycoside (for e.g. tobramycin or gentamycin) with chloramphenicol, others recommend a combination of the triple antibiotic with fluoroquinolones, or cefazolin as stand alone. All of those therapy may be efficient but the mainstay in literature is the importance of the susceptibility testing (JOKSIMOVIC et al., 2023; GUYONNET et al., 2020; TSVETANOVA et al. 2020; HINDLEY et al., 2015).

Melting corneal ulcers progress quickly to perforated ulcers which means they are an ocular emergency. When surgery is not possible, proteases inhibitors/anticollagenases topical products can be attempted to stop the keratomalacia, always in combination with antibiotics and pain control. Acetylcysteine or Ethylenediaminetetraacetic acid (EDTA) are good options, but the preferred therapy today is autologous serum as, in addition to anticollagenase properties, it has numerous growth factors and fibronectins thought to be beneficial. New techniques for autologous richer in platelets or in growth factors have been developed more recently and showed good results used on corneal ulcers healing. It can be applied as drops or as subconjunctival injections (FARGHALI et al., 2021; CASSAGNES, 2019; MICHAUD, 2013). Tetracyclines (for e.g. oxytetracycline, doxycycline) also demonstrated anticollagenases and anti-inflammatory properties and can be used in melting ulcers (MILTCHALIEV, 2022).

Cross linking is another option in the treatment of stromal melting ulcers if at least a third of the stroma is intact. It uses activation of riboflavin (vitamin B2) by Ultraviolet A (UV

A) for antimicrobial activity and polymerisation activity helping reorganization of collagen fibers. This will cause increased rigidity of the cornea and increased resistance to proteases activity, leading to healing of the keratomalacia without surgical procedure even sedation or general anesthesia of the patient is necessary (MILTCHALIEV, 2022; CASSAGNES, 2019; FAMOSE, 2017). Cross linking is also thought to stimulate neovascularization of the cornea which will accelerate wound healing (MARCHEGIANI et al., 2022).

#### 2.3.5.1.4. Medical management of indolent ulcers

SCCED being a particular type of superficial ulcer, medical therapy alone is rarely successful to treat it and generally require at least surgical debridement under local anesthesia. However, on a pharmacological point of view, SCCED is medicated the same way as other superficial ulcer would be, with being even more vigilant to pain and infection due to the size of the exposed corneal surface. Disposable lens can be placed to help with this purpose (CASSAGNES, 2019; SANCHEZ, 2014). Other topics can also be attempted such as topical fibronectin (improves migration and adhesion of cells), autologous serum, hyperosmotic agents, proteases inhibitors, topical substance P in combination with some growth factors (BENTLEY, 2005; SAPIENZA, 2002).

Thermal cautery on SCCED consists in mechanical debridement of loose epithelium with cotton swab then the use of a thermal cautery unit to create multiple small superficial burns on the debrided zone by approaching the hot unit, provoking slight contraction of collagen fibers. Ideally it is done without sedation, only with local anesthesia of the eye. As in surgical techniques, the treated zone can be helped to completely heal with the placement of a disposable lens, and always combined with an antimicrobial therapy (BENTLEY and MURPHY, 2004) Thermal cautery of SCCED shows increased risk if not performed correctly. It should be used as last resort when the patient is not responsive to conventional approaches (THOMASY, 2020a; BENTLEY and MURPHY, 2004).

Another alternative to classical keratotomy after debridement of the indolent ulcer is the use of chemical cauterization. Some cauterizing solutions such as iodine or trichloroacetic acid is applied on the borders of the lesion with a sterile cotton swab and is then rinsed with sterile saline (BOUHANNA, 2012; HVENEGAARD et al., 2011).

#### 2.3.5.1.5. Medical management of pain in corneal ulcers

Mydriatics are used to reduce pain associated with anterior uveitis often associated to ulceration. Topical mydriatic-cycloplegic drugs can be applied to control pain by reducing

ciliary and irideal spasms (THOMASY, 2020a; SANCHEZ, 2014). Atropine 1% is the most widely used for this purpose, but clinician should bear in mind that it decreases the tear production (DE GEYER, 2015; HVENEGAARD, 2011; MAGGS, 2008c).

To control ocular pain, topical or systemic (*per os*) options are available. Oral NSAIDs (for e.g. carprofen, meloxicam) are analgesics used in corneal ulcers as, contrary to corticosteroids, there is no evidence of delay in epithelial healing with it (THOMAY, 2020a; SANCHEZ, 2014), however topical NSAIDs (for e.g. diclofenac) may also delay corneal healing and aggravate bacterial ulcers, and do not seem really efficient for pain control. They are also irritant and can increase blepharospasm and epiphora so then should be avoided (MILTCHALIEV, 2022; THOMASY, 2020b; MICHAUD, 2013; REGNIER, 2012). Oral opioids (for e.g. tramadol) can also be used for pain management of corneal ulcers. Disposable contact lenses can also be an option in superficial and non-infected ulcers (SANCHEZ, 2014). Corticosteroids, especially topical, should be absolutely avoided as they will delay epithelial healing, predispose to infections, and increase the risk of keratomalacia (MILTCHALIEV, 2022; THOMASY, 2020b; REGNIER, 2012).

#### 2.3.5.1.6. Adjunctive therapies and novel therapies

In addition to antimicrobials and pain medications, clinician can feel the need for adjunctive therapy. Artificial tears based on hyaluronic acid and/or carbomers can also help stabilizing precorneal tear film and thus healing of the lesion. They will also lead to dilution of inflammatory mediators. Ointments with vitamins B12 and A can also be interesting because of their lubricating properties (CASSAGNES, 2019; JUGANT and DOUET, 2017; MICHAUD, 2013).

In case of the superficial stroma being affected, a new type of matrix therapy arises called ReGeneraTing Agent (RGTA). RGTA helps stabilizing hemostasis of the extracellular matrix by protecting growth factors and angiogenic factors which will contribute to synthesis of collagen and development of the extracellular matrix (MARTINEZ et al., 2019; CASSAGNES, 2019; JUGANT and DOUET, 2017; MICHAUD, 2013).

In a newer approach to corneal ulcers, use of mesenchymal cells subconjunctivally has been tried. Mesenchymal stem cells have the capacities to modulate inflammatory response and differentiate in keratocytes and produce new collagen. In addition, they will stimulate neovascularization of the cornea and promote endogenous regeneration (PALAFOX-HERRERA et al., 2023).

Antiplasmin agents, such as aminocaproic acid or polysulphated glycosaminoglycan or aprotinin, also been mentioned in the treatment of refractory epithelial ulcers. They are used to counteract the excess of plasmin in tear film present and initiating abnormal degradation of fibronectin matrix (REGNIER et al., 2005).

#### 2.3.5.2. Surgical treatment

Surgery is considered in addition to medical therapy in case of significant stromal loss (more than 50% of stroma thickness), corneal melting or long lasting and refractory more superficial ulcers. Regularly used surgical procedures include corneal debridement, conjunctival grafting, corneoscleral or corneoconjunctival transpositions (THOMASY, 2020b; SANCHEZ, 2014; MAGGS, 2008c). Corneal grafting with exogenous materials is also practiced in case of refractory ulcers (CASSAGNES, 2019)

Debridement of epithelium is used to treat SCCEDs and is not recommended for infected and melting ulcers. The goal is to remove non adherent epithelium and create an abrasion to stimulate adhesion of the newly generated epithelium. Two types are done: debridement with a cotton swab and diamond burr debridement (DBD). It can be done under local or general anesthesia (CASSAGNES, 2019; SANCHEZ, 2014). Debridement with a cotton swab impregnated with sterile saline can be done without sedation or anesthesia on compliant patients and when a keratotomy is not planned in addition. Alone, this type of debridement gives has a success rate at first try of approximately 50% (WU et al., 2018). Diamond burr has better success rate than cotton swab debridement. To increase the outcome of debridement, grid or punctate keratotomy can complete the procedure, very often with placement of a disposable contact lens and sometimes with tarsorrhaphy or third eyelid flap. Success rate at first try of DBD with or without a keratotomy is approximately the same and 75% to 100% (HUNG et al., 2020; WU et al., 2018). Superficial keratectomy can be attempted if keratotomy failed to heal the ulcer. It is a more invasive technique of complete removal of abnormal layer of stroma (THOMASY, 2020a; CASSAGNES, 2019; SANCHEZ, 2014; BOUHANNA, 2012).

Conjunctival grafting will provide a continuous blood supply helping the stabilization of the collagen and reducing corneal edema present (SANCHEZ, 2014) as well as a ‘delivery’ route for systemic drugs used (MILTCHALIEV, 2022; MAGGS, 2008c), however main disadvantage of this technique is the lack of transparency possible at the end of healing (ROBIN and DOUET, 2018). This technique also demonstrated antimicrobial and anticollagenase properties (MILTCHALIEV, 2022). The graft will fuse with the cornea and can be trimmed 6

to 8 weeks after placement. Cyclosporine solution can eventually be applied to reduce vascularization at the end of healing by the graft. Conjunctival graft is generally a band of bulbar conjunctiva sutured to the cornea but can also be completely detached from the conjunctiva (island graft) or bridging and stay attached in two points to the conjunctiva. Choice of the type of pedicle used depends mostly on the size of the lesion (MAGGS, 2008c).

Corneoscleral and corneconjunctival transpositions provide directly corneal tissue, thus there is better transparency at healing but are more difficult and longer to perform (ROBIEN and DOUET, 2018; SANCHEZ, 2014). Transpositions is better taken from dorsal part of the cornea to decrease frictions from the movements of eyelids (MICHAUD, 2024).

Corneal grafting is used in refractory or deep ulcers affecting more than 50% of stromal thickness. It can be autologous by taking part of the intact cornea in the same or contralateral eye. Autologous grafts are lamellar (only stroma is taken) or the entire thickness of the cornea is grafted at lesion, the latter require a donor and use of anti-rejection treatment. Corneal grafting comes more often from exogenous biomaterials such as amniotic membrane or intestinal submucosa (MILTCHALIEV, 2022; CASSAGNES, 2019; ROBIN and DOUET, 2018). Biomaterials used for corneal grafts should be resistant to proteolytic enzymes, stimulate epithelialization, create minimal immune reaction and give back transparency to the cornea. Swine intestinal submucosa is widely used as corneal graft because its composition promotes proliferation and migration of cells from the stroma and stop the synthesis of proteolytic enzymes. Biomaterial from urinary bladder of swine is a bit more complex as it has two different sides, one with an acellular membrane protecting the epithelium and one with an acellular collagen complex. Acellularity of this material create less immune response. Amniotic membranes are very interesting because they support epithelial but also axonal regeneration, the number of layers used from the graft can be adapted to the depth of the ulcer. The graft, according to its apposition side will act as a bandage or be completely incorporated to the corneal tissue. However, they are much more fragile and complex to use. Another option described is bovine pericardium. It is more resistant but much longer to heal and get back transparency (ROBIN and DOUET, 2018).

Tarsorrhaphy and third eyelid flap are kept in place approximately 15 days (BOUHANNA et al., 2020; ROBIN and DOUET, 2018). It can be applied as an alternative to disposable lens or as an addition to its placement, or in complement to a corneal grafting procedure (CASSAGNES, 2012; BOUHANNA, 2012). Third eyelid flap is the attachment of the nictitating membrane to the superior eyelid to create a mechanical barrier to irritations.



Tarsorrhaphy is the closing of the eye by suturing the eyelids together, it can be only lateral to allow application of topical treatments and surveillance of the lesion (MILTCHALIEV, 2022).

### 3. MATERIALS AND METHODS

This retrospective study aims to analyze the population of dogs presented with corneal ulceration to the Clinic for Surgery, Orthopaedics and Ophthalmology Of Veterinary Faculty of the University of Zagreb (VEF UNIZG) between the 24<sup>th</sup> of January 2024 and the 14<sup>th</sup> of June 2024. During this period, 30 dogs were presented with corneal ulcer to the clinic.

Including criteria were a diagnostic procedure including anamnesis of the animals, a complete ophthalmological examination which must involve fluorescein test and a STT-1, and a collection of data on each patient which being sex, age, breed, type of corneal ulcer, status of patient (primary care or referral), choice of treatment and length of treatment at VEF UNIZG. Excluding criteria are incomplete diagnostic information regarding fluorescein test and STT-1, and lack of follow-up of patient.

Patient data were collected from VEF UNIZG protocol software and analysed through Microsoft Excel for descriptive statistical analysis. Every owner has signed an agreement to enter this retrospective study and this research has been approved by the Ethical committee of the VEF UNIZG.

#### 4. RESULTS

Out of the 30 dogs diagnosed with corneal ulceration to the Clinic for Surgery, Orthopaedics and Ophthalmology of VEF UNIZG from the 24<sup>th</sup> of January 2024 and the 14<sup>th</sup> of June 2024; 2 dogs were excluded because of incomplete diagnostic information and 3 because of lack of follow-up data at the clinic. 44% of dogs included in the study were considered brachycephalic, 40% were non-brachycephalic breeds and 16% were mixed breed dogs. Detailed breeds of the 25 dogs included are displayed in the Table 3, and distribution according to breed categories is represented on Figure 10.

Sex distribution among dogs included in the study was 56% males and 44% of females. Mean age of patients was  $7.36 \pm 3.09$  years old (range: 2-10 years old). 56% of patients were referred by their primary veterinarian to VEF UNIZG while 44% of them were brought by their owners to VEF UNIZG as a primary care. The type of ulcers and their prevalence are displayed in the Table 4. 56% of ulcers affected the right eye and 44% affected the left eye.

Table 3. Breeds of 25 dogs with corneal ulcer

Breed	Number of dogs (total 25)	Percentage (%)
American Staffordshire terrier	2	8
Swiss white shepherd	1	4
Boston terrier	2	8
Cane canario	1	4
Shi-tzu	2	8
French bulldog	6	24
Yorkshire terrier	2	8
Samoyed	1	4
Weimaraner	1	4
Maltese dog	1	4
Bichon frisé	1	4
Beagle	1	4
Mixed breed	4	16

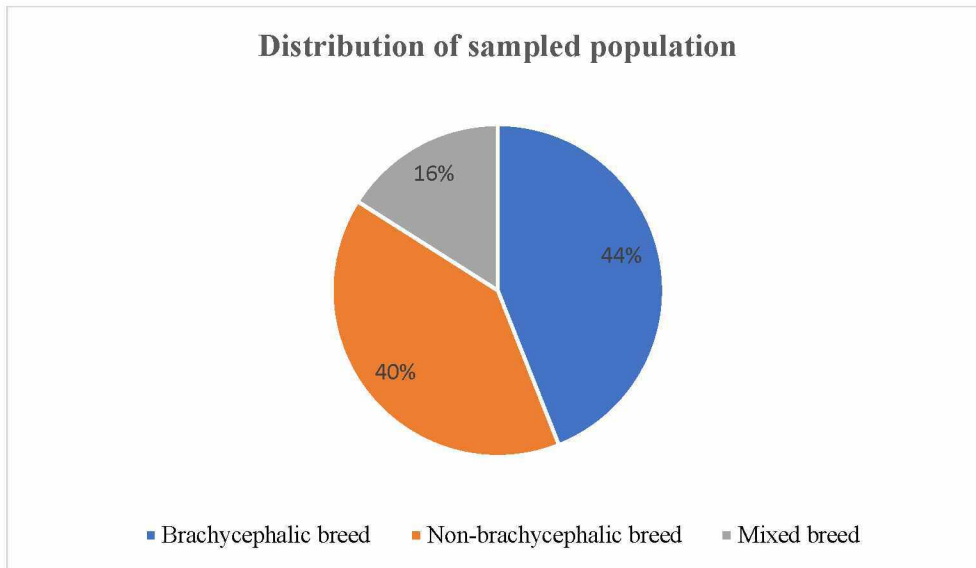


Figure 10. Distribution of sampled population according to breeds

Table 4. Types of ulcers distribution

Type of ulcer	Number of dogs (total 25)	Percentage (%)
Simple superficial ulcer	6	24
SCCED	11	44
Infected ulcer	3	12
Deep uninfected ulcer	3	12
Keratomalacia	2	8

One of the dogs with keratomalacia complicated to perforation necessitating a conjunctival graft and a partial lateral tarsorrhaphy, so 50% of keratomalacia got complicated.

Mean STT-1 value in observed population was  $20.2 \pm 7.99$  (range: 0- >30 mm/min), three of them being lower or equal to 12 mm/min and mean IOP value was  $24.5 \pm 11.17$  (range: 12-71 mmHg). Myosis was noted in 10 patients.

Primary cause was mostly undiagnosed due to the difficulty of collecting accurate anamnesis. Notable primary causes are listed in the table 5.

Table 5. Primary causes detected

Primary cause	Number of dogs
Eyelid problems	
Euryblepharon	1
Ectopic cilia	1
Tear film deficiency	
Lipid deficiency	1
KCS	3
Trauma	3
Foreign body	1
Chemical burn	1

Microbiological samples were taken from 3 corneal ulcers and analysis and susceptibility testing was done with Laboklin laboratory. List of detected microorganisms and their susceptibility is listed in the table 6.

Table 6. Isolated bacteria and their antimicrobial susceptibilities

Antimicrobial susceptibility test	Isolated bacteria		
	<i>Enterobacter bugadensis</i>	<i>Staphylococcus pseudointermedius</i>	<i>Streptococcus salivarius</i>
Penicillin	R	S	R
Amoxicillin/clavulanic acid	R	S	S
Cephalexin	R	S	S
Cefovectin	R	S	R
Macrolides	R	S	S
Lincosamides	R	S	S
Fusidic acid	R	S	R
Aminoglycosides	S	S	R
Fluoroquinolones	S	S	S
Tetracyclines	S	S	S
Phenicols	S	S	S
Trimetoprim sulfa	S	S	S
Polymyxin B	S	R	R
Nitrofuration	S	S	R

All dogs received antibacterial therapy topically as first-line treatment upon arrival VEF UNIZG (tobramycine or fluoroquinolones). In addition to antibacterial treatment, first-line therapy be completed with cycloplegic drops, topical NSAID, cyclosporine (immunosuppressant), artificial tears and/or proteases inhibitors. One dog did not receive any

treatment due to the extremely superficial nature of the erosion as this one resolved by itself. Treatments provided at the time of arrival and its therapeutic process are detailed in Table 7.

Median length of treatment from the first visit at VEF UNIZG to the last follow-up control is of  $14\pm 8$  days (range: 0-32 days). Detailed length of therapy according to the type of ulcer is displayed in Table 8.

Table 7. Treatments applied and their time of application

Treatment	Started at first visit		Started during control	
	Number (total 24)	Percentage (%)	Number (total 24)	Percentage (%)
Topical antibacterials (tobramycine or/and fluoroquinolones)	24	100	2*	8.33*
Cyclosporine	9	37.5	1	4.17
Artificial tears	15	62.5	3	12.5
Diamond burr debridement with disposable lens	4	16.7	5 (*1)	20.8(*4.17)
Topical pain control (atropine 1% or/and NSAID)	5	20.8	5 (*1)	20.8(*4.17)
Proteases inhibitors (EDTA or serum)	2	8.33	*1	*4.17

(\*number of change or addition of medication)

Table 8. Length of therapy in days according to the type of ulcer

Type of ulcer	Mean length of treatment in days
Simple superficial ulcer	$9.33\pm 5.57$
SCCED	$15.27\pm 6.78$
Infected ulcer	$16\pm 4.36$
Deep uninfected ulcer	$19.5\pm 11.27$
Keratomalacia	$20\pm 11.31$

## 5. DISCUSSION

The aim of this study was to establish descriptive statistics of the population of dogs presented with corneal ulceration to the Clinic for Surgery, Orthopaedics and Ophthalmology Of Veterinary Faculty of the University of Zagreb (VEF UNIZG) between the 24<sup>th</sup> of January 2024 and the 14<sup>th</sup> of June 2024. During this period, 30 dogs were presented with corneal ulcer to the clinic; 25 met the inclusion criteria.

Majority of males entered the study (56%) which is in agreement with PATEL et al. (2020) and O'NEILL et al. (2017) studies. However, according to literature, no sex predisposition exists (MURPHY et al., 2001; JAMES-JENKS et al., 2023). Mean age of patients in this study is  $7.36 \pm 3.09$  years old which is much higher than what found KIM et al. (2009) where mean age was  $3.59 \pm 2.97$  years old, or PATEL et al. (2020) where main population was also younger. However, O'NEILL et al. (2017) had a median age of 7.2 years old at diagnosis which much more similar to our study even though their sample was much bigger.

44% of all dogs and 52.4% of purebred dogs were brachycephalic dogs. This finding is similar to KIM et al. (2009), PATEL et al. (2020) and O'NEILL et al. (2017) studies, and predisposition to corneal ulcers is confirmed by JAMES-JENKS et al. (2023) study. French bulldogs were overrepresented in this study and encompassed 24% of all the cases and 54.5% of all cases in brachycephalic breeds. In non-brachycephalic breeds, the most important populations were Yorkshire terrier (8%) and American Staffordshire terrier (8%), this can be explained by the relatively large eyes and the skull conformation of those breeds. It is completely different than from IWASHITA et al. (2020) which reported Pembroke Welsh Corgi and Toy poodle to be the 2 non-brachycephalic breeds most commonly affected by ulcerative keratitis, however their sample is much larger and much more diverse in terms of breeds represented.

In terms of clinical data, SCCED were the most often reported type of ulcer (44%) followed by simple superficial ulcers (24%) and infected ulcers (12%) and deep uninfected ulcers (12%). These findings are slightly different than from PATEL et al. (2020) where superficial ulcers were the main pathology followed by SCCED but were similar to KIM et al. (2009) and even lower than in JAMES-JENKS et al. (2023) study. We can presume that this difference in prevalence of different types of ulcers is due to multiple factors such as the size of the sample, breeds represented, age distribution and geographic localization which may influence genetics and environmental factors. According to IWASHITA et al. (2020) study, brachycephalic breeds also seem more prone to deeper ulcers certainly due to their morphology.

Superficial and deep uninfected ulcers took respectively  $9.33 \pm 5.57$  days and  $19.5 \pm 11.27$  days to heal in our study. In KIM et al. (2009) research, superficial ulcers healing time was approximately the same as us. Half of the admitted keratomalacia complicated which lead to perforation, however, none of the other types of ulcers showed signs of complications during this study. Melting ulcers had an average healing time of  $20 \pm 11.31$  days in our study. GUYONNET et al. (2020) reported a similar rate of complications and medical success (31/57 melting ulcers healed only with intensive medical treatment), however healing time was shorter as they reported success in the first 15 days of treatment. This difference is probable due to the difference in the size of the sample.

Mean STT-1 value was  $20.2 \pm 7.99$  mm/min however it is important to notice the very wide range of values with the smallest reported value being 0 mm/min so a complete absence of secretions, and the biggest value being over 30 mm/min. WILLIAM and BURG (2017) reported that STT-1 values are always significantly higher in affected eye due to the reflex tearing induced by pain, this was also reported by MURPHY et al. (2001) In our study, mean IOP value stays in normal range, however WILLIAM and BURG (2017) stated IOP is usually decreased in corneal ulcerations. This difference can be due to the handling of patients and their stress which might have increased IOP values in our study. Also, IOP was not always measured due to the fragility of the cornea.

One of the main primary causes describe in our study was KCS. It was diagnosed in a mixed breed dog, a Yorkshire terrier and a French bulldog. This differs from the results of SANCHEZ et al. (2007) were the CKC and ST were the main breeds diagnosed with KCS which developed corneal ulcer. In that study starting point was KCS and not corneal ulcers, Furthermore, our sample size is smaller. The other main primary cause unveiled in our retrospective study was trauma (4 animals were diagnosed with trauma as primary cause for corneal ulcer if we count the one with the foreign body). PATEL et al. (2020) had similar findings in terms of order of prevalence of primary causes.

Only 3 microbiological samples were taken and tested for susceptibility in our study. Microorganisms isolated were *Staphylococcus pseudintermedius*, *Streptococcus salivarius* and *Enterobacter bugandensis*. In multiple studies, *Staphylococcus pseudintermedius* and *Streptococcus spp.* have been isolated one of the main bacteria from corneal ulcers. All of these studies coming from different countries, it is interesting to see that predominance of *Staphylococcus spp.* and *Streptococcus spp.* in ulcerative keratitis seems to a global phenomenon. However, *Enterobacter spp.* are much less often encountered (JOKSIMOVIC et



al., 2023; MILTCHALIEV, 2022; AUTEN et al., 2019; TOLAR et al., 2006; VERDENIUS et al., 2023; HINDLEY et al., 2015)

Susceptibility testing is the most important procedure when determining antimicrobial treatment in infected ulcers. Many studies recommend fluoroquinolones combined with another antibiotic upon arrival of patients on their practice, this is probably due to the fact this kind of studies often happen in referral centers and the animal already received antibacterial treatment before entering the study. In France fluoroquinolones are very rarely used as first line therapy ( GUYONNET et al., 2020). On the other hand, more and more studies show an increase in resistance of *Streptococcus spp.* to fluoroquinolones such HINDLEY et al. (2015) study. In our study, 100% received of dogs received one topical antibiotic on first visit, most of them being treated with ciprofloxacin as first line, the rest being treated with tobramycin. Except *Streptococcus salivarius* which was resistant to tobramycin, all our isolates were susceptible to both ciprofloxacin and tobramycin.

Diamond burr debridement with placement of a disposable lens was the treatment of choice for non-healing superficial ulcers (SCCED). It was attempted in total 9 times and only 1 had to be repeated. In our study, all ulcers treated with diamond burr debridement and disposable lens placement healed. WU et al. (2018) reported a healing rate after first attempt of 77.4% and HUNG et al. (2020) reported 73.9%. Our study reported a higher healing rate after first attempt (8/9) but our sample was much smaller and WU et al. (2018) and HUNG et al. (2020) has much more significative results.

Main limitations of our study are the small size of the sample which did not allow very significative statistics, and the lack a common protocol for examination and reports by the clinicians collecting the data. This study could be interesting to extend in time to increase the size of the sample and create a more solid base for statistical analysis. Even though 44% of the cases of this study have been reported as primary care cases, VEF UNIZG welcome mostly more complicated cases primary care clinics in Croatia. This could also be more relevant to try to involve smaller and more traditional clinics in this kind of study in a similar way as O'NEILL et al. (2017) study.

## 6. CONCLUSION

- Main population affected by corneal ulcers are brachycephalic dogs with an overrepresentation of French Bulldogs.
- Simple superficial corneal erosions and SCCED are the most common type of corneal in dogs.
- In all cases of corneal ulcerations, deep ulcers or presence of keratomalacia can develop complications which can lead to corneal perforation.
- Even without antibiogram, empirical treatment with fluoroquinolones and aminoglycosides was efficient in treatment of corneal ulcers.

## 7. REFERENCES

1. AROCH, I., R. OFRI, G. SUTTON (2008): Ocular Manifestations of Systemic Diseases. In: Slatter's fundamentals of veterinary ophthalmology, (MAGGS, D. J., P. E. MILLER, R. OFRI, Eds.), 4th ed., Saunders, Elsevier, St Louis, Missouri, USA, pp.374-418.
2. AUTEN, C., J. URBANZ, D. D. DEES (2019): Comparison of bacterial culture results collected via direct corneal ulcer vs conjunctival fornix sampling in canine eyes with presumed bacterial ulcerative keratitis. *Vet. Ophthalmol.* 23, 135-140. DOI: 10.1111/vop.12698
3. BALJIT, S. (2016): The Sense Organs. In: Dyce, Sack, and Wensing's Textbook of Veterinary Anatomy (BALJIT, S. Ed.), 5<sup>th</sup> ed., Saunders, Elsevier, St Louis, Missouri, USA, pp. 319-320.
4. BENTLEY, E. (2021): Keratitis, ulcerative. In: Blackwell's Five-Minute Veterinary Consult: Canine and Feline (TILLEY, L. P., F. W. K. SMITH, M. M. SLEEPER, B. M. BRAINARD, Eds.) 7th ed. Wiley Blackwell, Hoboken, New Jersey, USA, pp. 798-799.
5. BENTLEY, E. (2005): Spontaneous Chronic Corneal Epithelial Defects in Dogs: a Review. *J. Am. Anim. Hosp. Assoc.* 41, 158-165. DOI: 10.5326/0410158
6. BENTLEY, E., G. ABRAMS, D. COVITZ, C. COOK, C. FISCHER, D. HACKER, C. STUHR, T. REID, C. MURPHY (2001): Morphology and Immunohistochemistry of Spontaneous Chronic Corneal Epithelial Defects (SCCED) in Dogs. *Inv. Ophthalm. Vis. Sci.* 42, 2262-2269.
7. BENTLEY, E., C. MURPHY (2004): Thermal cautery of the cornea for treatment of spontaneous chronic corneal epithelial defects in dogs and horses. *J. Am. Vet. Med. Assoc.* 224, 250-253. DOI: 10.2460/javma.2004.224.250
8. BEN-SHLOMO, G., C. PLUMMER, K. BARRIE, D. BROOKS (2010): *Curvularia* keratomycosis in a dog. *Vet. Ophthalmol.* 13, 126-130. DOI: 10.1111/j.1463-5224.2010.00766.x
9. BETBEZE, C. (2022): Restoring Brilliance – Update on Dry Eye Disease. WVC Conference 2022, 6-9<sup>th</sup> of March 2022, Las Vegas, Nevada, USA
10. BJERK, E. (2004): Ocular Injuries in General Practice. World Small Animal Veterinary Association World Congress Proceedings, 6-9<sup>th</sup> of October, Rhodes, Greece
11. BOTT, M., P.-L. DESHUIILLERS, S. CHAHORY (2023): Corneo-conjunctival cytology: the sampling (in French). *Prat. Vet.* 223, 51-54.

12. BOUHANNA, L., C. MARINGUE, C. ALLGEYER (2020): Corneal ulcer: learn to manage this emergency (in French). *Dépêche Vét.* 1519, 15-19.
13. BOUHANNA, L. (2012): Managing persistent corneal ulcers in dog and cat (in French). *Dépêche Vét.* 1190, 16-18.
14. BROOKS, D. (2005a): Ophthalmic Examination Made Ridiculously Simple. World Small Animal Veterinary Association World Congress Proceedings, 11-14<sup>th</sup> of May, Mexico City, Mexico
15. BROOKS, D. (2005b): How to Keep the Windshield Clean: Rapid and Aggressive Corneal Ulcer Diagnosis and Therapy. World Small Animal Veterinary Association World Congress Proceedings, 11-14<sup>th</sup> of May, Mexico City, Mexico
16. CASSAGNES, C. (2012): Covering by the nictitating membrane (in French). *Prat. Vet.* 47, 342-345.
17. CASSAGNES, C. (2019): The ocular surfaces: Modifications of color and form. In: Course to follow in ophthalmology of dog and cat (in French) (CHAUDIEU, G., C. CASSAGNES, L. BOUHANNA, Eds.), éditions MED'COM, Paris, France, pp. 112-118.
18. CARTER, R. T. (2021): Eyelash Disorders (Trichiasis/Distichiasis/Ectopic Cilia). In: Blackwell's Five-Minute Veterinary Consult: Canine and Feline (TILLEY, L. P., F. W. K. SMITH, M. M. SLEEPER, B. M. BRAINARD, Eds.) 7th ed. Wiley Blackwell, Hoboken, New Jersey, USA, p. 482.
19. COOLEY, P., P. DICE (1990): Corneal Dystrophy in the Dog and Cat. *Vet. Clin. N. Am. Small.* 20, 681-692. DOI: 10.1016/s0195-5616(90)50057-1
20. DE DECKER, S. (2016): Neurological Disorders Affecting the Head and Face. World Small Animal Veterinary Association Congress Proceedings, 27-30<sup>th</sup> of September, Cartagena, Colombia
21. DE GEYER, G. (2015): Analgesic drugs in ophthalmology (in French). *Prat. Vet.* 50, 86-89.
22. FAMOSE, F. (2017): Interest in collagen cross-linking (CXL) for the treatment of corneal ulcers (in French). *Prat. Vet.* 52, 198-200.
23. FAMOSE, F. (2018): Fluorescein test and "pooling" effect (in French). *Prat. Vet.* 165, 44-46.
24. FARGHALI, H., N. ABDELKADER, H. ABUBAKR. E. RAMADAN, M. KHATTAB, N. SALEM, I. EMAM (2021): Corneal Ulcer in Dogs and Cats: Novel Clinical

- Application of Regenerative Therapy Using Subconjunctival Injection of Autologous Platelet-Rich Plasma. *Front. Vet. Sci.* 8, 641265. DOI: 10.3389/fvets.2021.641265
25. FEATHERSTONE, H., E. SCURRELL (2015): Ocular sampling in the dog and cat. In *Practice*. 37, 510-539. DOI:10.1136/inp.h5720
  26. GILGER, B., F. OLLIVIER, E. BENTLEY (2008): Diseases and Surgery of the Canine Cornea and Sclera. In: *Essentials of Veterinary Ophthalmology* (GELATT, K., Ed.), 2nd ed., Wiley-Blackwell, Ames, Iowa, USA, pp. 126-140.
  27. GOULD, D., K. PAPASOULIOTIS (2013): Clinical Microbiology and Parasitology. In: *Veterinary Ophthalmology* (GELATT, K., B. GILGER, T. KERN, Eds.) 5th ed., Wiley Blackwell, Ames, Iowa, USA, pp. 300-350
  28. GUANDALNI, A., J. SAPIENZA (1996): Keratomycosis in a Dog: A Case Report. *Anim. Eye Res.* 15, 123-126. DOI: 10.11254/jsevo.15.3-4\_123
  29. GIULIANO, E. (2013): Diseases and Surgery of the Canine Lacrimal Secretory System. In: *Veterinary Ophthalmology* (GELATT, K., B. GILGER, T. KERN, Eds.) 5th ed., Wiley Blackwell, Ames, Iowa, USA, pp. 912-944.
  30. GUYONNET, A., L. DESQUILBET, J. FAURE, A. BOURGUET, E. DONZEL, S. CHAHORY (2020): Outcome of medical therapy for keratomalacia in dogs. *J. Small Anim. Pract.* 61, 253-258. DOI: 10.1111/jsap.13118
  31. GRAHN, B., R. PEIFFER (2013): Veterinary Ophthalmic Pathology. In: *Veterinary Ophthalmology* (GELATT, K., B. GILGER, T. KERN, Eds.), 5th ed., Wiley Blackwell, Ames, Iowa, USA, pp. 435-523.
  32. GRUNDON, R., A. O'REILLY, C. MUHLNICKEL, C. HARDMAN, R. STANLEY (2010): Keratomycosis in a dog treated with topical 1% voriconazole solution. *Vet. Ophthalmol.* 13, 331-335. DOI: 10.1111/j.1463-5224.2010.00799.x
  33. HAMOR, R., G. NEWBOLD, C. BETBEZE (2024): Keratitis, Ulcerative (Canine). *VINyclopedia of Diseases*, <https://www.vin.com/members/cms/project/defaultadv1.aspx?pid=607&id=5110515&f5=1>
  34. HARTLEY, C. (2014): The lacrimal system. In: *BSAVA Manual of Canine and Feline Ophthalmology* (GOULD, D., G. J. McLELLAN, Eds.), 3rd ed., British Small Animal Veterinary Association, Gloucester, UK, pp.167-199.
  35. HEATHCOTE, J. G. (2021): The ocular adnexa. *Saudi J. Ophthalmol.* 35, 167-169. DOI: 10.4103/SJOPT.SJOPT\_43\_22

36. HEINRICH, C. (2014): The ocular examination. In: BSAVA Manual of Canine and Feline Ophthalmology (GOULD, D., G. J. McLELLAN, Eds.), 3rd ed., British Small Animal Veterinary Association, Gloucester, UK, pp.1-23.
37. HINDLEY, K., A. GROTH, M. KING, K. GRAHAM, F. M. BILLSON (2015): Bacterial isolates, antimicrobial susceptibility, and clinical characteristics of bacterial keratitis in dogs presenting to referral practice in Australia. *Vet. Ophthalmol.* 19, 418-426. DOI: 10.1111/vop.12325
38. HUNG, J., K. LEIDREITER, J. WHITE, M. BERNAYS (2020): Clinical characteristics and treatment of spontaneous chronic corneal epithelial defects (SCCEDs) with diamond burr debridement. *Vet. Ophthalmol.* DOI : 10.1111/vop.12772
39. HVENEGAARD, A.P., J. VIEIRA, D. LEANDRO, A.C. GOES, A. SAFATLE, P. BARROS (2011): Retrospective study on clinical management of indolent ulcers in Boxer dogs. *Pesq. Vet. Bras.* 31, 910-915. DOI: 10.1590/S0100-736X2011001000012
40. ION, L., I. IONASCU, A. BIRTOIU (2015): Melting keratitis in dogs and cats. *Agric. Agric. Sci. Procedia.* 6, 342-349. DOI: 10.1016/j.aaspro.2015.08.090
41. IWASHITA, H., L. SEBBAG, B. LEONARD, A. SAITO (2023): A review of diagnostic tests for qualitative and quantitative tear film deficiency in dogs. *Vet. Ophthalmol.* 26, 5-15. DOI: 10.1111/vop.13044
42. IWASHITA, H., S. WAKAIKI, Y. KAZAMA, A. SAITO (2020): Breed prevalence of canine ulcerative keratitis according to depth of corneal involvement. *Vet. Ophthalmol.* 23, 849-855. DOI: 10.1111/vop.12808
43. JAMES-JENKS, E., C. PINARD, P. CHARLEBOIS, G. MONTEITH (2023): Evaluation of corneal ulcer type, skull conformation, and other risk factors in dogs: A retrospective study of 347 cases. *Can. Vet. J.* 64, 225-234.
44. JOKSIMOVIC, M., B. FORD, T. LAZIC, I. SOLDATOVIC, S. LUZETSKY, S. GROZDANIC (2023): Antibiotic Recommendations for Treatment of Canine Stromal Corneal Ulcers. *Vet. Sci.* 10, 66. DOI: 10.3390/vetsci10020066
45. KERN, T. J. (1990): Ulcerative Keratitis. *Vet. Clin. North. Am. Small Anim. Pract.* 20, 643-666. DOI: 10.1016/s0195-5616(90)50055-8
46. KIM, J. Y., H-J. WON, S-W. JEONG (2009): A Retrospective Study of Ulcerative Keratitis in 32 Dogs. *Int. J. Appl. Res. Vet. Med.* 7, 27-31.
47. KONIG, H. E., H-G. LIEBICH, P. SOTONYI (2014): Eye (organum visus). In: *Veterinary anatomy of domestic mammals.* (LIEBICH, H-G., H. E. KONIG, Eds.), 6th ed., Schattauer, Stuttgart, Germany, pp. 579-591.

48. JUGANT, S., J-Y. DOUET (2017): Corneal healers : what place in the treatment of ulcers ? (in French). *Prat. Vet.* 52, 30-34.
49. LABELLE, P. (2017): The Eye. In: *Pathologic Basis of Veterinary Disease* (ZACHARY, J. Ed.), 6<sup>th</sup> ed., Elsevier, St Louis, Missouri, USA, p. 1269
50. LEDBETTER, E., J. STARR (2015): *Malassezia pachydermatis* keratomycosis in a dog. *Med. Mycol. Case Rep.* 10, 24-26. DOI: 10.1016/j.mmcr.2016.01.001
51. LEDBETTER, E., B. GILGER (2013): Diseases and Surgery of the Canine Cornea and Sclera. In: *Veterinary Ophthalmology* (GELATT, K., B. GILGER, T. KERN, Eds.), 5th ed., Wiley Blackwell, Ames, Iowa, USA, pp. 976-1049.
52. LEDBETTER, E., C. MARFURT, R. DUBIELZIG (2012): Metaherpetic corneal disease in a dog associated with partial limbal stem cell deficiency and neurotrophic keratitis. *Vet. Ophthalmol.* 16, 282-288. DOI: 10.1111/j.1463-5224.2012.01064.x
53. LEDBETTER, E., J. SCARLETT (2008): Isolation of obligate anaerobic bacteria from ulcerative keratitis in domestic animals. *Vet. Ophthalmol.* 11, 114-122. DOI: 10.1111/j.1463-5224.2008.00610.x
54. LEDBETTER, E., R. RIIS, T. KERN, N. HALEY, S. SCHATZBERG (2006): Corneal ulceration associated with naturally occurring canine herpesvirus-1 infection in two adult dogs. *J. Am. Vet. Med. Assoc.* 229, 376-384. DOI: 10.2460/javma.229.3.376
55. LEONARD, B., C. KERMANIAN, S. MICHALAK, P. KASS, S. HOLLINGSWORTH, K. GOOD, D. MAGGS, S. THOMASY (2021): A Retrospective Study of Corneal Endothelial Dystrophy in Dogs (1991–2014). *Cornea.* 40, 578-583. DOI: 10.1097/ICO.0000000000002488
56. LEWIN, A. (2021): How to Do a Great Eye Examination. Southwest Veterinary Symposium, 23-26 September, San Antonio, Texas, USA, p.178
57. MAGGS, D. (2008a): Basic Diagnostic Techniques. In: *Slatter's fundamentals of veterinary ophtalmology*, (MAGGS, D. J., P. E. MILLER, R. OFRI, Eds.), 4th ed., Saunders, Elsevier, St Louis, Missouri, USA, pp.81-105
58. MAGGS, D. (2008b): Eyelids. In: *Slatter's fundamentals of veterinary ophtalmology*, (MAGGS, D. J., P. E. MILLER, R. OFRI, Eds.), 4th ed., Saunders, Elsevier, St Louis, Missouri, USA, pp. 107-134
59. MAGGS, D. (2008c): Cornea and Sclera. In: *Slatter's fundamentals of veterinary ophtalmology*, (MAGGS, D. J., P. E. MILLER, R. OFRI, Eds.), 4th ed., Saunders, Elsevier, St Louis, Missouri, USA, pp.175-202

60. MAGGS, D. (2018): Cornea and Sclera. In: Slatter's fundamentals of veterinary ophthalmology, (MAGGS, D. J., P. E. MILLER, R. OFRI, Eds.), 6th ed., Saunders, Elsevier, St Louis, Missouri, USA, pp.213-245
61. MANNING, S. (2014): The eyelids. In: BSAVA Manual of Canine and Feline Ophthalmology (GOULD, D., G. J. McLELLAN, Eds.), 3rd ed., British Small Animal Veterinary Association, Gloucester, UK, pp.133-166.
62. MARCHEGANI, A., R. GIALLETTI, M.P. CASSARANI, M. CERQUETELLA, A.R. ATTILI, G. LOMBARDO, M. LOMBARDO, A. SPATERNA, R. ARCELLI (2022): Riboflavin/UV-A corneal phototherapy as stand-alone management of ulcerative keratitis in dogs. *Vet. Med-Czech.* 67, 190-198. DOI: 10.17221/46/2021-VETMED
63. MARTINEZ, J., F. CHIAPPINI, D. BARRITAU (2019): : Case Reports for Topical Treatment of Corneal Ulcers with a New Matrix Therapy Agent or RGTA® in Dogs. *Vet. Sci.* 6, 103. DOI: 10.3390/vetsci6040103
64. MEURS, K., K. MONTGOMERY, S. FRIEDENBERG, B. WILLIAMS, B. GILGER (2021): A defect in the NOG gene increases susceptibility to spontaneous superficial chronic corneal epithelial defects (SCCED) in boxer dogs. *BMC Vet. Res.* 26. DOI: 10.1186/s12917-021-02955-1
65. MICHAUD, B. (2024): Step by step: Realizations of a corneconjunctival transposition (in French). *Point Vét.* 451, 90-91.
66. MICHAUD, B. (2022): Chronic superficial ulcers of bulldogs (in French). *L'Essentiel Vétérinaire.* 285, 16-24.
67. MICHAUD, B. (2013): Medical management of corneal ulcers: Use of RGTA (in French). *Essentiel Vét.* 651, 15-16.
68. MILLER, P. (2008): Lacrimal System. In: Slatter's fundamentals of veterinary ophthalmology, (MAGGS, D. J., P. E. MILLER, R. OFRI, Eds.), 4th ed., Saunders, Elsevier, St Louis, Missouri, USA, pp. 157-174
69. MILTCHALIEV, C. (2022): Retrospective Study of 53 Melting Corneal Ulcers in Dogs presented at ENVA between 2017 and 2020 (in French). DVM Thesis, Ecole nationale vétérinaire d'Alfort, Maisons-Alfort, France.
70. MOORE, C. (1990): Qualitative Tear Film Disease. *Vet. Clin. North. Am. Small Anim. Pract.* 20, 565-581. DOI: 10.1016/s0195-5616(90)50071-6
71. MOORE, P. (2003): Diagnosis and Management of Chronic Corneal Epithelial Defects (Indolent Corneal Ulcerations). *Clin. Tech. Small Anim. Prac.* 18, 168-177. DOI: 10.1053/svms.2003.YSVMS32



72. MORALES, A., M. A. R. VALINHOS, M. SALVADEGO, C. E. LEVY (2009): Microbiological and Clinical Aspects of Corneal Ulcers in Dogs. World Small Animal Veterinary Association World Congress Proceedings, 21-24 July, Sao Paulo, Brazil
73. MURPHY, C., C. MARFURT, A. McDERMOTT, E. BENTLEY, G. ABRAMS, T. REID, S. CAMPBELL (2001): Spontaneous Chronic Corneal Epithelial Defects (SCCED) in Dogs: Clinical Features, Innervation, and Effect of Topical SP, with or without IGF-1. *Inv. Ophth. Vis. Sci.* 42, 2252-2261.
74. NEVILE, J., S. HURN, A. TURNER (2016): Keratomycosis in five dogs. *Vet. Ophthal.* 19, 432-438. DOI: 10.1111/vop.12313
75. NEWTON, E. (2012): *Scedosporium apiospermum* keratomycosis in a dog. *Vet. Ophthal.* 15, 417-420. DOI: 10.1111/j.1463-5224.2012.01012.x
76. OLLIVIER, F., B. GILGER, C. PLUMMER, K. BARRIE, D. BROOKS (2007): Proteinases of the cornea and precocular tear film. *Vet. Ophthal.* 10, 199-206. DOI: 10.1111/j.1463-5224.2007.00546.x
77. OLLIVIER, F., C. PLUMMER, K. BARRIE (2008): Ophthalmic Examination and Diagnostics; Section 1: The eye examination and Diagnostic procedures. In: *Essentials of Veterinary Ophthalmology* (GELATT, K., Ed.), 2nd ed., Wiley-Blackwell, Ames, Iowa, USA, pp. 3-22.
78. OLLIVIER, F. (2003): Bacterial Corneal Diseases in Dogs and Cats. *Clin. Tech. Small Anim. Pract.* 18, 193-198. DOI: 10.1053/svms.2003.YSVMS30
79. O'NEILL, D., M. LEE, D. BRODBELT, D. CHURCH, R. SANCHEZ (2017): Corneal ulcerative disease in dogs under primary veterinary care in England: epidemiology and clinical management. *Canine Genet. Epidemiol.* 4, 5. DOI: 10.1186/s40575-017-0045-5
80. PACKER, R., A. HENDRICKS, C. BURN (2015): Impact of Facial Conformation on Canine Health: Corneal Ulceration. *PLoS One.* 10. DOI: 10.1371/journal.pone.0123827
81. PALAFOX-HERRERA, P., Y. ORTIZ-AVILEZ, R. RUELAS-AVILES, D. RUELAS-VOGEL, D. MOSCO-FIERRO, D. MESA-DIAZ, S. TORRES, M. RAMIREZ-AMEZCUA, D. ESQUIVEL (2023): Use of Mesenchymal Stem Cells in Corneal Ulcers in Dogs: A Case Report. *Mathews J. Vet. Sci.* 7, 20. DOI: 10.30654/MJVS.10020
82. PALMER, S., F. ESPINHEIRA GOMES, J. McART (2021): Ophthalmic disorders in a referral population of seven breeds of brachycephalic dogs: 970 cases (2008–2017). *J. Am. Vet. Med. Assoc.* 259, 1318-1324. DOI: 10.2460/javma.20.07.0388

83. PATEL, K. P., P. V. PARIKH, J. K. MAHLA, S. N. ASHWATH, D. N. KELAWALA (2020): Incidence of Corneal Ulcer in Dogs – A Retrospective Study. *Int. J. Curr. Microbiol. App. Sci.* 9, 3174-3179. DOI: <https://doi.org/10.20546/ijcmas.2020.908.361>
84. PUCKET, J., R. ALLBAUGH, A. RANKIN (2012): Treatment of dematiaceous fungal keratitis in a dog. *J. Am. Vet. Med. Assoc.* 240, 1104-1108. DOI: 10.2460/javma.240.9.1104
85. REGNIER, A. (2012): Anti-inflammatories in ophthalmology (in French). *Prat. Vet.* 47, 631-634.
86. REGNIER, A., G. CAZALOT, B. CANTALOUBE (2005): Topical treatment of non-healing corneal epithelial ulcers in dogs with aminocaproic acid. *Vet. Rec.* 157, 510-513. DOI: 10.1136/vr.157.17.510.
87. ROBIN, M-C., J-Y. DOUET (2018): Contribution of biomaterials in corneal surgery (in French). *PratiqueVet.* 53, 646-648.
88. ROUTH, B., E. McCOOL (2022): Salmonella infantis ulcerative keratitis in a dog. *Clin. Case Rep.* 10. DOI: 10.1002/ccr3.6265
89. SANCHEZ, R. F. (2014): The cornea. In: *BSAVA Manual of Canine and Feline Ophthalmology* (GOULD, D., G. J. McLELLAN, Eds.), 3rd ed., British Small Animal Veterinary Association, Gloucester, UK, pp. 200-231.
90. SANCHEZ, R. F., G. INNOCENT, J. MOULD, F. M. BILLSON (2007): Canine keratoconjunctivitis sicca: disease trends in a review of 229 cases. *J. Small Anim. Pract.* 48, 211-217. DOI: 10.1111/j.1748-5827.2006.00185.x
91. SAPIENZA, J. (2002): Corneal Diseases of Dogs and Cats. *WSAVA 2002 Congress*, 3<sup>rd</sup> -5<sup>th</sup> of October, Granada, Spain
92. SCOTT, E., R. CARTER (2014): Canine Keratomycosis in 11 Dogs: A Case Series (2000–2011). *J Am Anim Hosp Assoc.* 50, 112-118. DOI: 10.5326/JAAHA-MS-6012
93. STADES, F. C., K. GELATT (2008): Diseases and Surgery of the Canine Eyelid. In: *Essentials of Veterinary Ophthalmology* (GELATT, K., Ed.), 2nd ed., Wiley Blackwell, Ames, Iowa, USA, pp. 53-78.
94. STADES, F. C., A. VAN DER WOERDT (2013): Diseases and Surgery of the Canine Eyelid. In: *Veterinary Ophthalmology* (GELATT, K., B. GILGER, T. KERN, Eds.), 5th ed., Wiley Blackwell, Ames, Iowa, USA, pp. 832-893.
95. STARTUP, F. G. (1984): Corneal ulceration in the dog. *J. small Anim. Pract.* 25, 737-752. DOI: 10.1111/j.1748-5827.1984.tb00444.x

96. STUCKEY HUEY, J., M. CHURCH (2021): Qualitative Tear Film Deficiency (Canine). VINcyclopedia of Diseases. <https://www.vin.com/members/cms/project/defaultadv1.aspx?pid=607&id=7975199&f5=1>
97. THOMASY, S. M. (2020a): Practical Corneal Ulcer Management I: Superficial Corneal Ulcers. Pacific Veterinary Conference 2020, 18-21<sup>st</sup> of June 2020, Long Beach, California, USA
98. THOMASY, S. M. (2020b): Practical Corneal Ulcer Management II: Deep Corneal Ulcers. Pacific Veterinary Conference 2020, 18-21<sup>st</sup> of June 2020, Long Beach, California, USA
99. TOLAR, E., D. HENDRIX, B. ROHRBACH, C. PLUMMER, D. BROOKS, K. GELATT (2006): Evaluation of clinical characteristics and bacterial isolates in dogs with bacterial keratitis: 97 cases (1993–2003). *J. Am. Vet. Med Assoc.* 228, 80-85. DOI: 10.2460/javma.228.1.80
100. TSUBOTA, K. (1991): The importance of the Schirmer test with nasal stimulation. *Am. J. Ophthalmol.* 111, 106-108. DOI: 10.1016/s0002-9394(14)76908-9
101. TSVETANOVA, A., R. M. POWELL, K. A. TSVETANOV, K. M. SMITH, D. J. GOULD (2021): Melting corneal ulcers (keratomalacia) in dogs: A 5-year clinical and microbiological study (2014–2018). *Vet. Ophthalmol.* 24, 265-278. DOI: 10.1111/vop.12885
102. VAHLENKAMP, T. (2017): Canine Distemper and Other Canine Viral Infections. In: *Textbook of Veterinary Internal Medicine (ETTINGER, S., E. FELDMAN, E. CÔTE, Eds.), 8<sup>th</sup> ed., Saunders, Elsevier, St Louis, Missouri, USA, pp. 2505-2520.*
103. VERDENIUS, C., E. BROENS, I. SLENTER, S. DJAJADININGRAT-LAANEN (2023): Corneal stromal ulcerations in a referral population of dogs and cats in the Netherlands (2012–2019): Bacterial isolates and antibiotic resistance. *Vet. Ophthalmol.* 27, 7-16. DOI: 10.1111/vop.13080
104. WANG, Z., L. GUO, J. LI, J. LI, L. CUI, J. DONG, H. WANG (2022): Case Report: The First Report on *Moraxella canis* Isolation From Corneal Ulcer in a Bulldog. *Front. Vet. Sci.* 9. DOI: 10.3389/fvets.2022.934081
105. WEBB, T., P. CAMACHO-LUNA (2019): Corneal Erosion, Persistent (Canine). VINcyclopedia of diseases, <https://www.vin.com/members/cms/project/defaultadv1.aspx?pid=607&id=5541555&f5=1>

106. WESTERMEYER, H. (2013): Management of Common Ocular Injuries. World Small Animal Veterinary Association World Congress Proceedings, 6-9<sup>th</sup> of March, Auckland, New Zealand
107. WILLIAMS, D., P. BURG (2017): Tear production and intraocular pressure in canine eyes with corneal ulceration. *Open Vet. J.* 7, 117-125. DOI: 10.4314/ovj.v7i2.7
108. WU, D., S. SMITH, J. STINE, T. MICHAU, T. MILLER, S. PEDERSON, K. FREEMAN (2018): Treatment of spontaneous chronic corneal epithelial defects (SCCEDs) with diamond burr debridement vs combination diamond burr debridement and superficial grid keratotomy. *Vet. Ophthalmol.* 21, 622-631. DOI: 10.1111/vop.12556

## 8. SUMMARY

### Prevalence of different types of corneal ulcers in dogs – Retrospective study

Capucine Loire

Corneal ulcers are one of the most often encountered pathology in canine patient in everyday practice. They vary widely in terms of characteristics and etiologies. It is important for clinicians to characterize and appropriately treat this variety of corneal ulcers as they can lead to vision impairment, and even loss of the globe

This study aimed to establish descriptive statistics for 25 canine patients presented at the Clinic for Surgery, Orthopaedics and Ophthalmology of with corneal ulcerations. Specific goals are to characterize populations of dogs affected by ulcerative keratitis in Croatia, and to comprehend treatment strategies adopted against different types of ulcers.

In this retrospective analysis in all of admitted patient during this thorough ophthalmological examination with fluorescein test and STT-1 was performed. Patient data regarding were sex, age, breed, type of corneal ulcer, status of patient (primary care or referral), choice of treatment and length of treatment were collected and processed in Microsoft excel for descriptive statistics.

Dogs meeting inclusion criteria were 25, 56% of them were males and 44% of them were considered from brachycephalic breeds with French Bulldog being overrepresented. Mean age was  $7.36 \pm 3.09$  years old. The main type of ulcer encountered in this study was SCCED (44%) followed by simple superficial ulcers (24%). Mean STT-1 value was  $20.2 \pm 7.99$  mm/min. Primary causes were difficult to establish but KCS and trauma were the most often encountered. All dogs were treated with a topical antibiotic (tobramycin or ciprofloxacin). Other prescribed medications included received pain control medications, cyclosporine, artificial tears and/or proteases inhibitors. 16.7% of them received diamond burr debridement at first visit and 20.8% during control visits. Only one case of keratomalacia lead to corneal perforation.

Good outcome of treatment with proper antimicrobial and other supportive therapy based on ophthalmological examination results is important and can be expected in treating this condition.

Keywords: corneal ulcers, dogs, retrospective study, fluorescein test, Croatia

## 9. SAŽETAK

Prevalencija različitih tipova ulkusa rožnice kod pasa – Retrospektivna studija  
Capucine Loire

Čir rožnice jedno je od najčešćih oftalmoloških promjena kojima se možemo susresti u svakodnevnoj praksi. Prema uzroku nastanka te dubini zahvaćenosti ozljede postoji više oblika, Zbog razvoja mogućih komplikacija poput gubitka vida ili čak gubitka samog oka vrlo je važno prepoznati te odgovarajuće liječiti pojedine oblike ove bolesti.

Cilj ovog istraživanja bilo je utvrditi prisutnost pojedinih oblika čira rožnice te raspodjelu podataka u zahvaćenoj populaciji zaprimljenih pasa na Kliniku za Kirurgiju, ortopediju i oftalmologiju Sveučilišta u Zagrebu. Specifični ciljevi uključuju zastupljenost pojedinih pasmina pasa te ustanoviti odgovarajuću terapiju za zahvaćene pse u Republici Hrvatskoj,

U ovom retrospektivnom istraživanju svih uključenim psima učinjen je detaljan oftalmološki pregled uz test oštećenja rožnice fluoresceinskom bojom te STT-1. Podaci o životinjama poput spola, dobi, pasmini, vrsti čira rožnice, primarnoj ili referalnoj obradi, te dužini trajanja liječenja obrađene su u programu Microsoft excel.

U populaciji pasa uključenih u istraživanje 25, 56% čini su muški psi, a 44% njih bilo je brahiocefalične pasmine među kojima je najčešća pasmina bila Francuski bulldog. Prosječna dob je bila  $7.36 \pm 3.09$  godina. Najčešći tip čira rožnice u istraživanju bio je SCCED (44%) a zatim površinski čirevi (24%). Srednja vrijednost STT-1 u istraživanju iznosi  $20.2 \pm 7.99$  mm/min. Primarni uzrok bolesti teško se jasno uočava no KCS I trauma oka se najčešće susreću. Svi psi su liječeni lokalnom primjenom antibiotika (tobramicina ili ciprofloksacina). Uz navedene lijekove u liječenju su se koristili lijekovi protiv bolova, ciklosporin i umjetne suze te inhibitori proteinaza za lokalnu promjenu. 16.7% pacijenata zahtjevalo je lokalni debridman rožnice dijamantnom brusilicom pri primarnom te 20.8% na kontrolnom pregledu. Samo jedan slučaj keratomalacije doveo je do perforacije rožnice. Povoljan ishod liječenja s odgovarajućim antimikrobnim pripravcima te uz ostalu terapiju ovisno o rezultatima oftalmološkog pregleda može se očekivati u ovakvim slučajevima.

Ključne riječi: ulkusi rožnice, psi, retrospektivna studija, fluoresceinski test, Hrvatska

## 10. CURRICULUM VITAE

Capucine Loire was born in Lille, France, on the 14<sup>th</sup> of October 1996. She grew up in her birth town until five years old and then moved to Poitiers, France. After finishing a scientific high school, she obtained a Bachelor in Management, major in finance from the ISCTE Business School, Lisbon, Portugal (double diploma with KEDGE Business School, Bordeaux, France) in 2018. During her Business School education, she had the opportunity to live in France, Portugal, Spain and Germany, giving her the opportunity to learn new cultures and adaptation skills to these cultures. After which she decided to follow her childhood dream of becoming a veterinarian and integrated the Veterinary Faculty of Zagreb in the International program.

Beside studies, she was involved in the faculty life through the Vet Society - University of Zagreb where she was an active member along the six years of her studies. She took part in the renovation of the anatomy student's room. She volunteered for multiple projects of the Vet Society and co-directed some others, notably the creation of the Student Guide and its update from her second to her fifth year of study, and Day for the Paws in 2021 where she also gave a presentation about first aids in dogs and cats. She was treasurer of the Vet Society – University of Zagreb during the academic years 2020-2021 and 2021-2022.

To complete her veterinary education, she had multiple externships through her studies in small animals and mixed clinics in different parts of France (Pas-de-Calais, Vienne, Ain, Ile-et-Villaine, Finistère) and completed a total of 23 weeks where she acquired multiple practical skills and had the occasion of sharing and improving her theoretical knowledges with experienced veterinarians. She also attended the French national congress of the AFVAC in December 2023 in Lille to improve and update her knowledges on wide spectrum of veterinary subjects.