

# Detecting subclinical laminitis: histopathological study of hoof lamellae from a random population of horses (ex-vivo)

---

Prié, Valentine Jeanne Marie

Master's thesis / Diplomski rad

2024

Degree Grantor / Ustanova koja je dodijelila akademski / stručni stupanj: **University of Zagreb, Faculty of Veterinary Medicine / Sveučilište u Zagrebu, Veterinarski fakultet**

Permanent link / Trajna poveznica: <https://um.nsk.hr/um:nbn:hr:178:898982>

Rights / Prava: [In copyright](#)/[Zaštićeno autorskim pravom.](#)

Download date / Datum preuzimanja: **2024-12-30**



Repository / Repozitorij:

[Repository of Faculty of Veterinary Medicine -  
Repository of PHD, master's thesis](#)



THE UNIVERSITY OF ZAGREB  
FACULTY OF VETERINARY MEDICINE

INTEGRATED UNDERGRADUATE AND GRADUATE UNIVERSITY STUDIES IN  
*VETERINARY MEDICINE*

MASTER'S THESIS

Valentine, Jeanne, Marie PRIÉ

Detecting subclinical laminitis:  
histopathological study of hoof lamellae from a random population of horses  
(*ex-vivo*)

Zagreb, 2024

Valentine Prié

Department of Veterinary Pathology

Head of department: Assoc. Prof. Ivan-Conrado Šoštarić-Zuckermann, DVM, PhD, DECVP

Mentor: Assoc. Prof. Ivan-Conrado Šoštarić-Zuckermann, DVM, PhD, DECVP

Clinic for Surgery, Orthopaedics and Ophthalmology

Head of department: Prof. Dražen Vnuk, DVM, PhD

Mentor: Assoc. Prof. Nika Brkljača Bottegaro, DVM, PhD, DECVSMR

Members of the Committee for Defense of the Master's Thesis:

1. Assoc. Prof. Ivan-Conrado Šoštarić-Zuckermann
2. Assoc. Prof. Nika Brkljača Bottegaro
3. Assist. Prof. Lidija Medven Zagradišnik
4. Assist. Prof. Darko Grden

The paper contains 64 pages, 4 figures, 21 tables and 26 literature citations.

## ACKNOWLEDGEMENTS

I would like to dedicate this thesis to my parents, Alexandrine and Pierre-Yves, who sacrificed plenty so I could pursue those studies. From the farm to Croatia, without the shadow of a doubt, you always supported my projects, allowing me to thrive today. Ben, my dear brother: we shall keep on transforming our dreams into reality and may our journey as equine veterinarians continue successfully. I will miss seeing your silly face daily. Thanks for following and supporting me blindly on any journey.

Dr Šoštarić-Zuckermann, I am lacking words to assert my gratitude as you chose to believe this project was achievable despite the challenge. Your willingness allowed it to be concretized, it would not have been successful without your guidance. The knowledge and passion for histopathology which I gained through your support is one of the highlights of my education. Heartfelt thanks to the Pathology Department, especially Sandra who enabled the laboratory procedure to be successful, Alen for the tough labour and all employees for their kindness welcoming me.

Dr Brkljača Bottegaro, it's extremely gratifying to be today closing one of the many chapters of your project. What a relief! Your achievements specifically in this country as a female equine specialist is admirable and I believe a legacy for this faculty. My equine clinical experience would have been greatly lessened without your presence.

To our equine volunteers group, my second family: many thanks to Dr Grden, Dr Gotić and all involved clinicians. I am glad that fluid bags (or bloody Indy) could bring us together: Tonija, Tina, Laura, Marija, Klara, Anamarija, Morana, girls (sorry Thibaud ! *53 le sang*), keep on dreaming big, you earned it. I'm there for you, always. Margaux, you hate compliments but you deserve a hundred applauds for your work ethic and dedication and Jess, almost literally for maintaining me alive at times. I know we will remain friends for life and this is such a comforting thought. Dr Miljak, you are not only a strong, incredible equine vet, you are also an example of resilience and kindness. Thank you so dearly for all your investment. I wish you the best of luck in the continuation of your career !

Dr Caure, you supported me further than anyone in the profession. I would not have found my vocation this early without you. You must be ensured of my appreciation for meeting you and incredible farriers, becoming part of Equi-Junior-Locomotion. Lea: we shall keep on running, minds alike, through life together. I'm ensuring you. To the wonderful people I met along the way, I will not forget you. My trauma bonding friends; Sofia, Alyssa, Theresita, Nia, Coco, Juliette, Joséphine, Natnat, Chelsea... I am so happy our paths crossed and I couldn't dream of better people to share it with. The ones who aren't doing horses, it's not too late yet. Zoya and Will, I am so grateful our lives got tangled together in that tiny flat's carpet: to being a happy bundle forever. Anae, Nina, can't believe you've been there all this time. *Loin des yeux, près du cœur... Hrvatska: hvala ti puno, Zagreb volim te i vidimo se !*



## INDEX

<b>1. INTRODUCTION</b>	<b>1</b>
<b>2. LITERATURE REVIEW</b>	<b>4</b>
<i>2.1 Histological description of physiological lamellar tissue</i>	<i>4</i>
<i>2.1.1 The primary and secondary lamellae</i>	<i>4</i>
<i>2.1.2 The basement membrane and lamina densa</i>	<i>4</i>
<i>2.1.3 Lamellar microcirculation and epidermal cell response</i>	<i>5</i>
<i>2.2 Histopathological changes associated with laminitis</i>	<i>6</i>
<i>2.2.1 The hemodynamic phase: vascular histopathological changes</i>	<i>6</i>
<i>2.2.2 The mechanical phase: lamellar and cellular stretching, a key early lesion</i>	<i>7</i>
<i>2.2.3 The basement membrane pathology</i>	<i>9</i>
<i>2.3 Grading system for evaluating laminitis based on histopathology</i>	<i>9</i>
<b>3. MATERIALS AND METHODS</b>	<b>11</b>
<i>3.1 Gross pathology protocol: specimen collection and dissection</i>	<i>11</i>
<i>3.2 Laboratory processing: specifics of hoof tissue</i>	<i>13</i>
<i>3.2.1 Keratin softening and cutting procedures</i>	<i>13</i>
<i>3.2.2 Slides preparation</i>	<i>15</i>
<i>3.3 Adapted grading system</i>	<i>16</i>
<b>4. RESULTS</b>	<b>19</b>
<i>4.1 Individual results: microscopic findings for each evaluated parameter</i>	<i>19</i>
<i>4.2 General results: individual and average grading per sample</i>	<i>53</i>
<b>5. DISCUSSION</b>	<b>55</b>
<b>6. CONCLUSIONS</b>	<b>58</b>
<b>7. REFERENCES</b>	<b>59</b>
<b>8. SAŽETAK</b>	<b>62</b>
<b>9. ABSTRACT</b>	<b>63</b>
<b>10. BIOGRAPHY</b>	<b>64</b>

## 1. INTRODUCTION

Fossil evidence suggests ancient horses dealt with laminitis dating back over 1.8 million years ago. It may have been first mentioned by the ancient Greek historian and philosopher Xenophon, who wrote about a disease called “barley surfeit (excess)” and said: “Diseases are easier to cure at the start than after they have become chronic and have been wrongly diagnosed.” (WALLET, 2013). Those two statements are still indubitable in the present day, laminitis being one of the most important debilitating conditions affecting equids worldwide. In the UK, 1 in 10 horses or ponies may develop at least one laminitis episode each year, making it just as common as colic, with 15% of deaths in direct correlation (POLLARD et al., 2018). The acute phase of laminitis is rarely self-limiting and frequently ends in euthanasia or becomes a chronic condition with complicated recovery and poor return to performance (ORSINI et al., 2010). Therefore, prevention and early detection allowing for treatment before clinical presentation of the syndrome are primordial.

The disease is characterised by the inflammation of the lamellar tissue in the hoof. The lamellar basal epithelial cells (LBEC) participate in suspending the distal phalanx (DP) from the *stratum internum* of the hoof capsule. The LBECs can weaken and stretch all together with the secondary epidermal lamellae (SEL) or detach from their underlying basement membrane (BM), producing the same net result: the DP pathologically descends towards the solear dermis (POLLITT, 2007). The deep digital flexor tendon (DDFT) action will further emphasise the DP rotation inside the hoof capsule and grave cases can end with bone perforating the solear surface.

Rather than a discrete entity, laminitis is now considered to be a clinical syndrome associated with systemic disease and is classified based on the division between the endocrine disease model, the sepsis or systemic inflammatory response syndrome (SIRS) model or altered weight bearing such as supporting limb laminitis (PATTERSON-KANE et al., 2018). Consequently, clinical signs associated with laminitis vary but include characteristic lameness with shorter stride, weight shifting to the hind limbs leading to the typical laminitic stance and reluctance to move. Deformation of the hoof capsule and more specifically convex or dropped solear surface with widened white line appear with chronicity. Severely affected horses present with considerable pain, increased vitals and complete recumbency before death (ORSINI et al., 2010).

Diagnosis of laminitis by the equine practitioner usually results from correlation between clinical signs and imaging findings, primarily through radiology or when available, advanced diagnostic methods such as Magnetic Resonance Imaging (MRI) and Computed Tomography (CT). However, those methods can be limiting: macroscopic remodelling of the hoof capsule can be restricted to subtle gross changes and clinical signs scarce or unspecific such as decreased performance, increased digital pulse or mild to absent hoof test sensitivity. Furthermore, absence of clinically relevant radiographic alterations is common in the early stage, making subclinical laminitis difficult to assert with certainty through traditional methods. In consequence, the syndrome is regularly not suspected in subclinical cases and early misdiagnosis is common (LITTLE and SCHRAMME, 2007).

In the early pathophysiology of laminitis, the first key event is stretching and elongation of the lamellar cells (PATTERSON-KANE et al., 2018). Therefore, the gold standard for laminitis diagnosis is the microscopic histological analysis of lamellar tissue. While well described, this method is performed in great majority for experimental purposes after death of the animal and not used by field veterinarians. This can be explained by the knowledge and material necessary to perform the biopsy, the invasive character of lamellae sample extraction and the aftermath implication of such procedure: pain, recovery period and potential for further complications such as infections or hoof capsule deformation. However, several studies in recent years demonstrated the advantage of using biopsies in live horses and aimed at standardising the technique. For instance, the use of a specifically designed instrument called a Falcão-Faleiros lamellotome allowed for collection of histologic samples of adequate quality with no complications reported (RIBEIRO et al., 2016).

Not only can laminitis diagnosis in the early stage be difficult with traditional radiology, but this subclinical phase can be prolonged, in some horses for months. It is evidenced by development of divergent hoof rings, way prior to lameness onset. Chronically developing endocrino-pathic lesions were found to have a preclinical stage: these hoof rings may signify a window of opportunity for therapeutic intervention (KARIKOSKI et al., 2015). The use of biopsy techniques for histological analysis of lamellar tissue will likely continue to increase in the future years, allowing for more prompt diagnosis during that period. Whether through the use of therapeutic podiatry or medically, there is a variety of treatment options available for laminitis. In all cases, the earliest diagnosis and treatment is, the better the prognosis, with increased chances of successful recovery and quality of life improvement.

The great majority of histopathological studies on laminitis were based on samples obtained from horses in which the pathology was experimentally induced and euthanasia performed for this research purpose (POLLITT and MILINOVICH, 2017). Histopathology as a diagnostic tool for laminitis in horses without known laminitis history or without clinical signs has rarely been performed (KAWASAKO et al., 2009; HAMPSON et al., 2012).

The aim of this present study was to describe the histological findings in lamellar tissue obtained post-mortem from randomly selected horses showing no clinical manifestation of laminitis. The specimens were obtained from slaughtered horses, clinically examined by a veterinarian and declared healthy.

The hypothesis is that a minority of the evaluated hooves samples could present histopathological changes conclusive of laminitis. If such changes would be observed, it could emphasise the benefit of biopsy use followed by histological evaluation for early-stage diagnosis in live horses suspected to have subclinical laminitis.

The specific goals were:

- To establish a protocol of the procedure from hoof dissection to obtention of histopathological slide, for educational purposes by the Department of the Pathology, Veterinary Faculty, University of Zagreb.
- To microscopically evaluate the obtained specimens and describe pathological findings.
- In the event of detecting laminitis markers, to evaluate the histological changes according to a histological grading system for laminitis.

## 2. LITERATURE REVIEW

### 2.1 Histological description of physiological lamellar tissue

#### 2.1.1 The primary and secondary lamellae

Anatomy and normal physiology of the equine inner hoof and lamellae has been initially studied and described by POLLITT (2007a and 2007b) and is presented in the following three sub-sections. The surface area of the equine inner hoof wall has been calculated to average 0.8 m<sup>2</sup>, which is considerably more than the inner surface area of bovine hooves, which lack secondary lamellae. This large surface area for suspension of the distal phalanx and the great compliance of the interdigitating lamellar architecture helps reduce stress and ensures even energy transfer during peak loading of the equine foot. In life, the hoof distal phalangeal attachment apparatus is impressively strong.

The primary epidermal lamellae (PELs) in a physiological number of 550 to 600 project in parallel rows from the inner surface of the hoof wall and bars. They are supported by the presence of 150 to 200 secondary epidermal lamellae (SELs) on the surface of each PEL forming the *stratum lamellatum*. The lamellae of the dorsal hoof wall present a long, thin rectangular shape approximately 7 mm wide and 50 mm long. One long edge of the rectangle is incorporated into the tough, heavily keratinized hoof wall proper (*stratum medium*) and the other long edge is free, facing the outer surface of the distal phalanx. The proximal short edge is curved and forms the inner shoulder of the coronary groove. The distal short edge merges with the sole and becomes part of the white zone visible at the ground surface of the hoof.

The SEL tips are rounded (club-shaped). The basal cell nuclei are oval in shape and positioned away from the basement membrane (BM) at the apex of each cell. The long axis of each basal cell nucleus is at right angles to the long axis of the SEL. The secondary dermal lamellae are filled with connective tissue even at their very tips, between the SEL bases. The tips of the lamellae (both primary and secondary) all orient toward the distal phalanx, thus indicating the lines of tension to which the lamellar suspensory apparatus is subjected.

#### 2.1.2 The basement membrane and *lamina densa*

At the interface of the epidermis and the dermis is a tough, unbroken sheet of extracellular matrix called the basement membrane (BM). This key structure partitions lamellar

epidermal cells from the lamellar dermis. On one side of the BM, epidermal basal cells are firmly attached; on the other (dermal) side, tendon-like connective tissue, emanating from the dorsal surface of the distal phalanx, is tightly woven into the mat-like structure of the BM.

Specific staining such as Periodic Acid-Schiff (PAS) is required to highlight the basement membrane (BM) and locate the glycoprotein constituents of the basement membrane, for example laminin. Applied to normal hoof lamellae, the BM of each SEL stains as a dark magenta line closely adherent to the SEL basal cells. Between the bases of each SEL, the BM penetrates deeply and is close to the anuclear, keratinized PEL. The BM of normal lamellae penetrates deeply into the crypt between pairs of SELs and clearly outlines the tapered tip of each secondary dermal lamella (SDL). The proximity of the SDL tip to the keratinized axis of the PEL is always a distance equivalent to the length of one or two epidermal basal cells.

The ultrastructure of the equine hoof basement membrane is a sheet-like three-dimensional anastomosing latticework of fine interconnecting cords. The axial skeleton of the cord network consists of filaments of collagen IV. The collagen IV filaments are ensheathed with glycoproteins, in particular laminin-1, which together form the electron-dense *lamina densa* which appears as a dark line following the contours of the epidermal basal cells. The plasma membrane (*plasmalemma*) at the base of each basal cell is attached to the BM by numerous electron-dense adhesion plaques, or hemidesmosomes (HDs). The various proteins of each HD occur on both sides of the basal cell *plasmalemma*, thus forming a bridge linking the interior of the basal cell to the exterior connective tissue. Innumerable extensions of the *lamina densa* and banded anchoring fibrils (consisting of collagen VII) in the shape of recurved hooks intermesh with the type I collagen fibrils of the connective tissue of the lamellar corium, forming an important part of the attachment mechanism between dermis and epidermis. The equine lamellar basement membrane has a high density of *lamina densa* extensions and anchoring fibrils around the tips of the secondary epidermal lamellae.

The electron-dense *lamina densa* is only visualised with a Transmission Electron Microscope (TEM) and isn't a visibility evaluable structure in routine diagnosis operation.

### 2.1.3 Lamellar microcirculation and epidermal cell response

The lamellar epidermis (PELs and SELs) is strictly avascular. Therefore, the delivery of glucose and water exchange required to maintain attachment at the lamellar dermal/epidermal interface relies exclusively on the capillaries of the adjacent secondary

dermal lamellae (SDLs). The capillaries are present extremely close to the target of energy delivery, the basal cells of the secondary epidermal lamellae (SELs). In a physiological setting there are no dermal inflammatory cells such as polymorphonuclear leukocytes (PMNs) present in either the capillaries or any part of the lamellar corium.

## 2.2 Histopathological changes associated with laminitis

During peak loading, the hoof wall and the distal phalanx move in concert and separate only when laminitis interferes with lamellar anatomy. The signature lesion of laminitis, failure of attachment between lamellar dermis and epidermis, occurs at this lamellar dermo-epidermal junction and involves the lamellar BM. The temporal correlation of histopathological changes occurring in laminitis has been the subject of research for decades. Different paradigms have been accepted, commented on and modified through time (POLLITT, 2007b).

### 2.2.1 The hemodynamic phase: vascular histopathological changes

The first event of the developmental phase of laminitis is the vasospastic ischemia of the fragile lamellar capillaries, following decreased blood flow to the hoof which is compatible with any etiological cause of the syndrome (HOOD et al., 1993).

Ischemia initiates a complex cascade of events that result in loss of tissue function. Included as a primary event in this cascade is necrosis due to anoxia. The second component of the ischemic cascade is the occurrence of reperfusion injury that occurs following systemic response and reactive hyperaemia. Most of this injury is attributed to peroxidation of cellular and intracellular lipids secondary to the production of superoxide radicals. In addition to the damage attributable to anoxia and that caused by reperfusion injury, alterations occur in the ability of cellular and noncellular elements of the blood to flow through the microcirculation (hemorheological dysfunctions). Coagulopathies, activation of leukocytes, and loss of vascular endothelium all occur frequently in post ischemic laminitis.

Before development of the vascular phase, the very first histopathological sign consisting of endothelial cells swelling and limited adjacent oedema appeared one study 4h after the onset, making hemodynamic change first before any other non-vascular histological alteration (HOOD et al., 1993). This is concordant with the fact that clinically, warmth of the hoof and increased digital pulse are always the first noticeable signs as markers of the acute phase, before further symptomatic development. Thus, the angiopathy process precedes the

mechanical distortion of the epidermal-dermal tissues and the physiological cell response. However, the more visible vascular changes such as the erythrocytic congestion and obstruction of the capillaries, microvascular thrombi appearance and severe oedema as well as the primary dermal lamellae haemorrhage and inflammatory cells infiltrate appear in that chronological order during the 72h hours post onset. Laminitis in the prodromal phase is associated with inflammatory response with appearance and elevation in inflammatory mediators, like TNF-  $\alpha$ , cytokines, and reactive oxygen species (LOFTUS et al., 2008).

Therefore, overlapping of those changes with more detectable changes related to the other processes occurs and hemodynamic study, while potentially detectable in the very early processes, cannot be solely applied as a reliable source for histopathological diagnosis.

### 2.2.2 The mechanical phase: lamellar and cellular stretching as a key early lesion

As a paradigm shift, stretching is now regarded as a key early (and potentially primary) structural event, and was the earliest noticeable histological change at the 6 h time point in Standardbred horses with induced hyperinsulinemia (DE LAAT et al., 2012). Beyond their anatomical position, the function of the plethora of lamellar capillaries is expressed through their constant supply of vital energy that maintains the integrity of the lamellar interface, specifically glucose. It can be hypothesised that the bridge between vascular and mechanical lamellar stretching also results from the ambiguous connection between blood, thus glucose supply, and normal cellular function in those highly dependent tissues.

Documented early histological changes in all laminitis models (mechanical overload, endocrinopathic and SIRS-associated) (ELLIOTT et al., 2013) have included loss of the perpendicular orientation of SEL nuclei relative to their basement membranes, nuclear rounding, a more centrally located nucleus within the cytoplasm compared to its physiological apical position, with a more random orientation and prominent nucleoli. Normal SELs have a constant histologic appearance that only laminitis alters. They were observed to lengthen, narrow, deformation of the club-shaped into tapered tips and to become more acutely angled to the PEL axis, which keratinized axis becomes elongated and distorted, with irregularity of the PEL/SEL interface. The club-shaped tips of the SELs, as outlined by the BM, have always been found to be rounded and never tapered or pointed. The PEL and SEL become closely apposed and frequently became difficult to distinguish from one another as the condition progresses (POLLITT, 1996; ASPLIN et al., 2010; DE LAAT et al. 2012). SEL elongation



(lamellar and cellular) was thought to occur partly due to epidermal cells sliding past each other (POLLITT, 2004) or because of increased proliferative activity provoked by insulin, sometimes in the absence of significant lamellar disruption (DE LAAT et al., 2012; KARIKOSKI et al., 2014).

This cellular stretching is accompanied and followed by evidence of an accelerated cell death proliferation cycle with lamellar epithelial cell proliferation, although the spatio-temporal relationships of these processes (cell death, proliferation and stretching) remain obscure and vary between models/studies. Apoptotic cells are a rarity in normal lamellar tissue and their enrichment may be secondary to mechanical stress caused by lamellar epithelial cell stretching (ASPLIN et al., 2010; KARIKOSKI et al., 2014).

The histopathology of naturally occurring endocrinopathic laminitis was described (KARIKOSKI et al., 2015) with microscopic lesions largely localised abaxially (close to the hoof wall) and included apoptosis, lamellar fusion, hyperplasia and partial replacement with aberrant keratin containing nucleated debris and proteinaceous lakes. The abaxial location of continuing apoptosis correlated well with the axial-to-abaxial ‘wave’ of cell death hypothesised from the developmental phases of experimental models. These abaxial lesions were associated with irregular margins between the stratum medium and the lamellar tissue, and may indicate the following sequential events:

- (1) fusion of SEL tips across the supporting dermal tissue, isolating rounded areas of vascular dermal tissue;
- (2) continued centrifugal keratinisation with production of increasing amounts of cap horn; degeneration of blood vessel(s);
- (3) infill with keratin or proteinaceous fluid.

In chronic endocrinopathic laminitis, lamellar disruption was always abaxial and variably involved BM separation, tearing of SEL and/or separation of the PEL by ripping through the SEL bases. In acute induction models associated with SIRS, tearing was mostly axial and exclusively involved BM separation (POLLITT, 1996; DE LAAT et al., 2012).

While the specific model of aetiology causing the syndrome has an incidence on the histopathological observable changes, it's rather through a quantifying impact than a complete absence or presence of changes, making all those parameters evaluable in any case of laminitis.

### 2.2.3 The basement membrane pathology

Prior to the development of knowledge over the aetiologies of laminitis and the refining of the hyperinsulinemic model, the primary lesion of laminitis, and research focus, was generally accepted to be BM injury (POLLITT, 1996; EADES, 2010). However, BM damage was not found in all carbohydrate overload models, with one research noting that it remained intact and attached during the acute phase (MORGAN et al., 2003).

In most hyperinsulinemia models, BM damage is minimal and predominantly localised to the most axial SEL only; neither all SEL, nor all specimens were affected. Even when BM separation was absent, there were reduced numbers of hemi-desmosomes per unit length of BM. Matrix metalloproteinases (MMPs) are often proposed to be the agents of BM breakdown, although we lack direct evidence for their activities (ASPLIN et al., 2010; DE LAAT et al., 2012), it undoubtedly plays a variable role in the cascade of lesions following disease initiation. Therefore, a primary role of BM pathology is debatable for both endocrinopathic and SIRS-associated laminitis. The specific staining necessary to properly evaluate the BM can be a complicating factor in the process of making histological slides, thus while not completely circumvented, the evaluation of this parameter was lowered in the present study.

### 2.3 Grading system for evaluating laminitis based on histopathology

The description of hoof lamellar anatomy forms the basis of the histologic grading system of laminitis, an evaluation system created in order to generalise the use of a standardised system. Results are therefore easier to read and for the practitioner to correlate or not the pathological findings firstly with a diagnosis of laminitis and secondly to determine a prognosis based on the severity, which further influences the treatment plan. The first official grading system was determined by C.Pollitt (8) in 1996 and, due to the proposed paradigm on key lesions at the time, based principally on changes to lamellar basement membrane (BM). Lesions of the epidermal lamellae, attributable to laminitis, were graded in order of increasing severity from Grade N (normal), Grade 1 (mild), Grade 2 (moderate) to Grade 3 (severe and extensive). It was further described as follows:

- In early Grade 1 lesions, the tips of the SELs where the BM had lifted formed teat-shaped bubbles. Earliest changes were rounding of the basal cell nuclei and elongation of secondary epidermal lamellae. SELs tips were pointed instead of round and the basement membrane had separated from the lamellae.
- In Grade 2 lesions, the absence of BM at the tips of secondary dermal lamellae, along with varying amounts of connective tissue, was considered a progression in severity.
- Grade 3 lesion: eventually, even the primary epidermal and primary dermal lamellae separated from each other and the empty shells of isolated BM, in what was once the tip of the primary epidermal lamella, signified that a global separation of the epidermal and dermal lamellae had occurred (POLLITT, 1996).

The two studies published with the aim of detecting and describing histopathology of lamellae obtained from horses respectively without history data (HAMPSON et al., 2012) and without clinical signs of laminitis (KAWASAKO et al., 2009) did not use a specific grading system for assessment of the laminitis. They described structural pathology criteria, with the most prevalent features being presence of excessive horn at the distal lamellae end as well as multi-branched and attenuated SEL and morphology of the PEL.

### 3. MATERIAL AND METHODS

#### 3.1 Gross pathology protocol: specimen collection and dissection

This research was approved by the ethical committee of the Veterinary Faculty, University of Zagreb, by decision 640-01/24-17/06, study number 251-61-32-24-01. The specimens used were collected during a 7 days period from the 20th January to the 27th January 2024 at the registered slaughterhouse “Klaonica 32 d.o.o” (10408 Velika Mlaka, OIB: 29309628580). All front limbs of horses slaughtered in the location of Zagreb county during that time frame were selected provided that they met the research requirements. Inclusions criteria were to retrieve the front legs of horses which had been declared clinically exempt of diseases and issued a valid health certificate, following the clinical examination performed by the official sanitary veterinarian of the slaughterhouse.

The exclusion criteria were a prior or current diagnosis of laminitis or any active disease process. No discrimination based on sex, age, breed or previous use was performed.



Figure 1. Posavac stallion in Sisak region, example of horse breed used for the study. Damjan Džakula

Before dissection, pictures of the hooves were taken for macroscopical examination and gross inspection. The selected distal front limbs were collected after section at the intermediate carpal joint within 1h following death. Fresh specimens were stored refrigerated at +4° and processed within 72h. At the necropsy hall, Department of Pathology, the distal

limbs were cleaned and carefully secured on a bench vice used for dissection purposes with both jaws tightly grasping the fetlock joint. Protected with metallic gloves, the operator manipulated the hack saw in order to perform parallel cuts extending from the coronary band through the palmar solear surface of the hoof, on a strictly sagittal plane at the dorsal aspect of the hoof. Following that, two parasagittal cuts were made and spaced parallel to the central most sagittal cut with a 3mm thickness. For each hoof, this resulted in retrieval of two triangular shaped sections of 3mm width and 3-5cm maximum length, each of the dorsal and palmar hoof wall with the extremity of P3 and all intermediate tissues including lamellar corium present.

The tissue sections were then rinsed with clear water and individually fixated with enough of 10% formalin to cover the totality of the sample surface, in a clean labelled container. The container was then stored at room temperature for at least 24h hours until further processing at the laboratory of the Department of Pathology.



Figure 2. Gross dissection by sagittal cut of the dorsal aspect of the hoof to the mid P3 bone depth. Operators should wear security gloves while manipulating the hacksaw. Author picture

### 3.2 Laboratory processing: specifics of hoof tissue

#### 3.2.1 Keratin softening and cutting procedures

Softening of the keratin layer to enable further resection of the sample as to fit the cassette was a necessary step. Several experimental methods present here were tested to find the most appropriate one. The entire sample (triangular shaped hoof section of generally max length 4/5cm) was covered with a softening agent during a specific amount of time.

Table 1. Tested products for softening of the keratin hoof layer and results.

Softener tested	Ability to adequately cover the sample	Length of time until correct softening	Practicality and use	On histological evaluation
10% Potassium hydroxide (KOH)	Liquid form – optimal	7h	Care while manipulating	No tissue alteration visible
10% Sodium hydroxide (NaOH)	Liquid form – optimal	7h	Care while manipulating	Similar as NaOH (no visible difference)
Fabric detergent (Ornel laundry softener)	Liquid form - optimal	Unreliable 5 – 8 days	If no time constraint	Samples broke during microtomy (not soft enough)
Wheet epilation cream	Sub-optimal – (consistency)	+ 14 days	Unpractical	Unexploitable samples

Due to the results, Potassium Hydroxide (KOH) was further used in the experiment. A 10% concentration was prepared by mixing 100g of pure KOH crystals in 1L of distilled water. Each sample was then completely covered by the solution for a period of 7 hours at room temperature. It was then possible to test the softening advancement by trying to pierce the keratin at its level of higher thickness with a small needle. If it is impossible or difficult for the needle to pierce completely through the keratin, the softening time should be extended and the extra time recorded (3 hours more for a total of 10h softening in KOH for the hardest samples).

Extra care should be taken to follow the drying process as curling up of the sample edges past 7h was witnessed and is a challenge for further cutting before cassetting.

Once the keratin layer was sufficiently soft, samples were rinsed one more time in distilled water before being completely soaked in an Anna Morse decalcification solution of 50% formic acid and 20% sodium citrate for 48h. Similarly, it should then be possible to pierce with a needle or cut through the P3 bone without effort. As with softening, time in the decalcification solution can also be extended for 24h if needed. Once softened and decalcified, the triangular shaped samples of the hoof section should be cut to correctly fit in the cassette before histological processing. A sharp blade strongly fixed on a scalpel handle was used with caution.

After trial of several cutting techniques for section of the sample before cassetting, two were selected. Both produced slides of the adequate quality for evaluation, the criteria being to have at least 2 visible PEL of sufficient quality (no more than a limited keratin to PEL tips separation, no complete disruption of the PEL-SEL interface, quality sufficient to see individual nucleus at magnification 200X).

With the first technique, both keratinized dorsal hoof wall and palmar solar surface were resected to leave a 1 mm thick parallel layer to the laminar corium. At the opposing side of P3 apex, the bone surface was cut as much as needed for the sample to fit in the cassette while leaving a minimal bone structure of at least 4mm length. This results in a sample of similar triangular shape while smaller in size (maximum 25mm in length) compared to the original.

With the second technique, the original triangular shape hoof section was sectioned transversely with a single cut at the point where P3 was the widest, from the dorsal hoof wall to the middle of P3 length. This provided a sample of squared shape which was laid at the bottom of the cassette on the side where the dorsal lamellae were visibly arranged. This technique does not allow visualisation of the solar lamellae, however, consistency of the dorsal lamellar layer's morphology is usually improved and the method should be preferred for further use. Once adequate, the sample was positioned with the flatter surface facing the bottom of the labelled cassette and stored in formaldehyde until paraffin block embedding.






Figure 3. Left: sample cut following the first technique. Right: preferred method of sampling. Author picture

### 3. 2.2 Slides preparation

The rest of the embedding procedure and microtomy, once the sample is appropriately softened, follows the standard procedure. When the block is ready for microtomy to obtain a section of 2 micrometre thickness. This step constituted a control checkpoint as the majority of the failure rate occurs at this step: if the keratin isn't sufficiently softened or the bone too hard, the specimen would break during microtomy.

The second failure point leading to suboptimal slide quality was determined to be due to the artefacts created when the edges of the specimen are “bending” and thus not properly adhering to the slide on a straight plane. This can be prevented by having the straightest sectional plane possible while cutting and a good orientation of the block to the microtome. However, the composition of the hoof section, specifically the dry hydrophobic quality of the keratin makes this bias particularly difficult to avoid. Therefore, an extra step was added after microtomy and before definitely fixed the tissue slide on the glass slide. A glue-like material was prepared by the laboratory technician by mixing gelatine with xylol in a 50:50



concentration and added to the sample on the slide before staining process. This allowed the edges to remain glued to the slide surface without bending or tissue duplication.

Standard haematoxylin and eosin staining procedure was then performed for all slides. Periodic acid-Schiff staining allowing for better basement membrane visualization was performed only some samples due to difficulty in the staining process.

The tissues once fixated on the slides with cover top were examined with a brightfield microscope under different magnification. The microscope is equipped with a camera connected to a computer interface allowing for capturing and saving microphotographs. The microscopic samples were photographed with Digicyte BigEye camera using Digicyte Capture v2.23 software. Examination and evaluation of the samples were performed by consensus of the two operators (Prof. Šoštarić-Zuckermann DVM PhD DECVP and Valentine Prie).

### 3.3 Adapted grading system

This study did not focus specifically on one etiological model of laminitis, contrary to most published experiments. Therefore, it was decided to retrieve all criteria used for histopathological evaluation in previous research. The review of (ELLIOTT and BAILEY, 2023) lists the histological results of 26 laminitis research projects on any of the 3 accepted models of laminitis. Out of a total of seven described histopathological parameters, 5 were selected for our study. The PEL morphology and the SEL contour, both being structural pathology criteria, were excluded.

The grading of severity chosen corresponds to a version of the system created by (POLLITT, 1996) and presented with modifications by (ENGILES et al., 2015). A grade 0 representing no abnormal finding, 1 a mild pathological change, 2 a moderate change and 3 severe change is.

The first evaluated criterion was the presence of an abnormality in the thickness (hyperplasia) or the arrangement (dysplasia) of the SEL supra-basal cells layer, also called Secondary Epidermal Lamellae suprabasilar hyperplasia or dysplasia (SEL sup.).

The evaluation was as follows: no hyperplasia of the SEL supra-basal layer is graded as 0, the presence of 1-2 extra cell layers is graded as a mild change (1), 3-5 extra cell layers with visible intercellular bridges is graded as a moderate severity change (2) and more than 5 extra cell layers with prominent intercellular bridges and hyperkeratosis qualifies as a grade of severity 3 (severe) (ENGILES et al.2015).

The second evaluated criterion was the integrity of the basement membrane (BM) surrounding the SEL. A physiological, intact basement membrane was graded (0) normal, presence of thickening or duplication of the membranes was graded (1), a partial separation (2) and complete separation would have been a severe change graded (3) however no samples presented such change in the present study (POLLITT, 1996; ASPLIN et al., 2010; DELAAT et al., 2012; KARIKOSKI et al., 2014; ELLIOTT and BAILEY, 2023).

The third evaluated criterion was the pathological presence of cellular infiltration (Cells.). The grade 0 corresponds to the absence of dermal inflammatory cells infiltrate either in lamellae or corium such as in a physiological state. A grading of (1) indicates the presence of rare LC (lymphocytes) presence with the absence of PLC (platelets leukocytes). A grade (2) indicates both LC presence with few PLC presence and severity of (3) correlates with visible presence of both LC and PLC with neutrophils which was not identified (POLLITT, 1996; ASPLIN et al., 2010; DELAAT et al., 2012; KARIKOSKI et al., 2014; ELLIOTT and BAILEY, 2023).

The fourth evaluated criterion was the dysplasia or inflammation of the lamellar blood vessels (vasc.) which should be located in the dermal tissue of the lamellae only. The grade (0) corresponds to the absence of vascular pathology, (1) indicates compression or displacement of SDL capillaries, the grade (2) further characterised loss of SDL capillaries with haemorrhage and (3) severe vascular damage with PDL thromboemboli, vascular necrosis or haemorrhage which was not detected on any sample of this study (ENGILES et al., 2015).

The last criterion was the presence of an epidermal cell response corresponding to degenerative changes of the basal epidermal cells in the SEL (ECR). A grade (0) indicated an absence of epidermal cells' response, grade (1) corresponds to the appearance of nuclei of epidermal basal cells which are rounded and more centrally orientated, grade (2) basal cell nuclei pyknotic with cellular vacuolation at SEL tip with visible mitoses and grade (3) indicates generalised changes visible on more than 5 SEL (POLLITT, 1996; ASPLIN et al., 2010; DELAAT et al., 2012; KARIKOSKI et al., 2014; ELLIOTT and BAILEY, 2023).

Table 2. Grading system adapted for the present study.

<b>Histopathological parameter</b>	<b>Detailed severity index for each grading</b> (0 : normal, 1 : mild, 2 : moderate, 3 : severe)
Secondary Epidermal Lamellae suprabasilar hyperplasia or dysplasia (SEL sup.)	0) none, 1) 1-2 extra cells, 2) 3-5 extra cell layers with visible intercellular bridges 3) >5 extra cell layers with prominent intercellular bridges and hyperkeratosis
Basement Membrane pathology (BM)	0) normal, 1) thickening duplication, 2) partial separation, 3) complete separation
Epidermal Cell Response (ECR)	0) normal 1) nuclei of epidermal basal cells are rounded and more centrally orientated 2) basal cell nuclei pyknotic with cellular vacuolation at SEL tip with visible mitoses 3) generalised changes (more than 5 SEL)
Cells infiltration in lamellae or corium (Cells)	0) none 1) rare LC presence and no PLC 2) LC with few PLC presence 3) LC and PLC presence with neutrophils
Vascularisation (Vasc.)	0) no vascular pathology, 1) compression or displacement of SDL capillaries, 2) loss of SDL capillaries with haemorrhage, 3) PDL thromboemboli, vascular necrosis or haemorrhage

## 4. RESULTS

### 4.1 Individual results per evaluated parameter and sample

The initial sample size was 35 front limbs obtained from 24 different horses. The average age at slaughter was 7 years old (standard deviation: 25.5), with 23% of horses between 1 and 4 years old, 63% between 5 and 9 years old and 14% being 10 years of age or older. The population was composed of light to heavy cold-blooded horses of Hrvatski Hladnokrvnjak (51%) and Posavac (49%) breeds. No data over sex was obtained. At the end of the study, 31 of the 35 initial hoof samples were successfully processed. The quality of histological tissue was unsatisfactory for 4 microscopic slides of 4 front legs retrieved from 3 different horses and those were excluded from these results.

Table 3. Samples included in the study, only front legs were used (L= left, R=right)

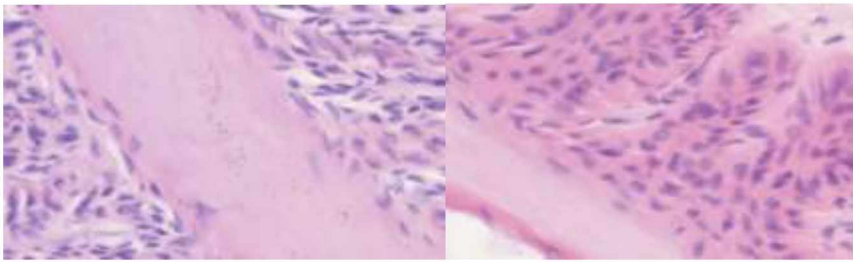
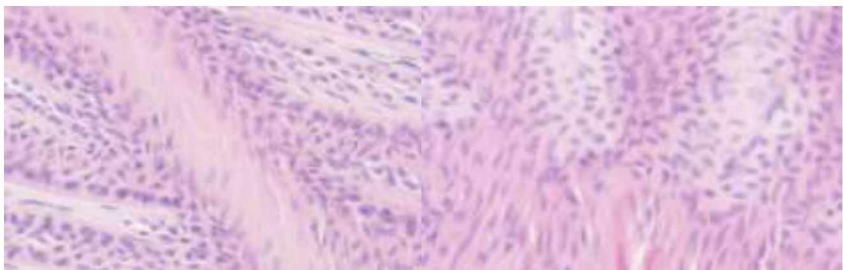
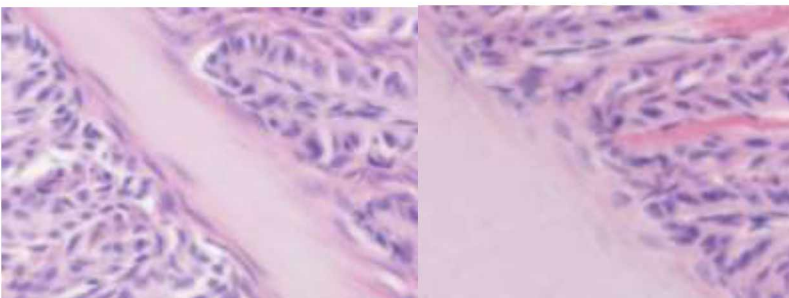
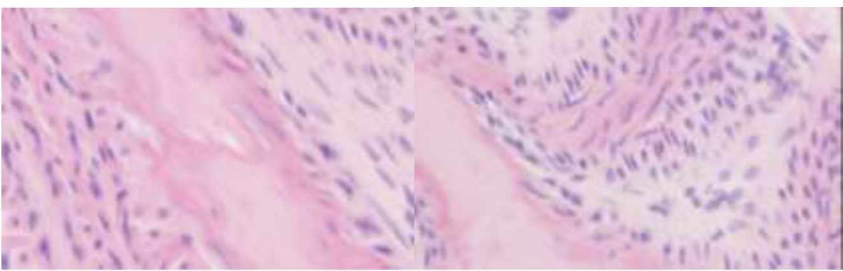
Sample identification with date of collection	Breed	Age
20/01 1-L	Posavac	5-9yo
20/01 1-R	Posavac	5-9yo
20/01 2-L	Posavac	5-9yo
20/01 2-R	Posavac	5-9yo
20/01 3-L	Hrvatski Hladnokrvnjak	<5yo
20/01 3-R	Hrvatski Hladnokrvnjak	<5yo
20/01 4-L	Posavac	5-9yo
20/01 4-R	Posavac	5-9yo
20/01 5-L	Posavac	5-9yo
20/01 5-R	Posavac	5-9yo
20/01 6-L	Posavac	>10yo
20/01 6-R	Posavac	>10yo
20/01 7-L	Posavac	<5yo
20/01 7-R	Posavac	<5yo
20/01 8-L	Posavac	<5yo
20/01 8-R	Posavac	<5yo
27/01 9-R	Hrvatski Hladnokrvnjak	5-9yo
27/01 10-L	Hrvatski Hladnokrvnjak	5-9yo
27/01 10-R	Hrvatski Hladnokrvnjak	5-9yo
27/01 11-L	Hrvatski Hladnokrvnjak	5-9yo
27/01 11-R	Hrvatski Hladnokrvnjak	5-9yo
27/01 12-L	Hrvatski Hladnokrvnjak	>10yo
27/01 12-R	Hrvatski Hladnokrvnjak	>10yo
27/01 13-L	Hrvatski Hladnokrvnjak	5-9yo
27/01 13-R	Hrvatski Hladnokrvnjak	5-9yo
27/01 14-L	Hrvatski Hladnokrvnjak	5-9yo
27/01 14-R	Hrvatski Hladnokrvnjak	5-9yo
27/01 15-L	Hrvatski Hladnokrvnjak	<5yo
27/01 15-R	Hrvatski Hladnokrvnjak	<5yo
27/01 16-L	Posavac	5-9yo
27/01 17-R	Hrvatski Hladnokrvnjak	>10yo
27/01 18-L	Hrvatski Hladnokrvnjak	5-9yo
27/01 19-L	Posavac	5-9yo
27/01 20-L	Hrvatski Hladnokrvnjak	5-9yo
27/01 21-R	Posavac	5-9yo

Results are presented in the form of tables. Each attributed grade mentioned above the table is supported with microscopical images (on the right) of the characteristics related to the

evaluated parameter (sample identification number on the left) and taken with a brightfield microscope at total magnifications 40x, 10x, 200x or 400x.

Table 4. Parameter “Secondary Epidermal Lamellae supra-basal cells”, samples of grade (0):

Those samples correspond to biopsies of the dorsal hoof wall of the horses with their identification number presented on the left. In this table are presented slides with no findings of hyperplasia or dysplasia of SEL supra-basal cells (grade 0).

2-L	
2-R	
3-L	
3-R	

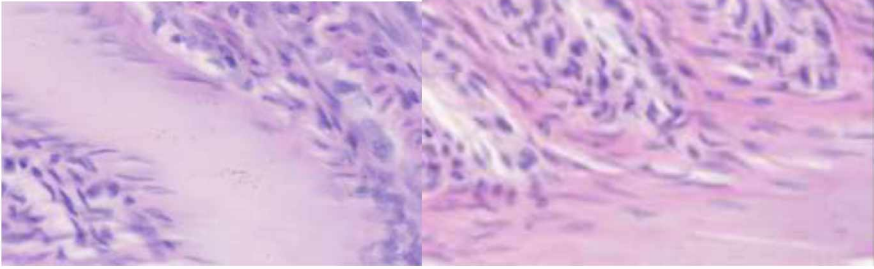
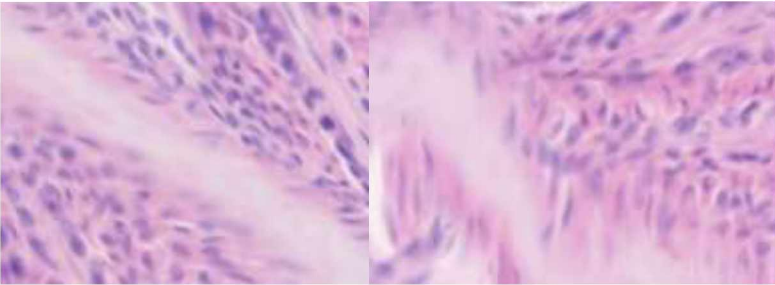
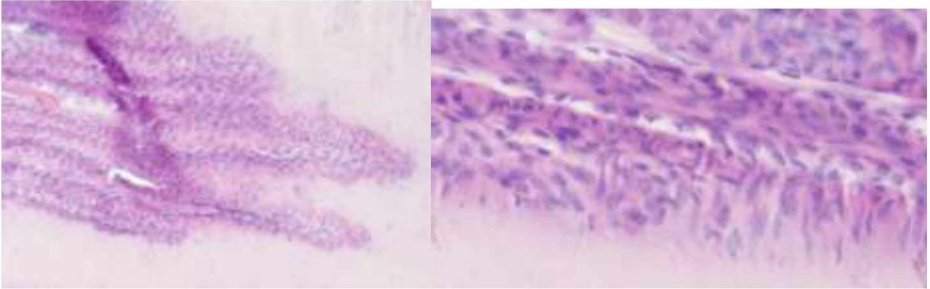
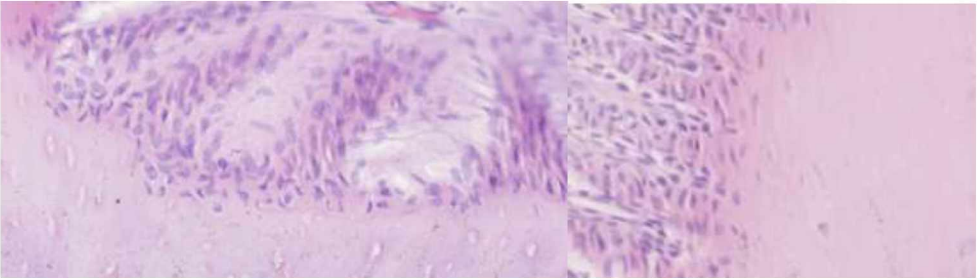
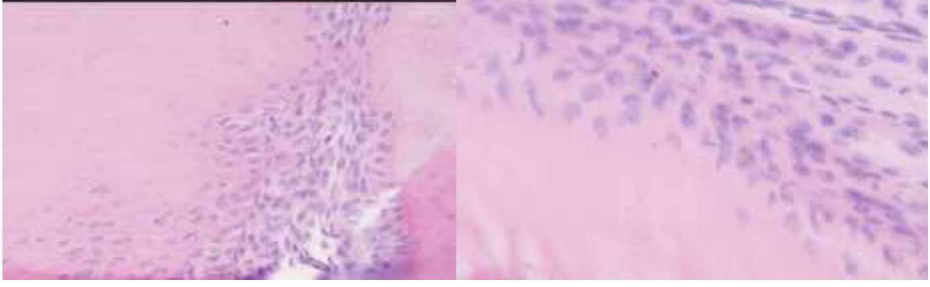
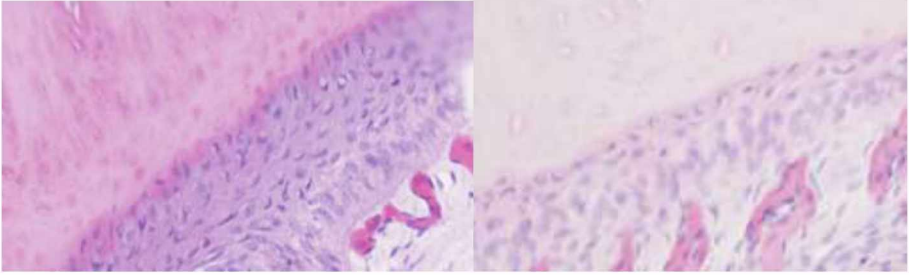
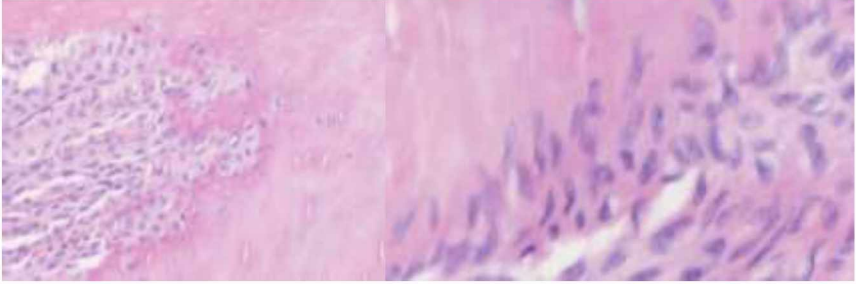
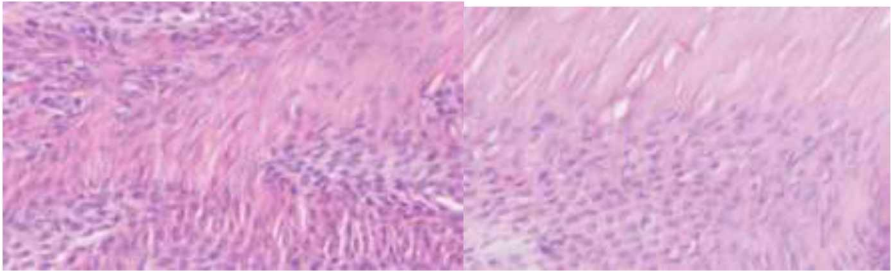
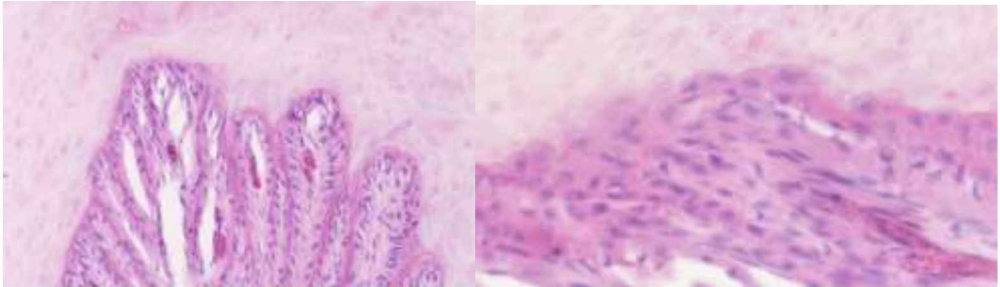
5-L	
5-R	

Table 5. Parameter “Secondary Epidermal Lamellae supra-basal cells”, samples of grade (1):

Those samples correspond to biopsies of the dorsal hoof wall of the horses with their identification number presented on the left. In this table are presented slides with mild findings of hyperplasia or dysplasia of SEL supra-basal cells (grade 1).

4-L	
4-R	



7-L	
7-R	
11-L	
11-R	
12-L	

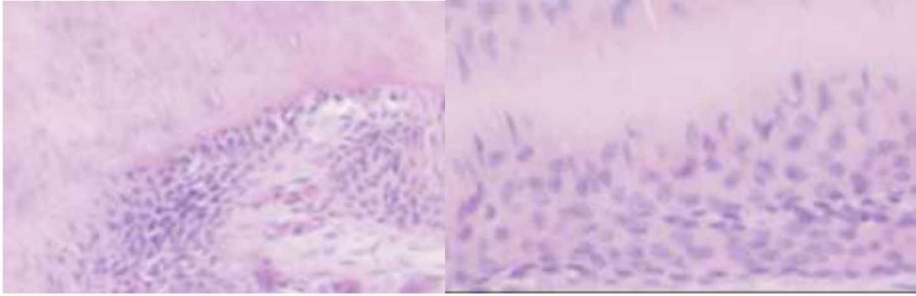
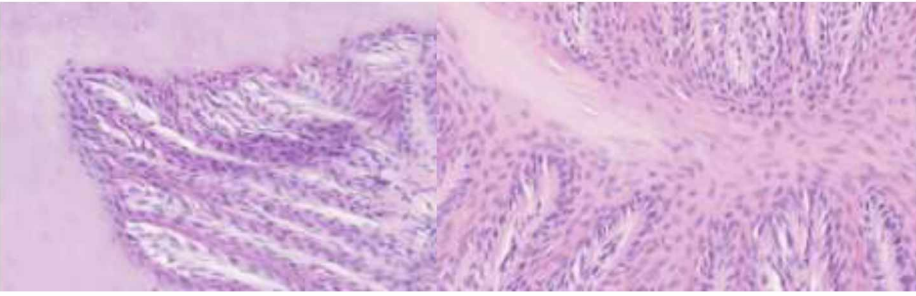
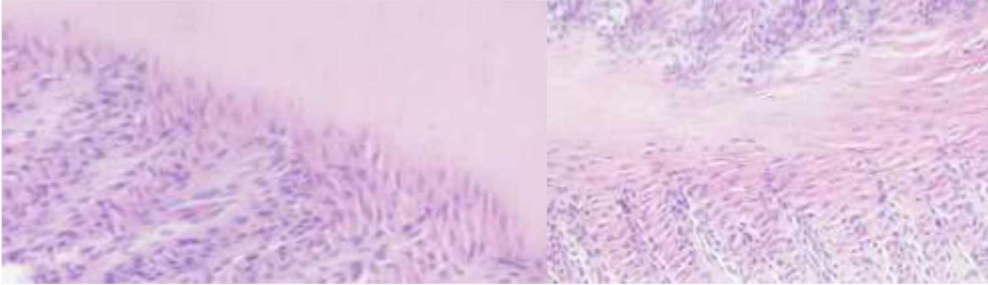
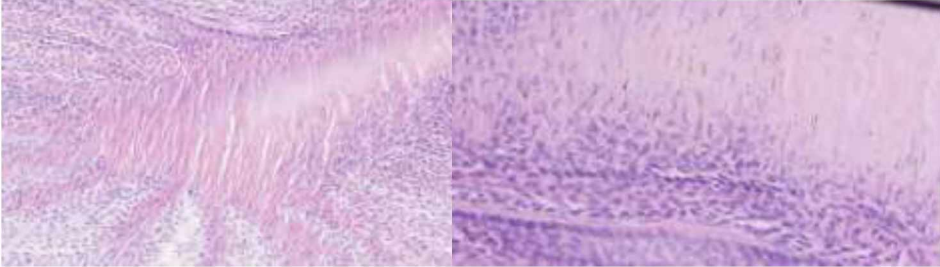
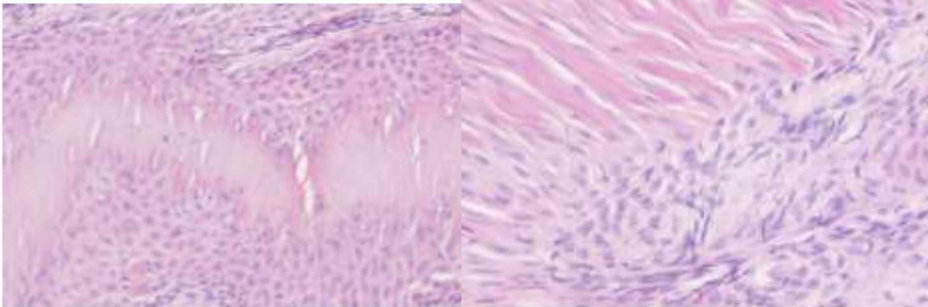
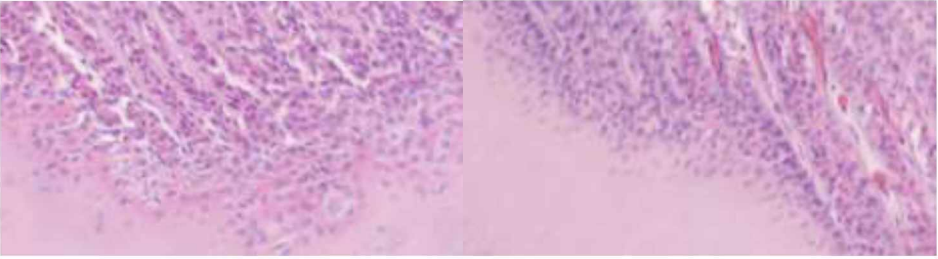
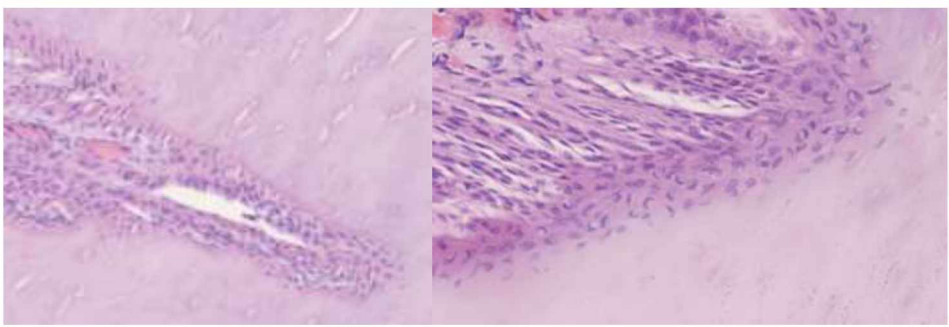
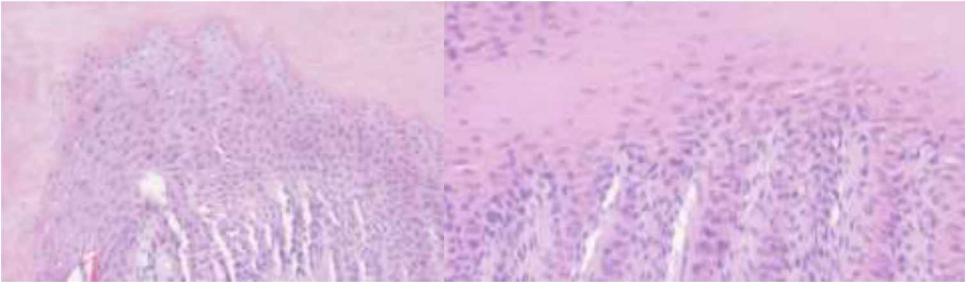
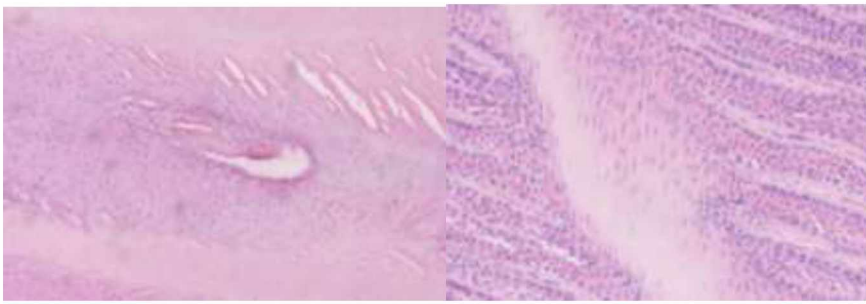
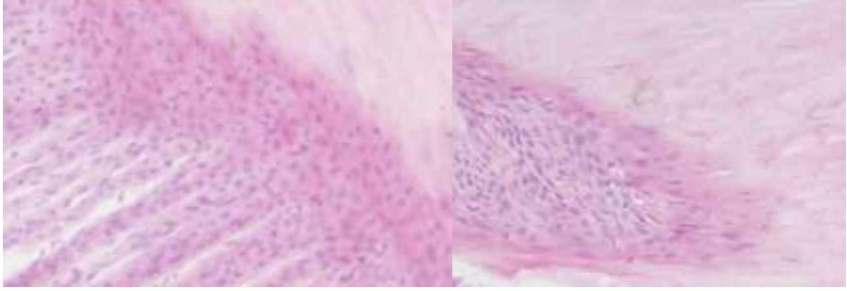
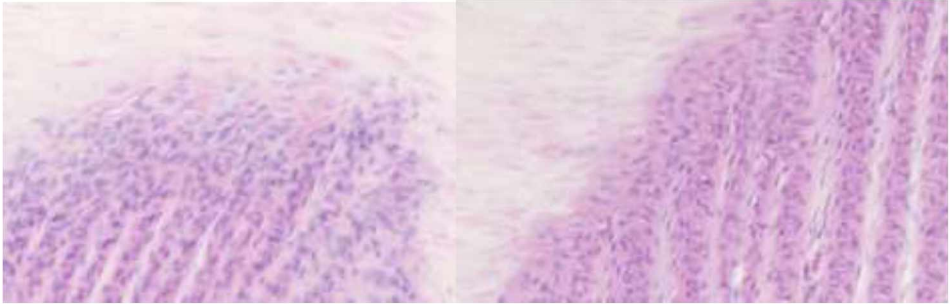
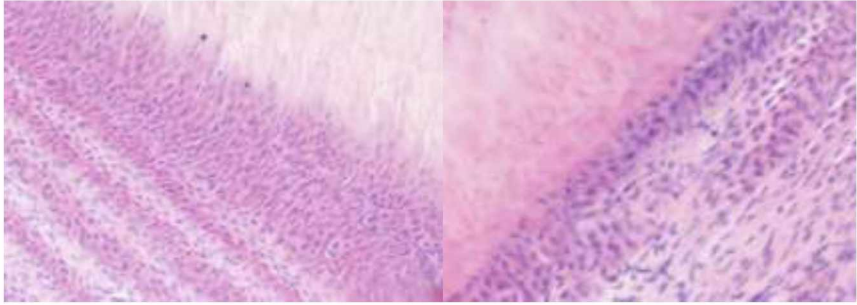
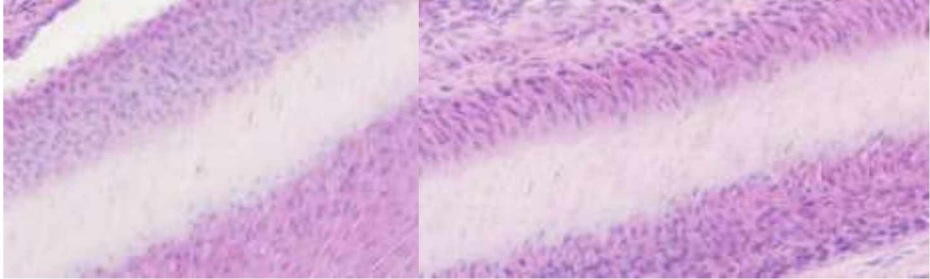
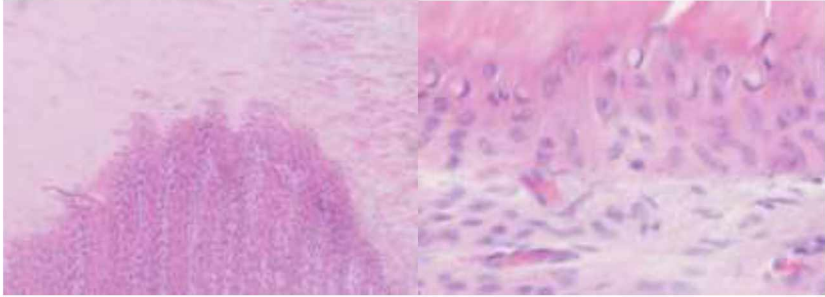
12-R	
14-R	
18-L	
19-L	
21-R	



Table 6. Parameter “Secondary Epidermal Lamellae supra-basal cells”, samples of grade 2:

Those samples correspond to biopsies of the dorsal hoof wall of the horses with their identification number presented on the left. In this table are presented slides with moderate findings of hyperplasia or dysplasia of SEL supra-basal cells (grade 2):

1-L	
1-R	
6-L	
6-R	

8-R	
9-R	
10-L	
10-R	
13-R	

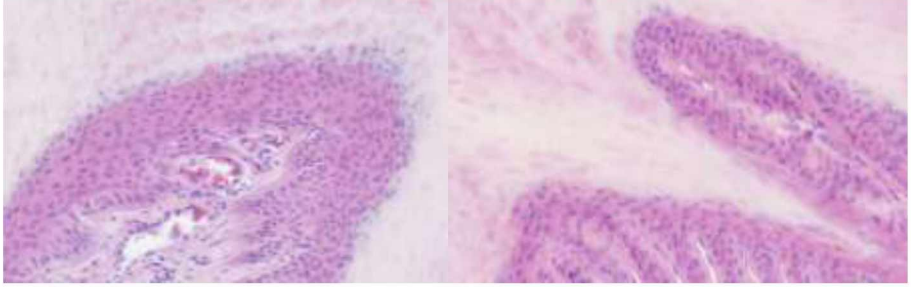
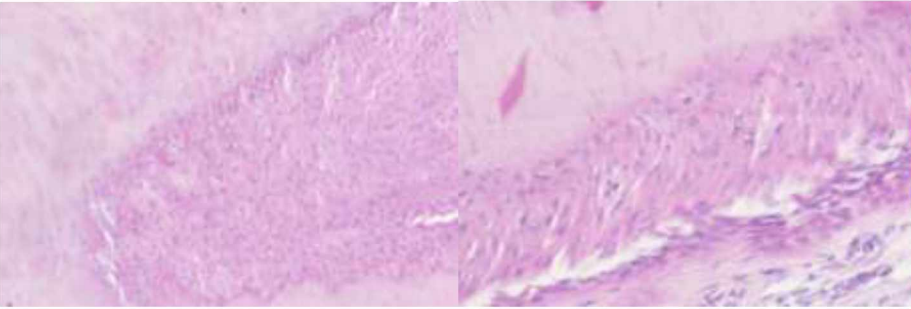
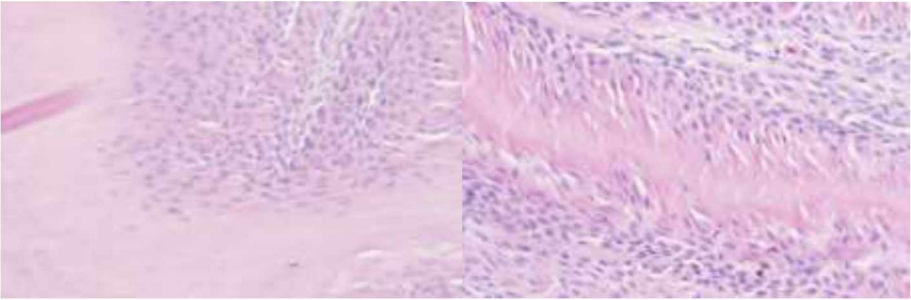
14-L	
16-L	
20-L	

Table 7. Parameter “Secondary Epidermal Lamellae supra-basal cells”, samples of grade (3):

This sample corresponds to biopsies of the dorsal hoof wall of the horse with its identification number presented on the left. In this table are presented slides with severe findings of hyperplasia or dysplasia of SEL supra-basal cells accompanied by hyperkeratosis and intercellular bridging (grade 3):

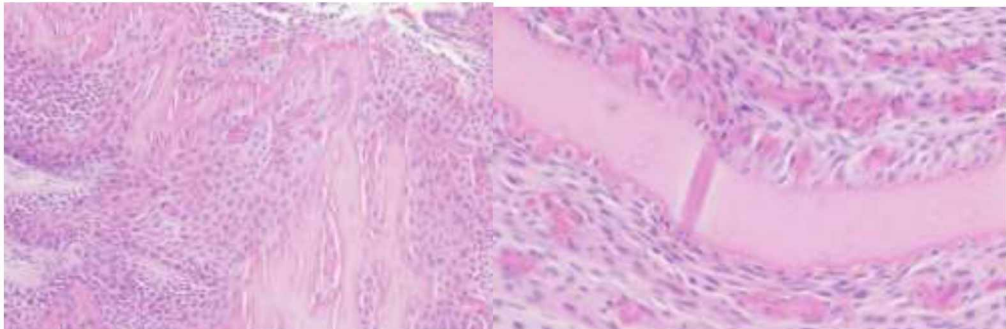
17-R	
------	--



Table 8. Parameter ‘Basement Membrane’, samples of grade (0):

Those samples correspond to biopsies of the dorsal hoof wall of the horses with their identification number presented on the left. In this table are presented slides with a physiological, intact basement membrane (grade 0):

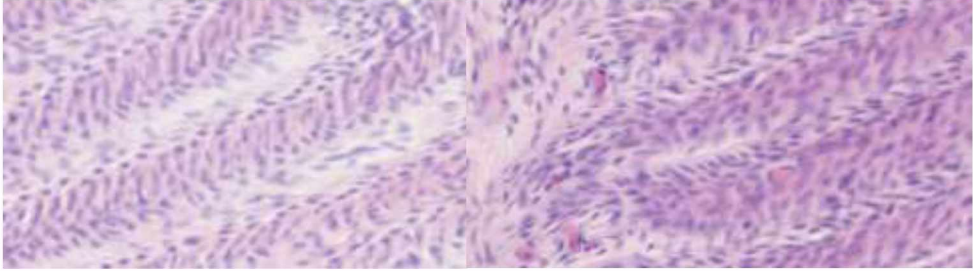
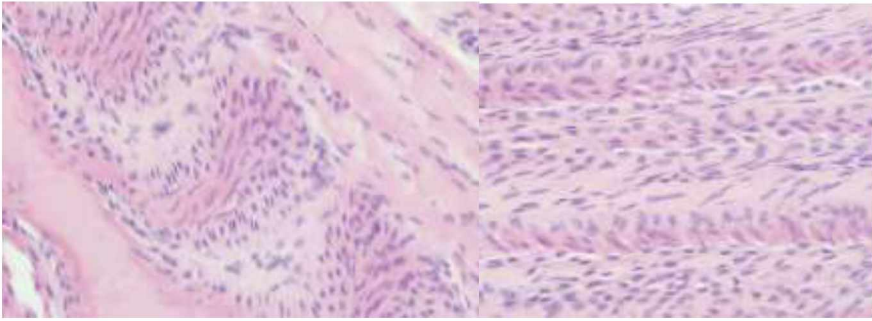
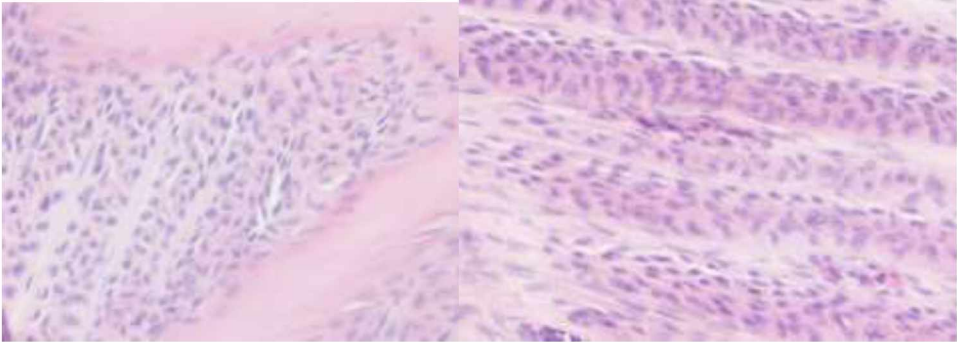
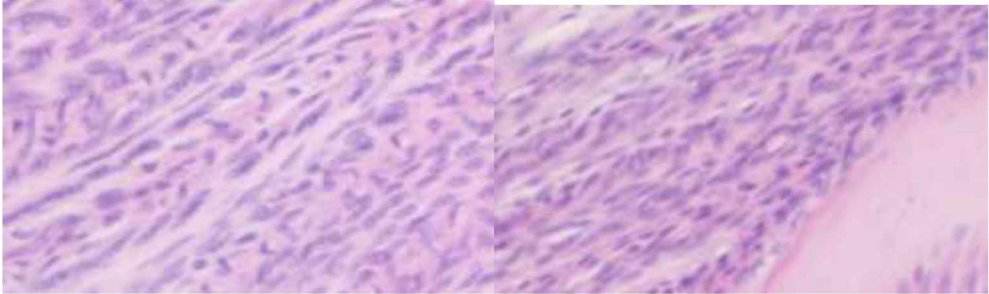
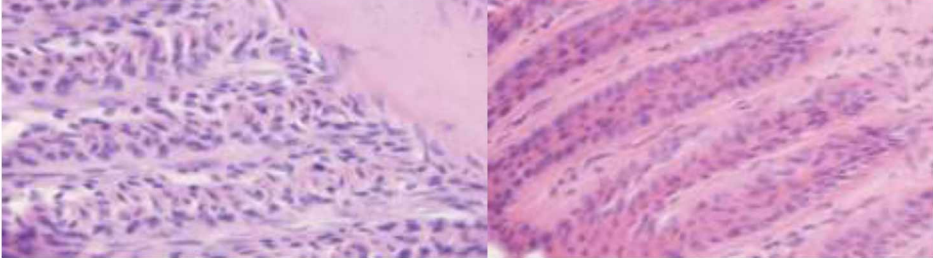
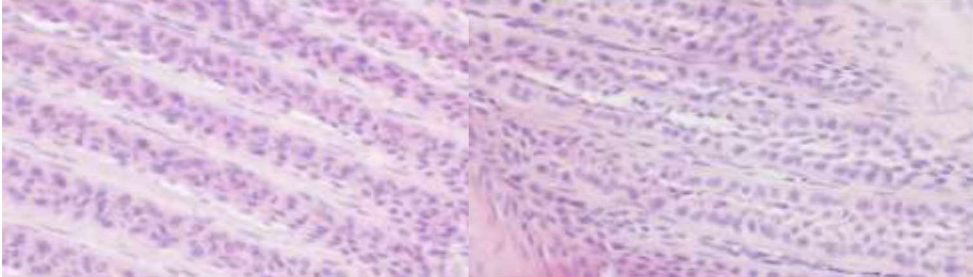
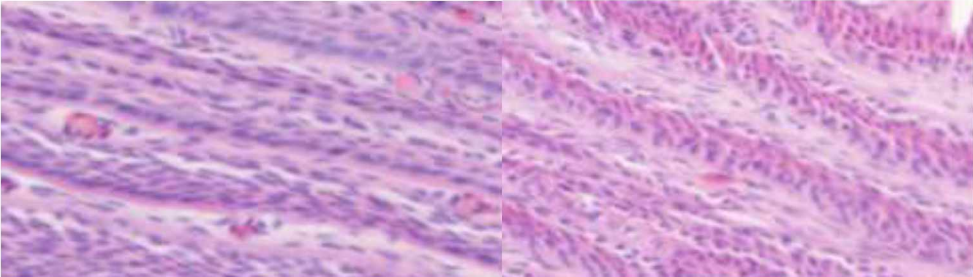
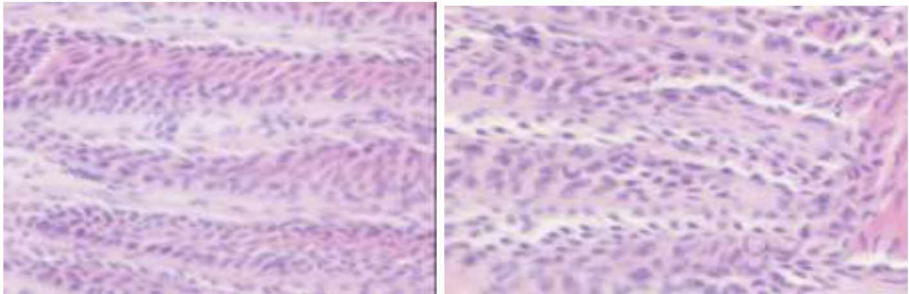
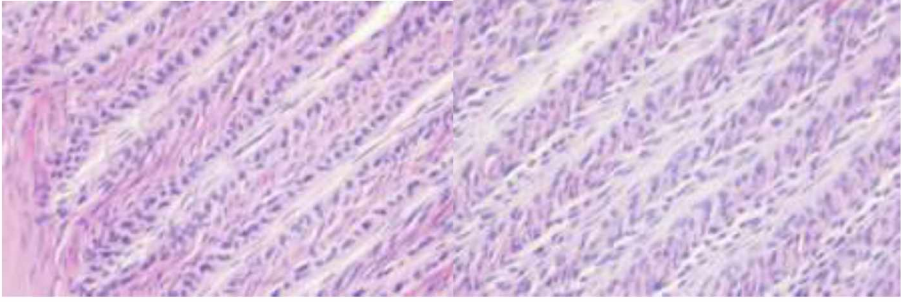
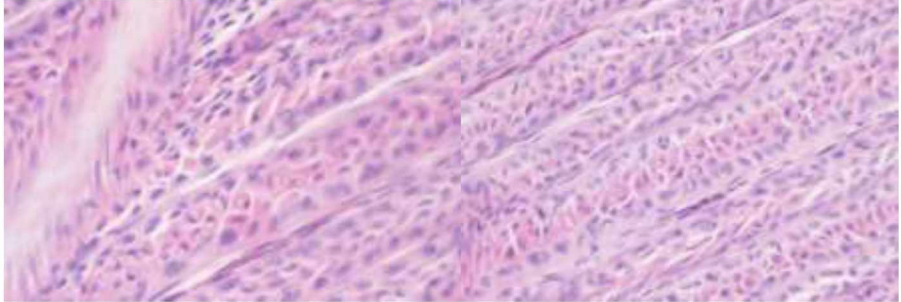
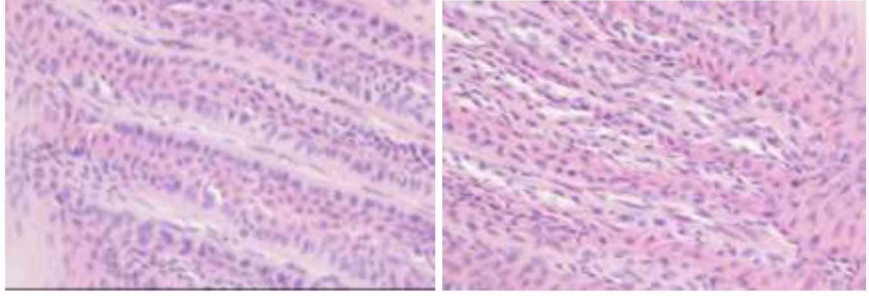
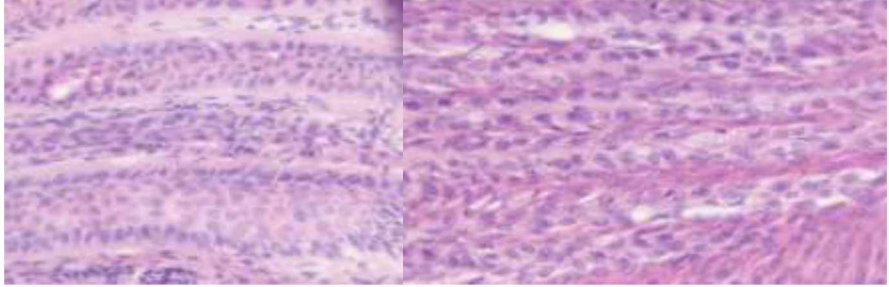
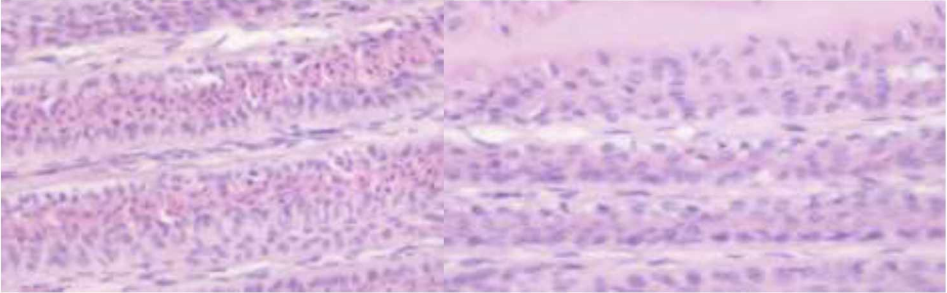
3-L	
3-R	
7-L	
7-R	

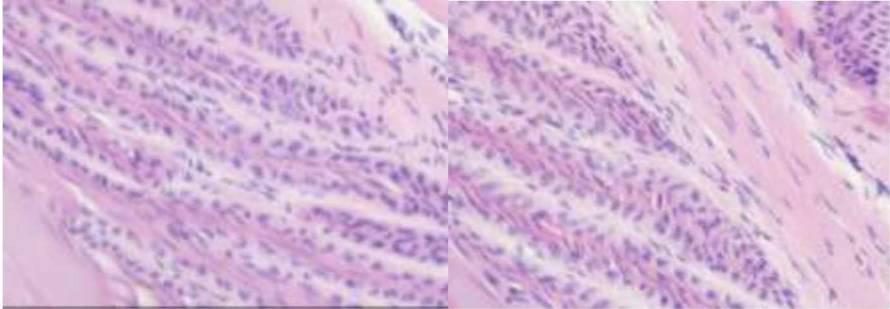
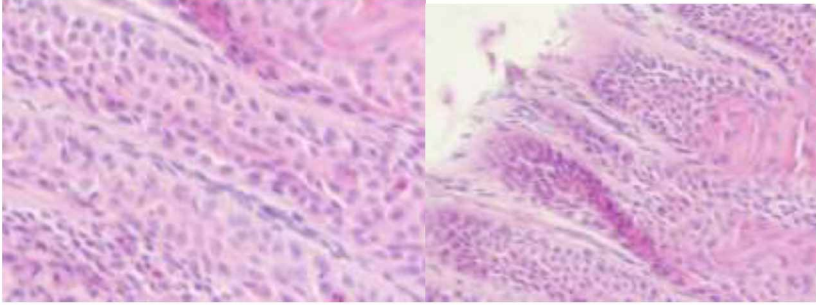
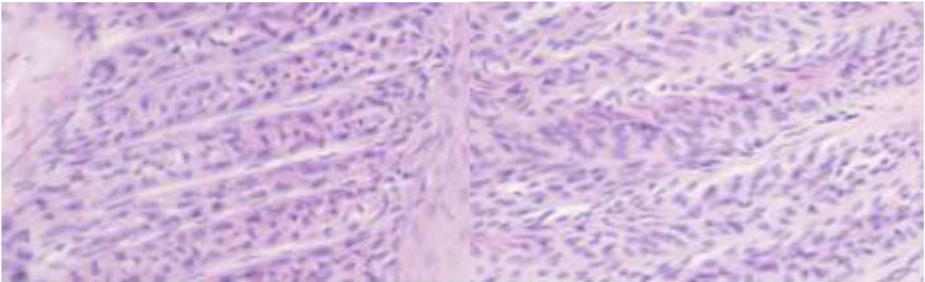
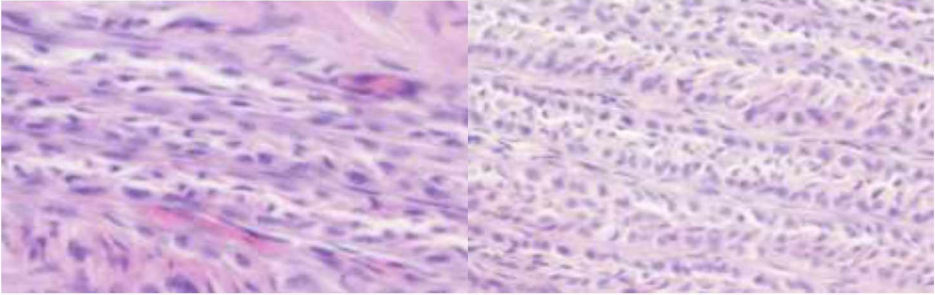
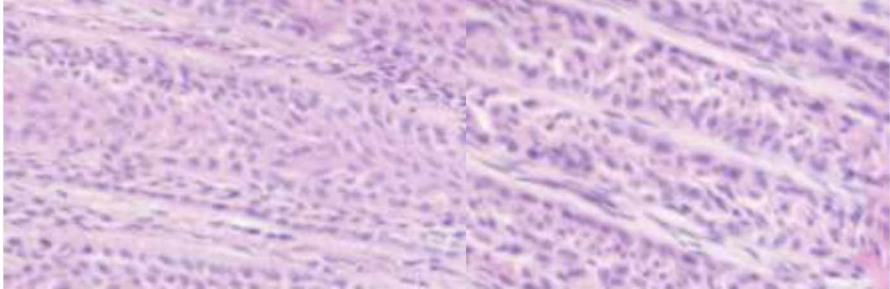
Table 9. Parameter “Basement Membrane”, samples of grade (1):

Those samples correspond to biopsies of the dorsal hoof wall of the horses with their identification number presented on the left. In this table are presented slides with presence of basement membrane duplication (grade 1):

2-L	
2-R	
4-L	
4-R	



5-L	
5-R	
6-R	
11-R	
12-R	

14-R	
17-R	
18-L	
19-L	
20-L	



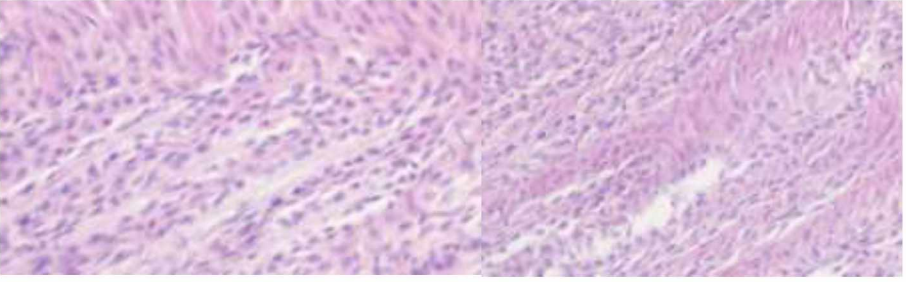
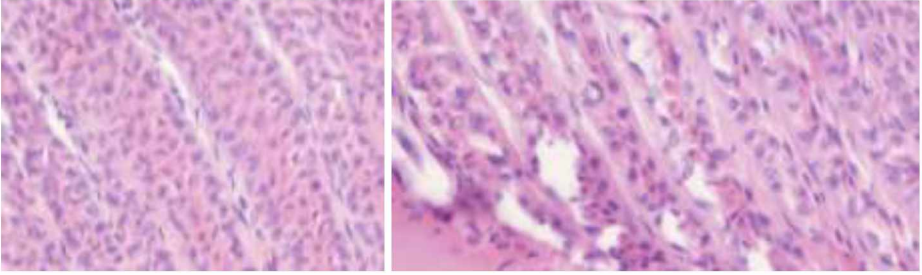
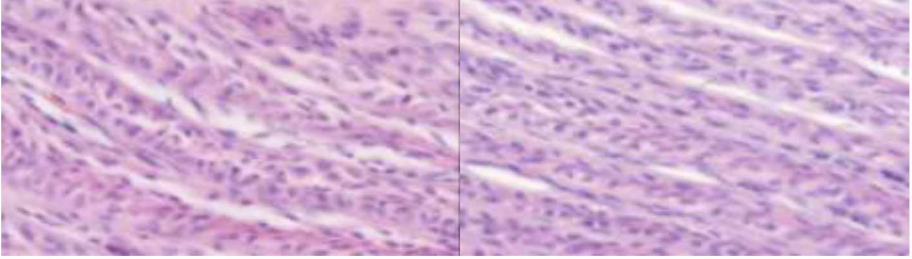
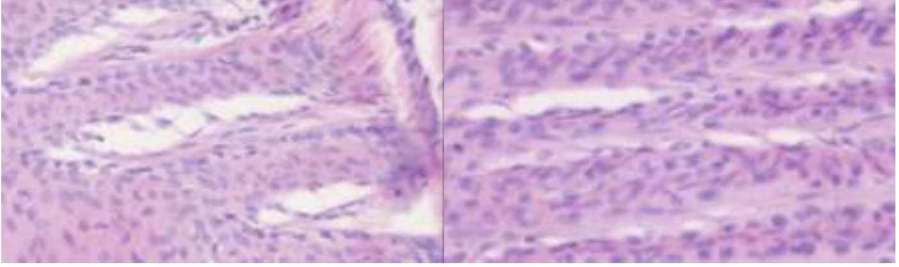
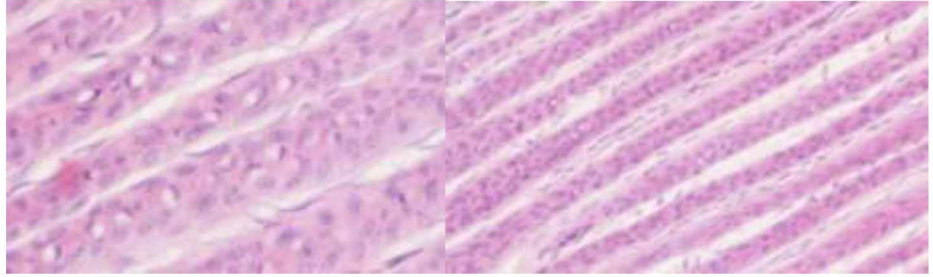
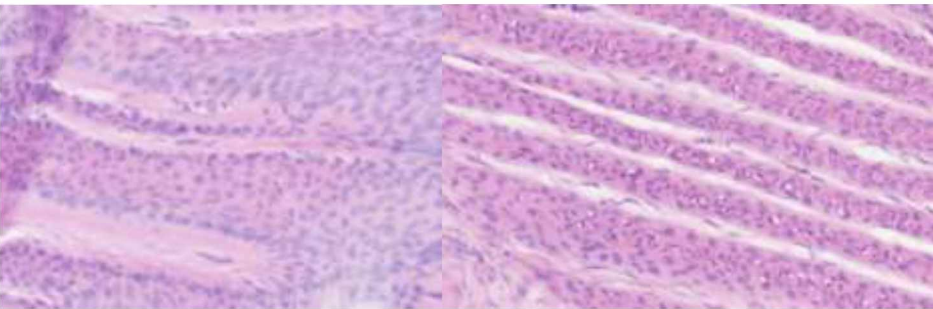
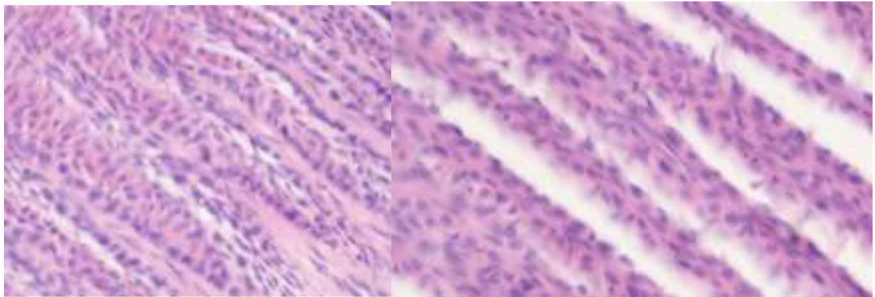
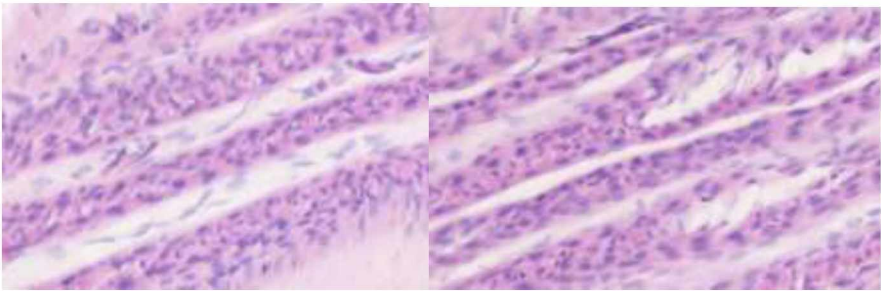
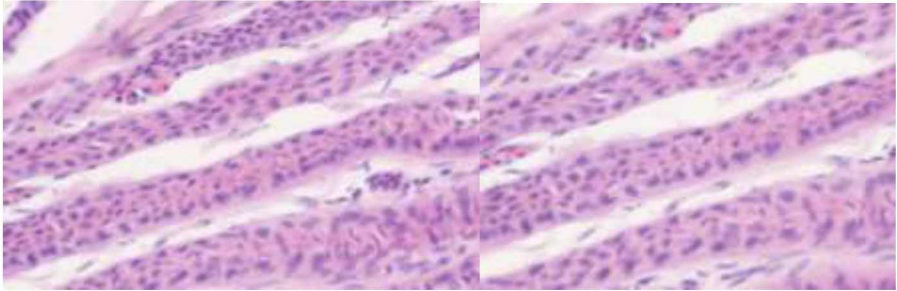
21-R	
------	--

Table 10. Parameter “Basement Membrane”, samples of grade (2):

Those samples correspond to biopsies of the dorsal hoof wall of the horses with their identification number presented on the left. In this table are presented slides with presence of a partial basement membrane separation (grade 2):

1-L	
1-R	
6-L	



8-R	
9-R	
10-L	
10-R	
11-L	

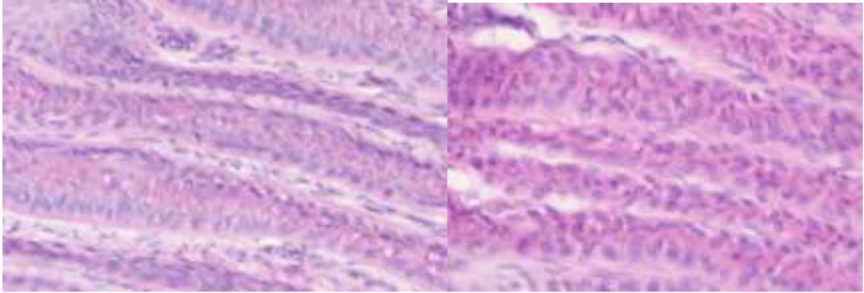
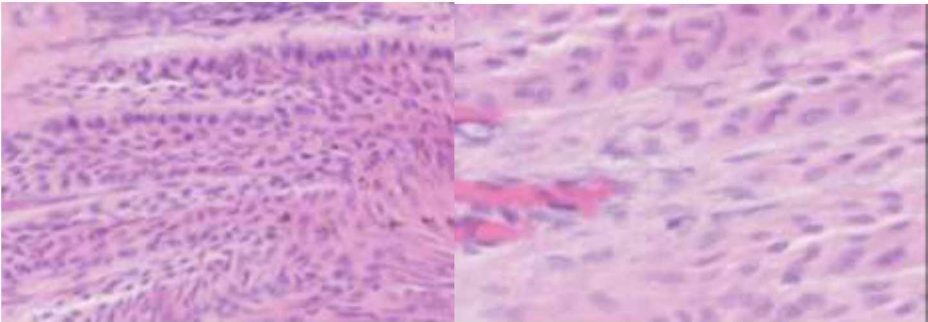
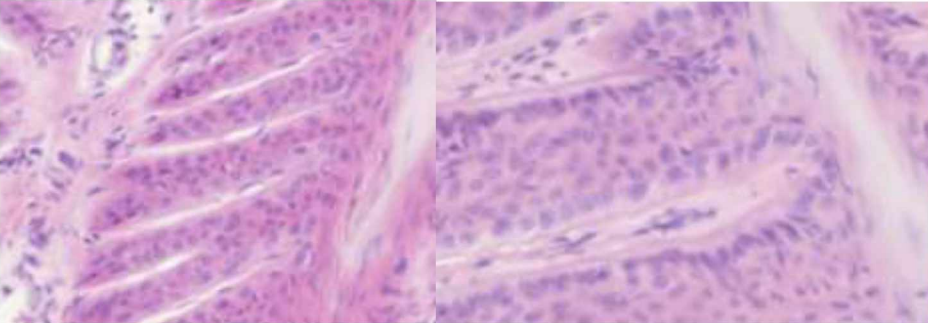
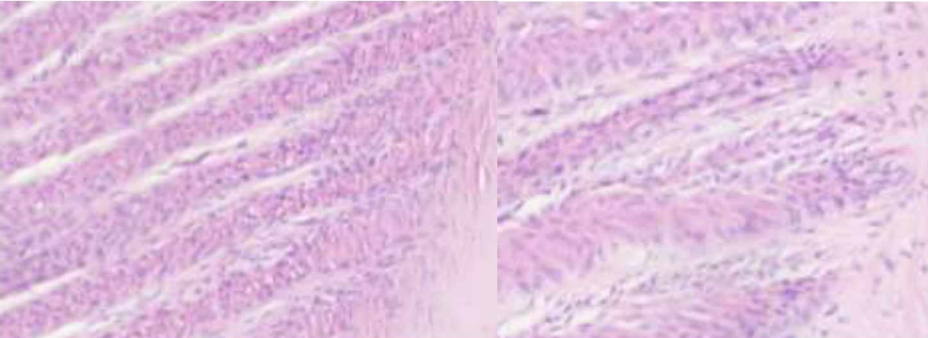
12-L	
13-R	
14-L	
16-L	

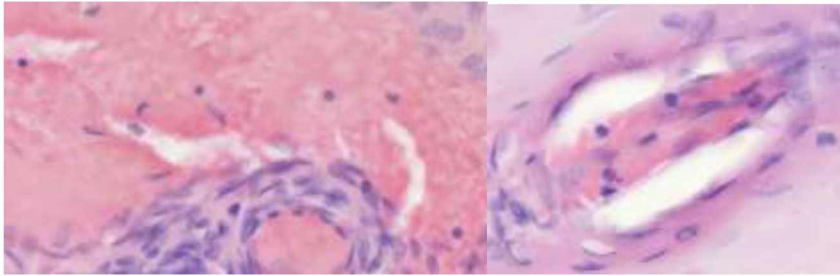
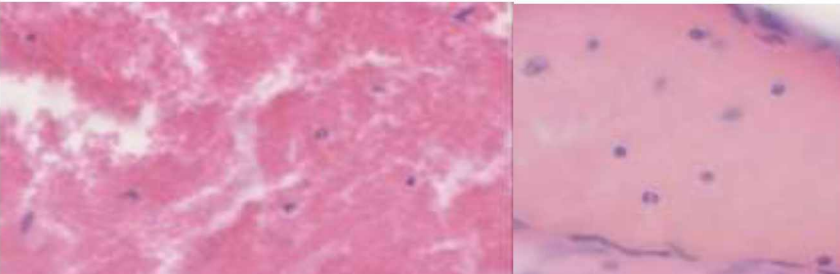
Table 11. Parameter “Cellular infiltration”, samples of grade (0):

Those samples correspond to biopsies of the dorsal hoof wall of the horses with their identification number presented on the left. In this table no slides present dermal inflammatory cells infiltrate either in lamellae or corium such as in a physiological state (grade 0) was noted.

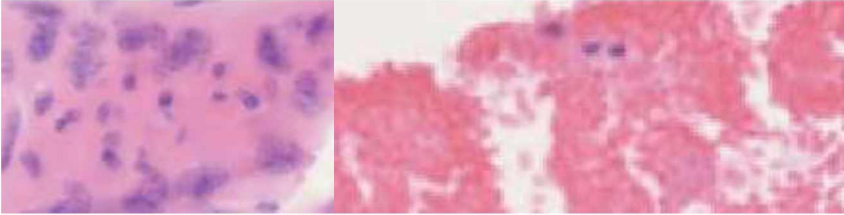
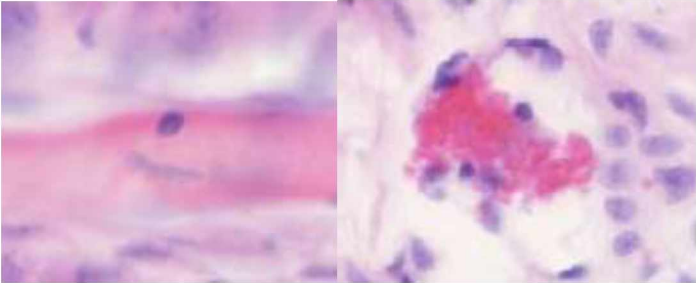
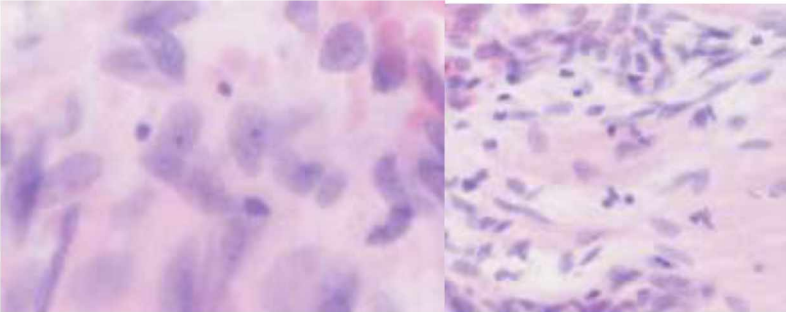


2-L	No findings
2-R	No findings
7-R	No findings
11-L	No findings
14-R	No findings
17-R	No findings
18-L	No findings

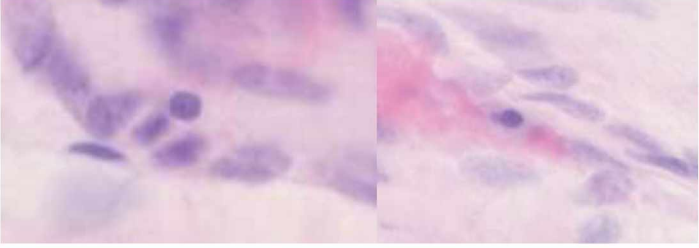
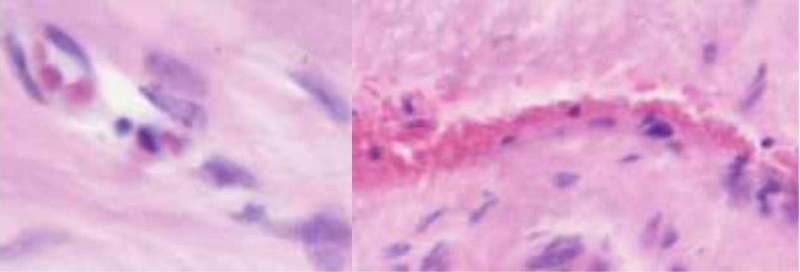
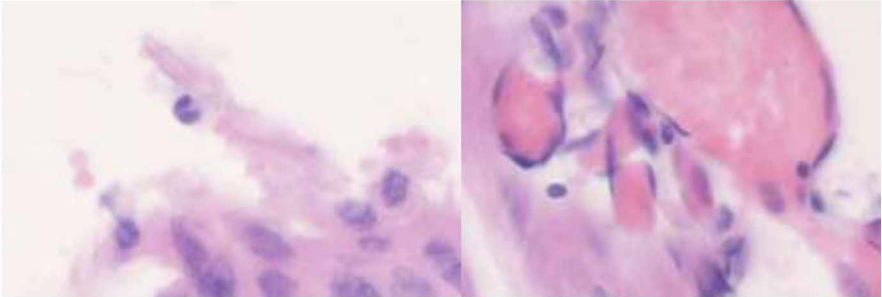
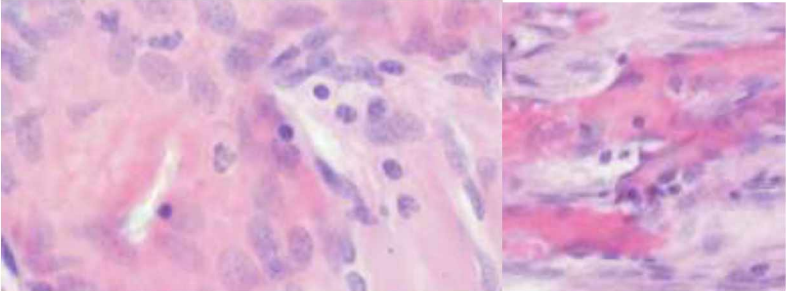
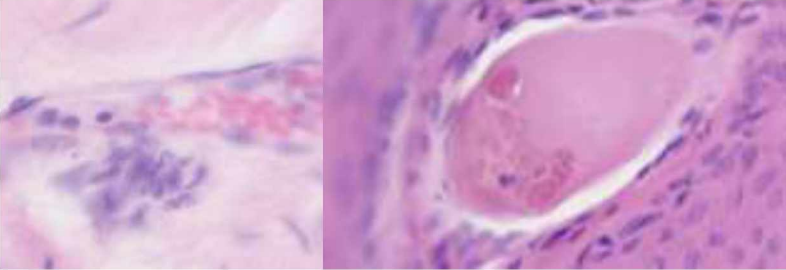
Table 12. Parameter “Cellular infiltration”, samples of grade (1):

Those samples correspond to biopsies of the dorsal hoof wall of the horses with their identification number presented on the left. In this table are presented slides with a presence of rare LC (lymphocytes) presence with the absence of PLC (platelets leukocytes) (grade 1):

1-L	
3-L	



3-R	
4-L	
4-R	
5-L	
5-R	

7-L	
12-L	
12-R	
13-R	
14-L	

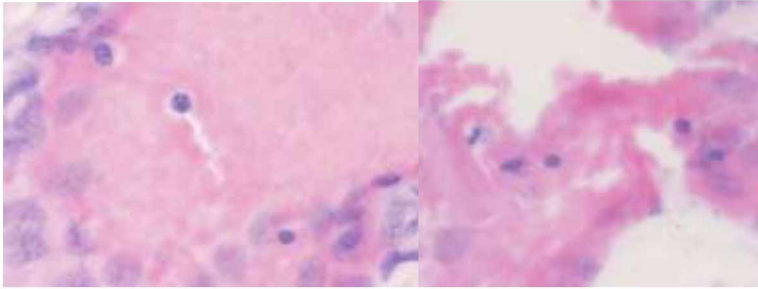
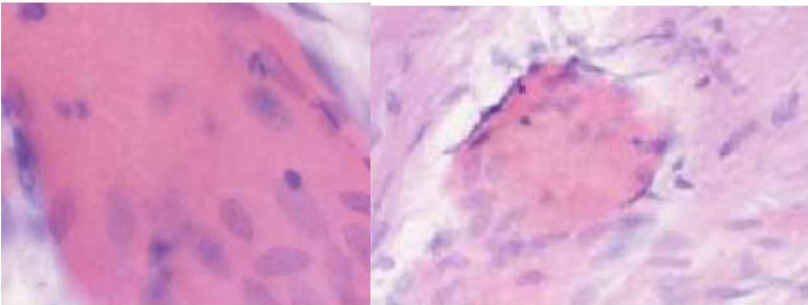
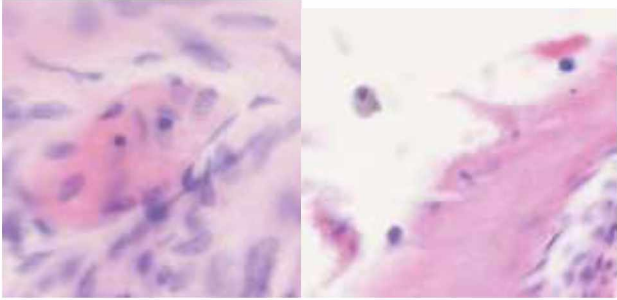
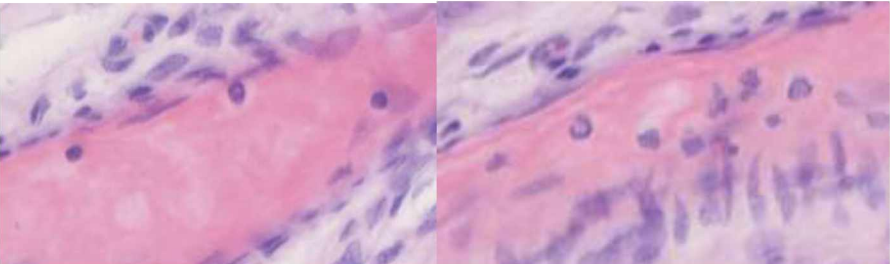
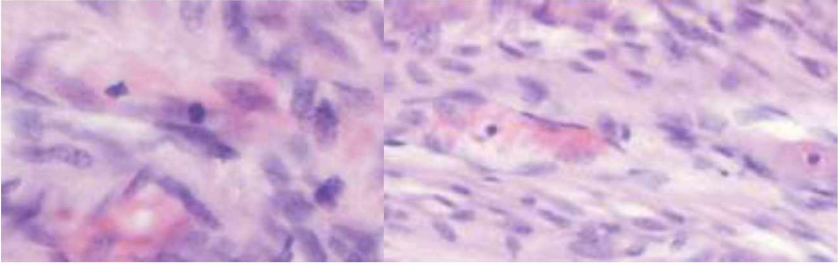
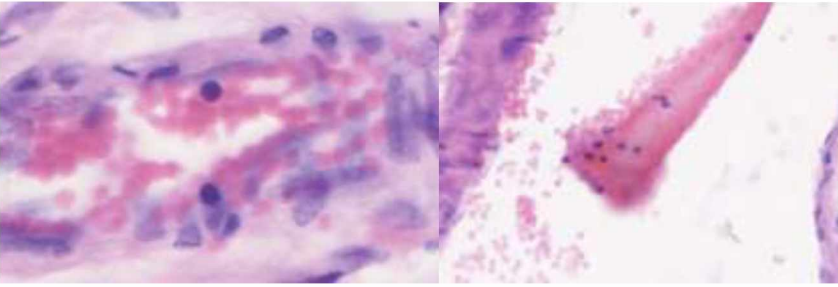
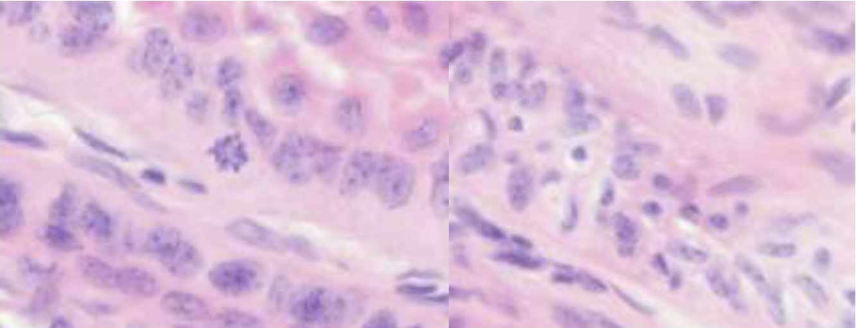
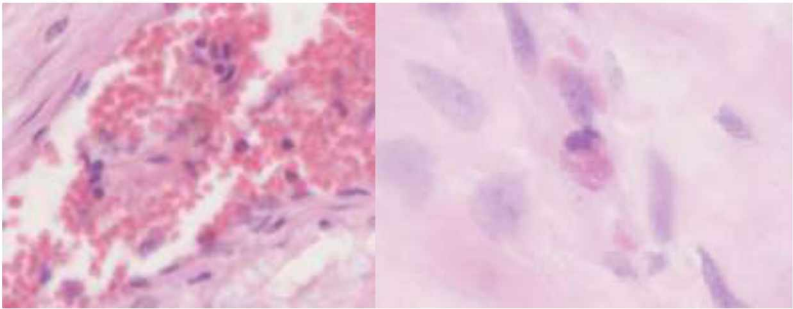
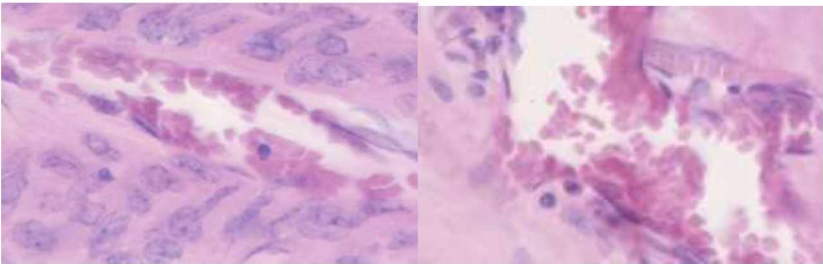
16-L	
19-L	
20-L	
21-R	

Table 13. Parameter “Cellular infiltration”, samples of grade (2):

Those samples correspond to biopsies of the dorsal hoof wall of the horses with their identification number presented on the left. In this table are presented slides with a presence of both LC with few PLC (grade 2):

1-R	
6-L	
6-R	
8-R	
9-R	



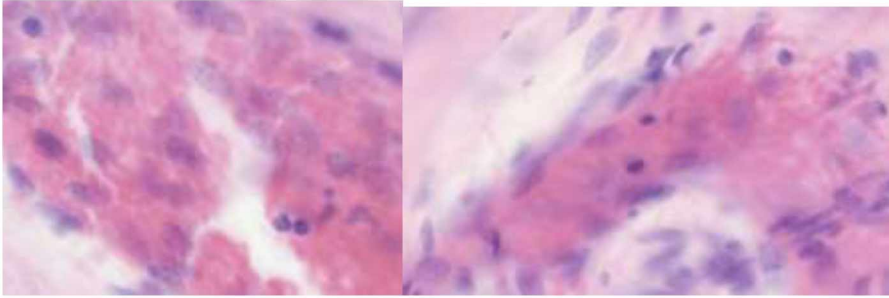
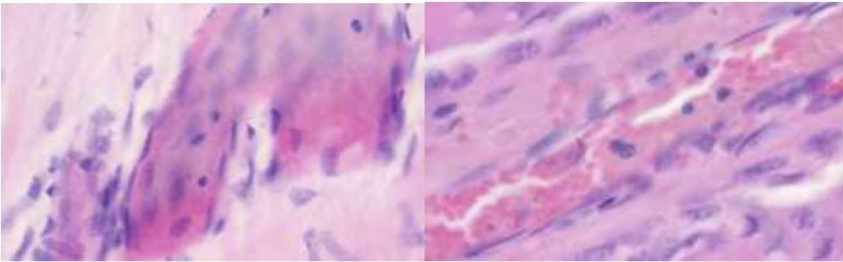
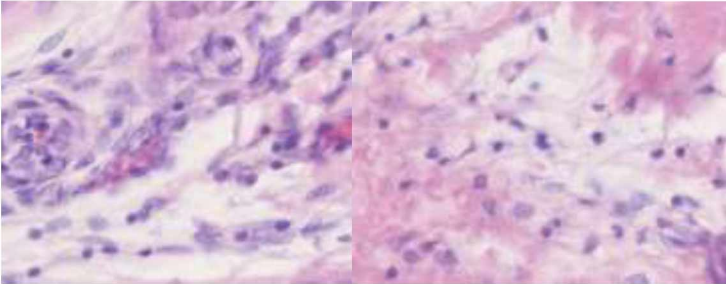
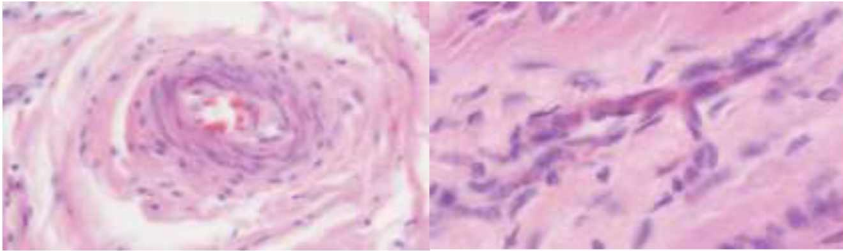
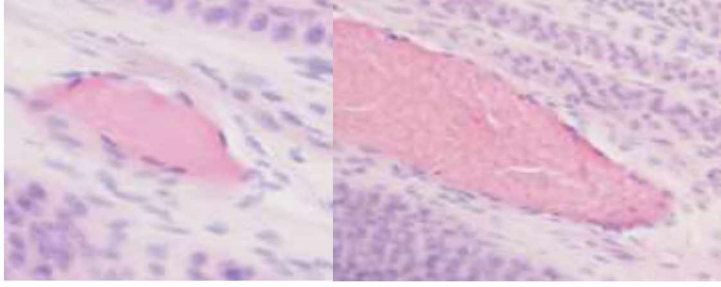
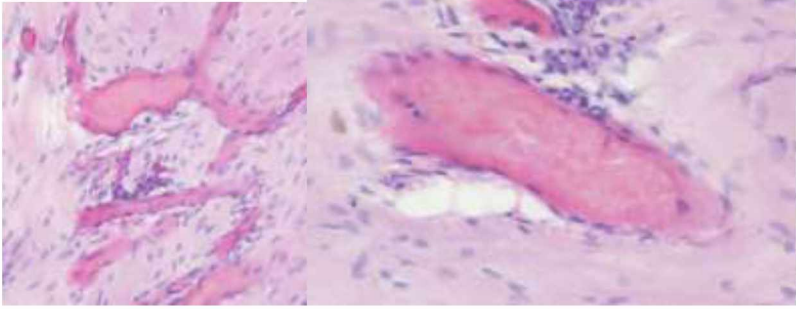
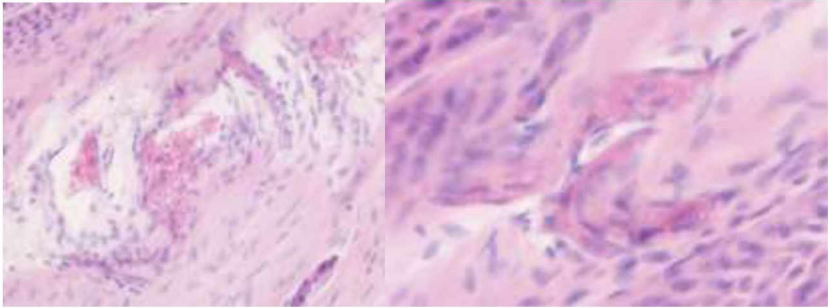
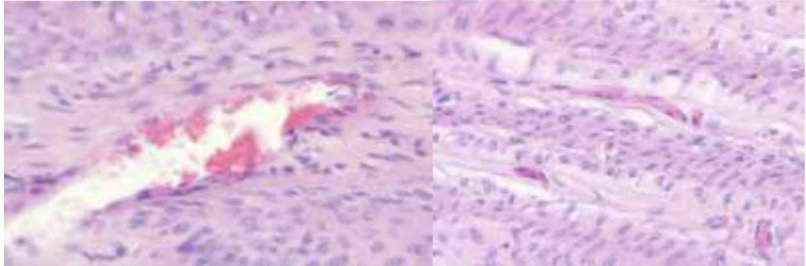
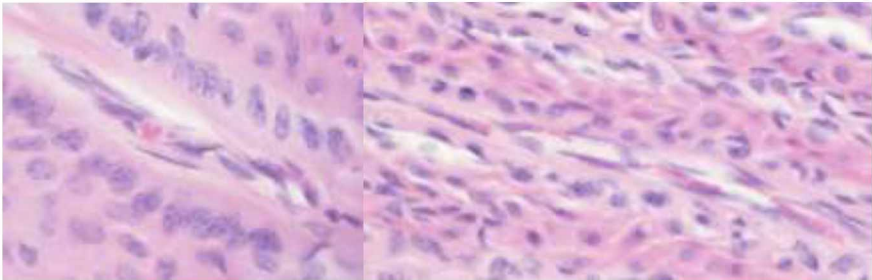
10-L	
10-R	
11-R	

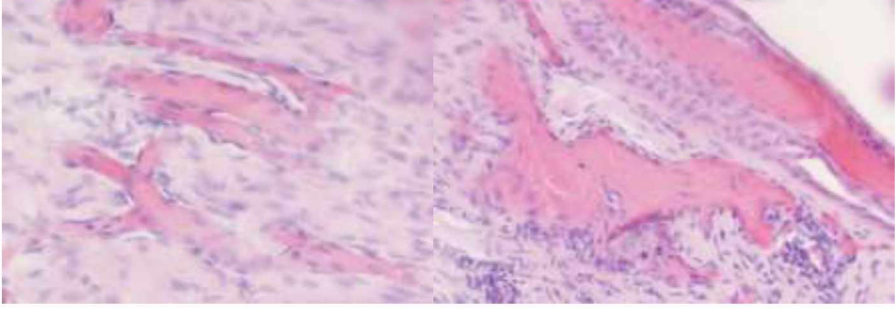
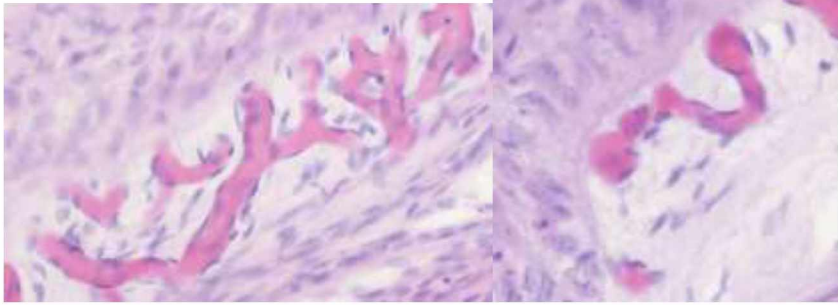
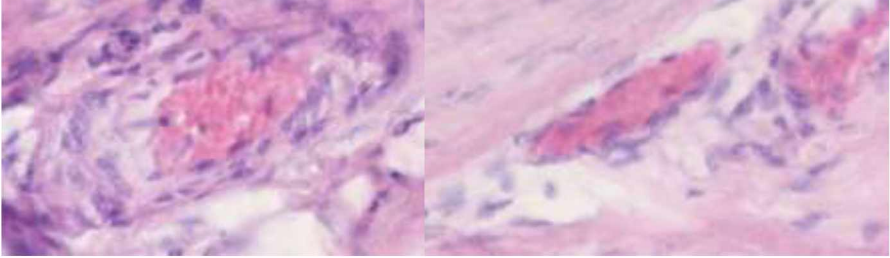
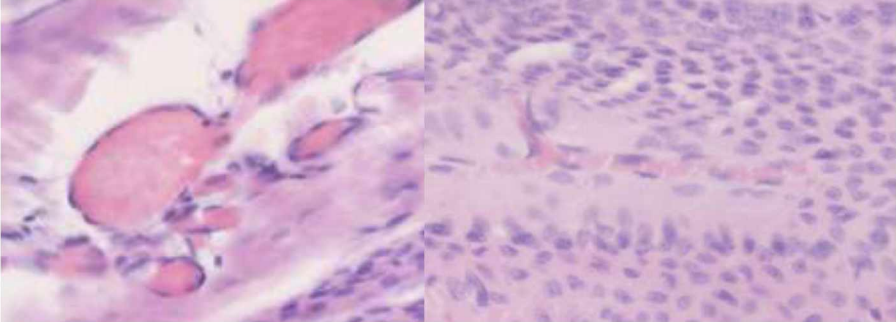
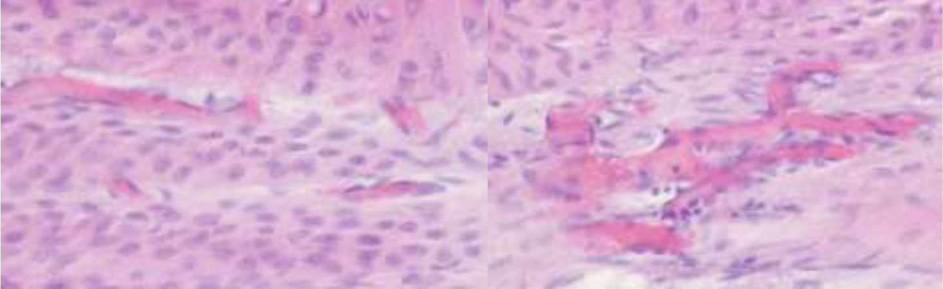
Table 14. Parameter “Vascularization”, samples of grade (0):

Those samples correspond to biopsies of the dorsal hoof wall of the horses with their identification number presented on the left. In this table are presented slides with no vascular pathology (grade 0):

2-L	
-----	--



2-R	
5-L	
5-R	
6-L	
6-R	

7-L	
7-R	
11-R	
12-R	
13-R	

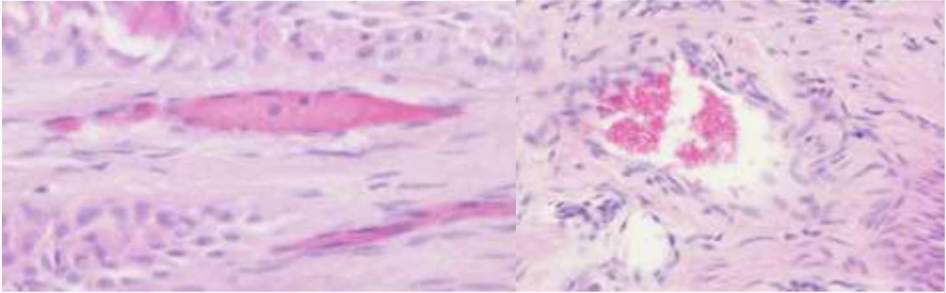
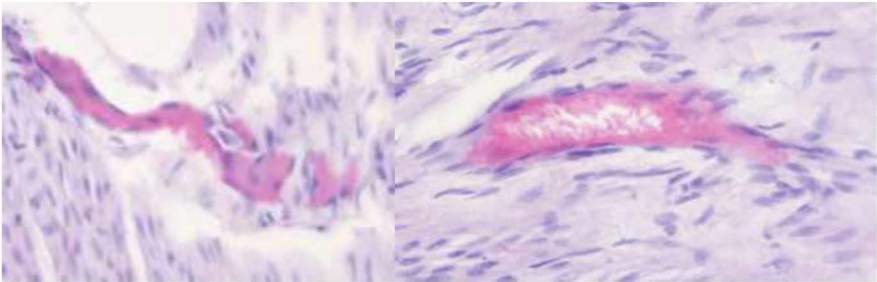
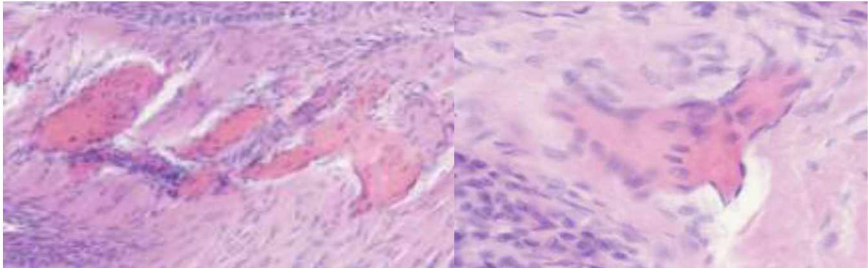
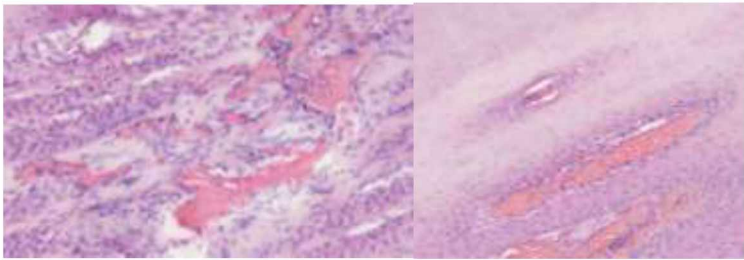
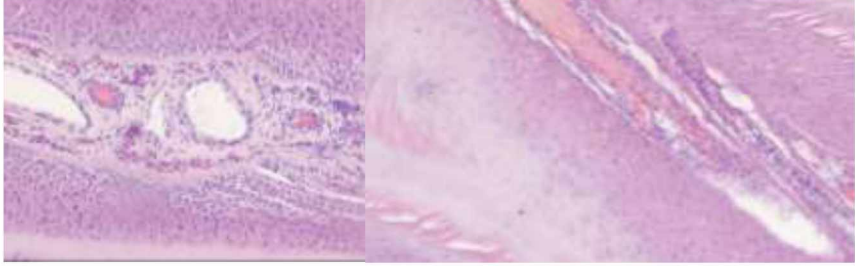
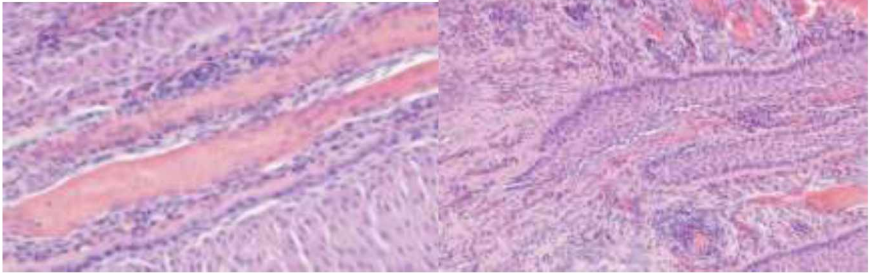
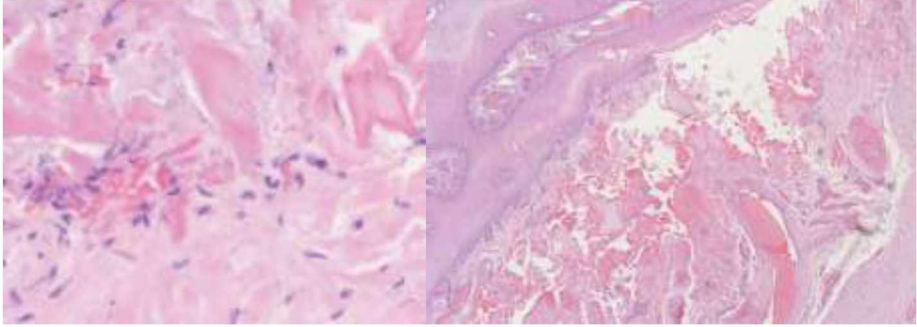
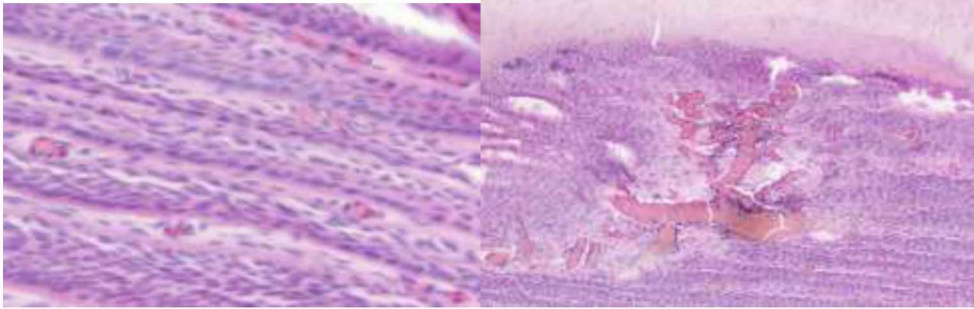
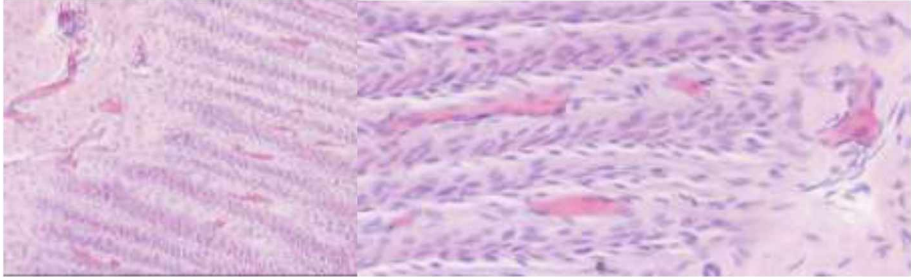
17-R	
18-L	
19-L	

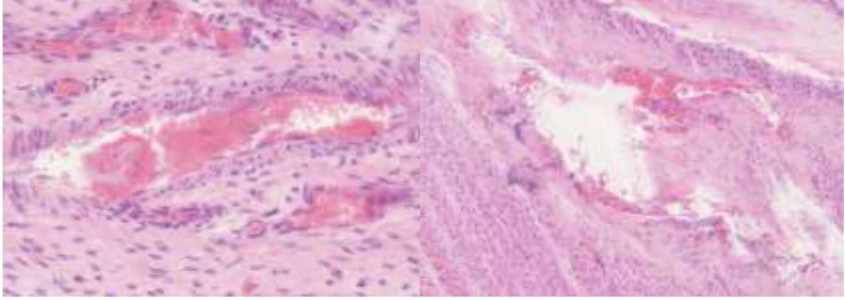
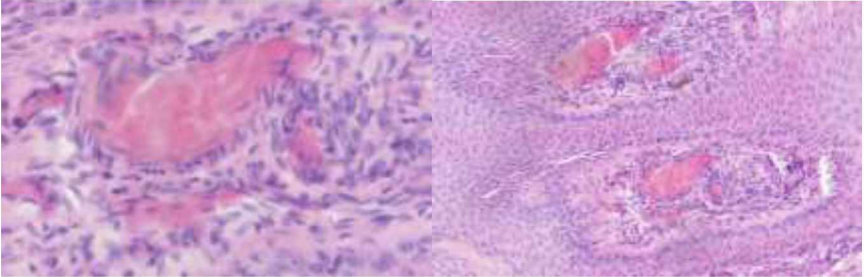
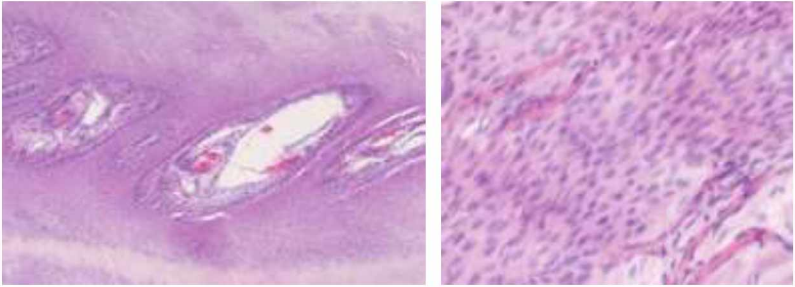
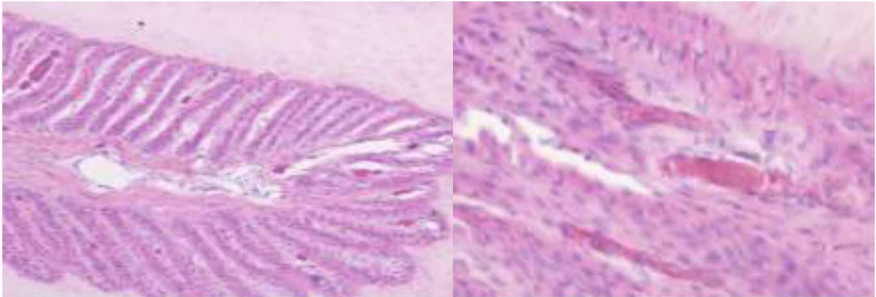
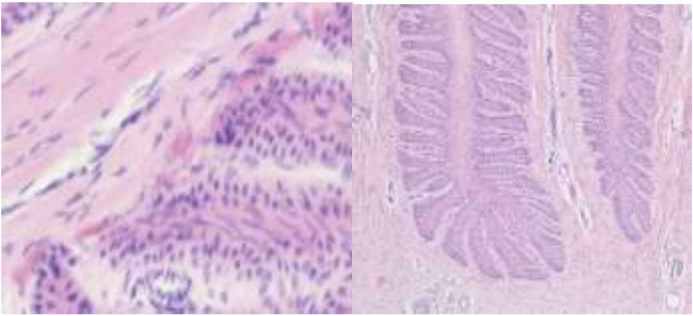
Table 15. Parameter “Vascularization”, samples of grade (1):

Those samples correspond to biopsies of the dorsal hoof wall of the horses with their identification number presented on the left. In this table are presented slides with compression or displacement of SDL capillaries which indicates mild dysplasia or inflammation of the lamellar blood vessels (grade 1):

1-L	
-----	--



1-R	
3-L	
3-R	
4-L	
4-R	

8-R	
10-R	
11-L	
12-L	
14-R	



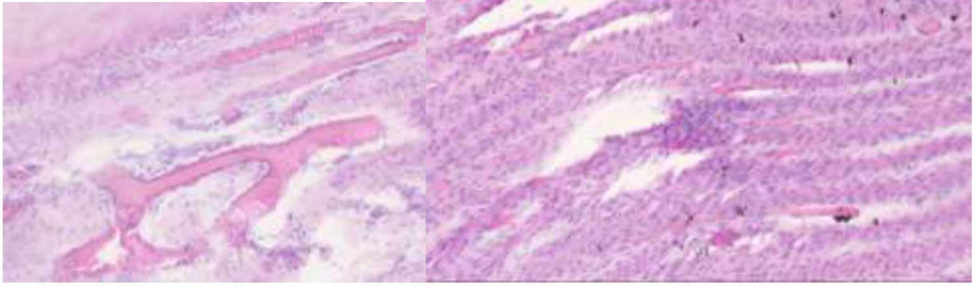
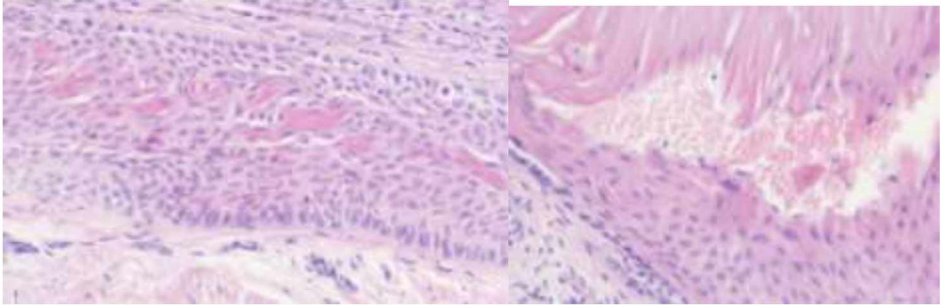
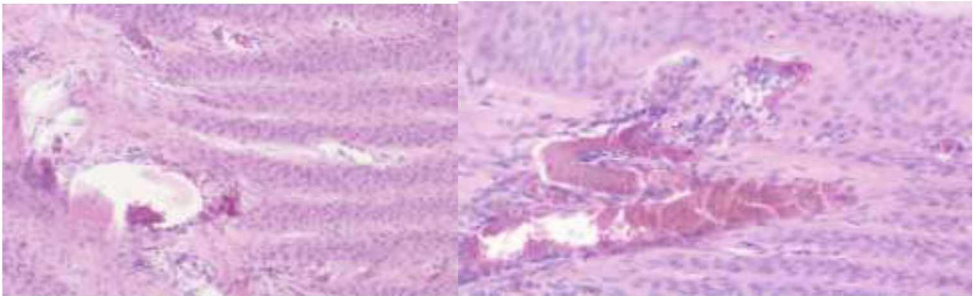
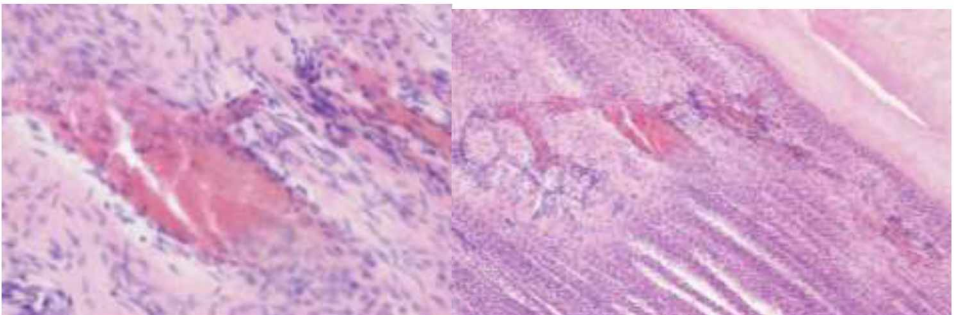
16-L	
20-L	

Table 16. Parameter “Vascularization”, samples of grade (2):

Those samples correspond to biopsies of the dorsal hoof wall of horses with identification number presented on the left. In this table are presented slides with characterised loss of SDL capillaries with haemorrhage which indicates moderate dysplasia or inflammation of the lamellar blood vessels (grade 2):

9-R	
10-L	

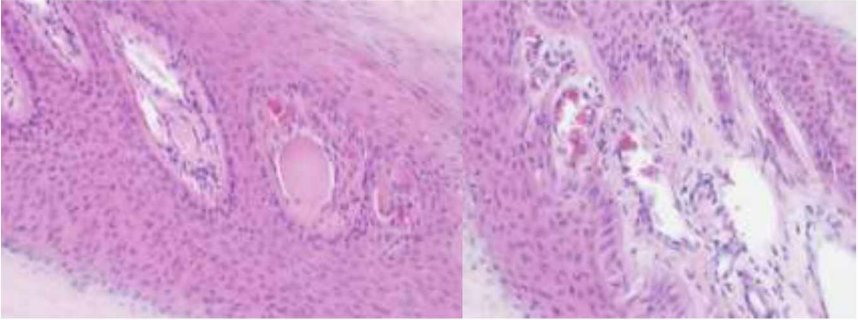
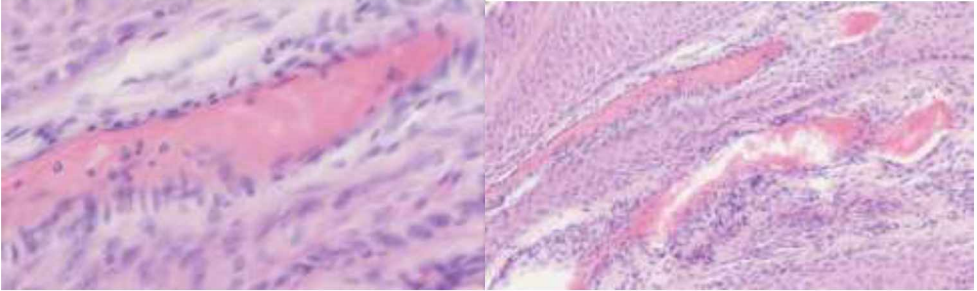
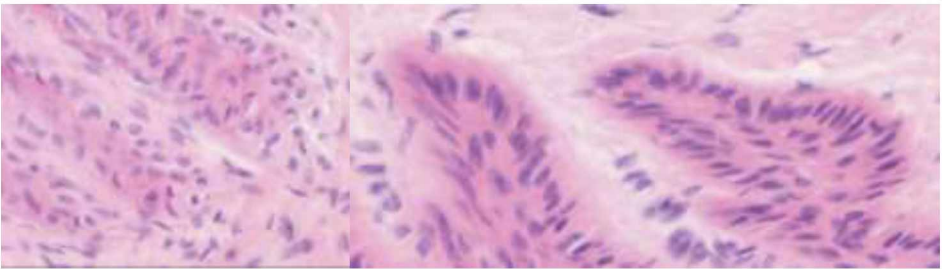
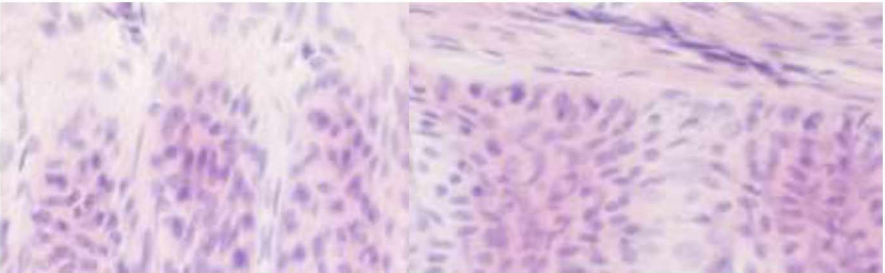
14-L	
21-R	

Table 17. Parameter “Epidermal Cell Response”, samples of grade (0):

Those samples correspond to biopsies of the dorsal hoof wall of the horses with their identification number presented on the left. In this table are presented slides presenting physiological epidermal cells (no EC response, grade 0):

2-L	
2-R	



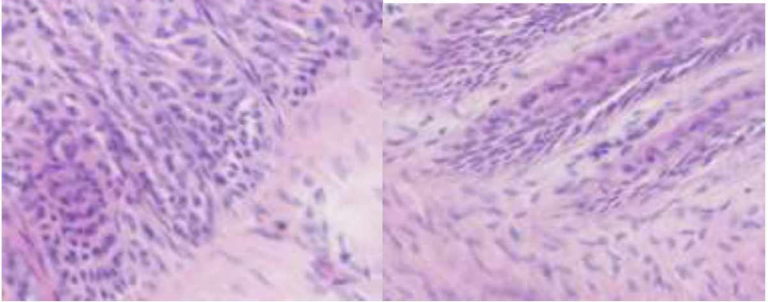
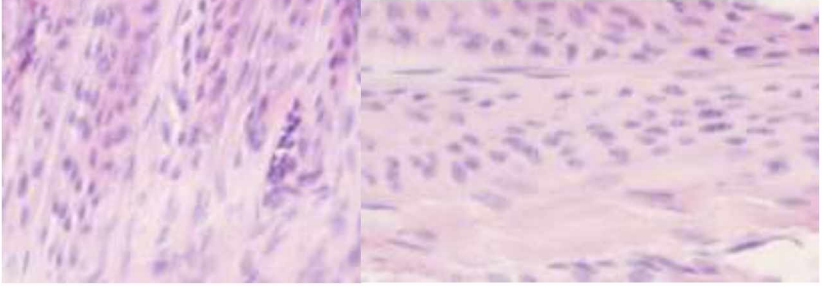
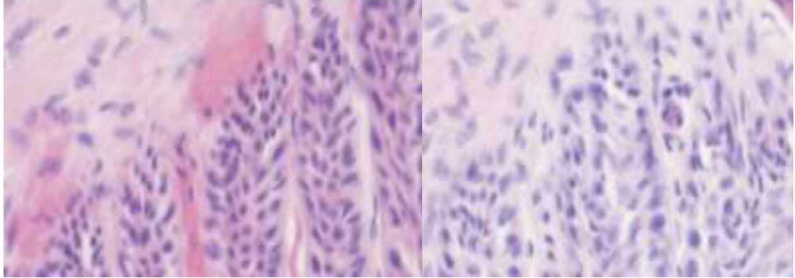
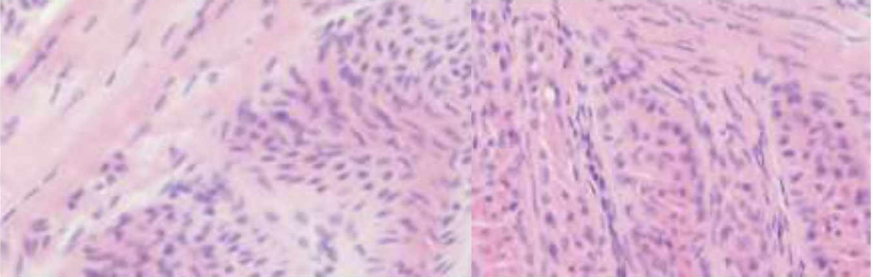
5-L	
7-L	

Table 18. Parameter “Epidermal Cell Response”, samples of grade (1):

Those samples correspond to biopsies of the dorsal hoof wall of the horses with their identification number presented on the left. In this table are presented slides with mild degenerative changes of the basal epidermal cells in the SEL, corresponding to nuclei which are rounded and more centrally orientated (grade 1):

3-L	
3-R	



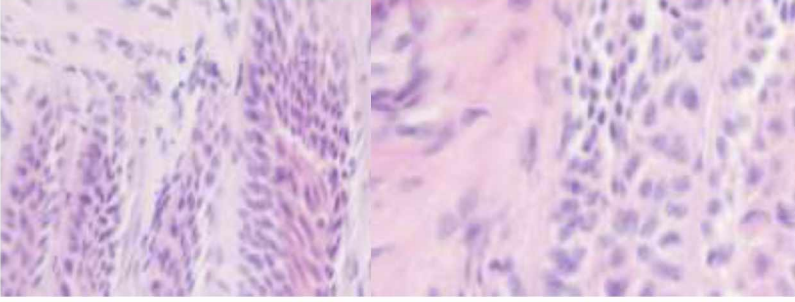
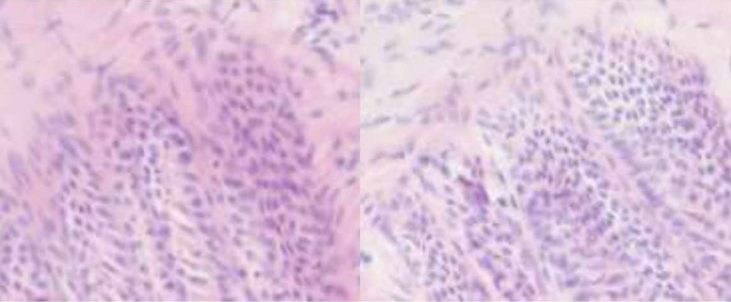
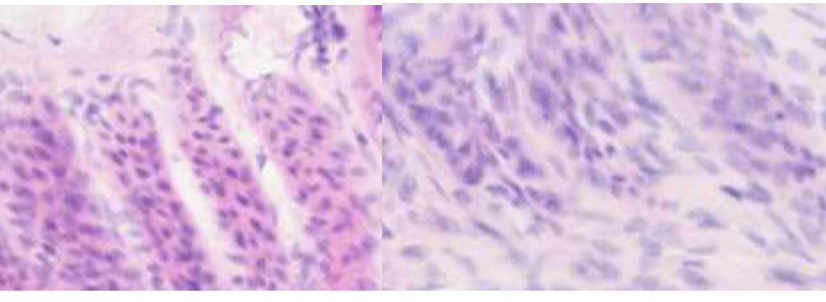
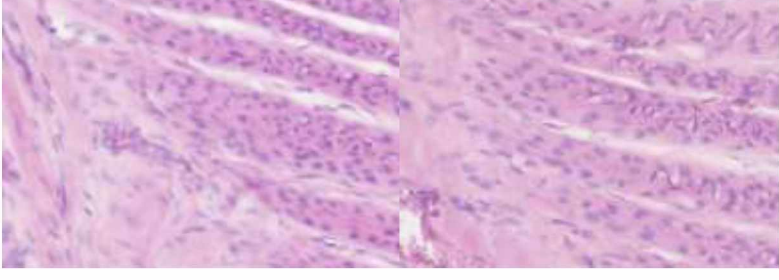
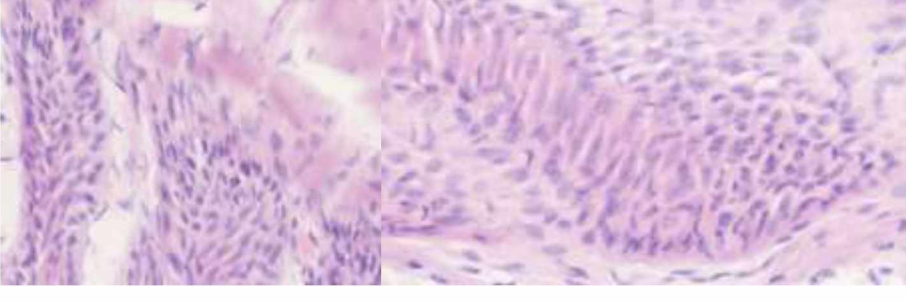
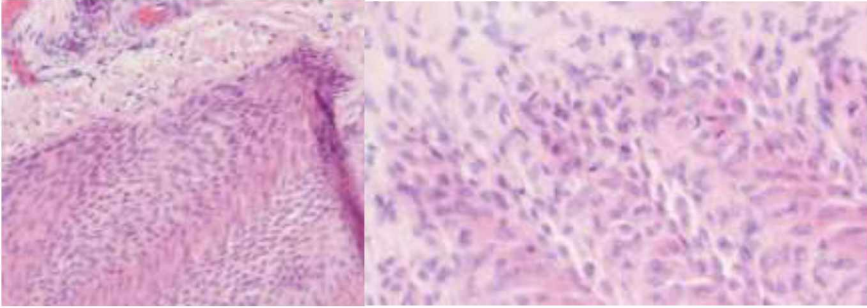
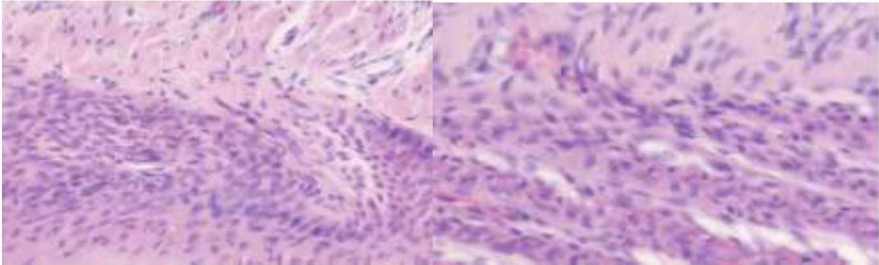
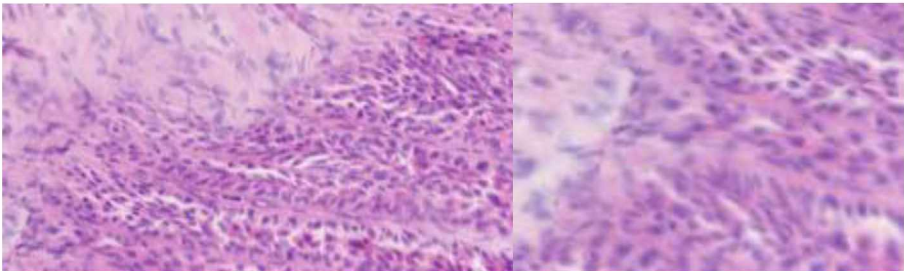
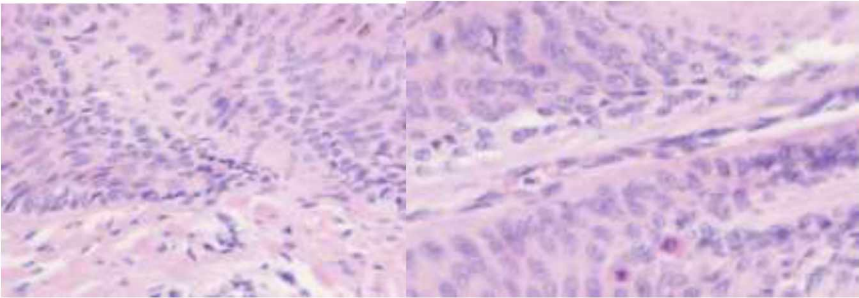
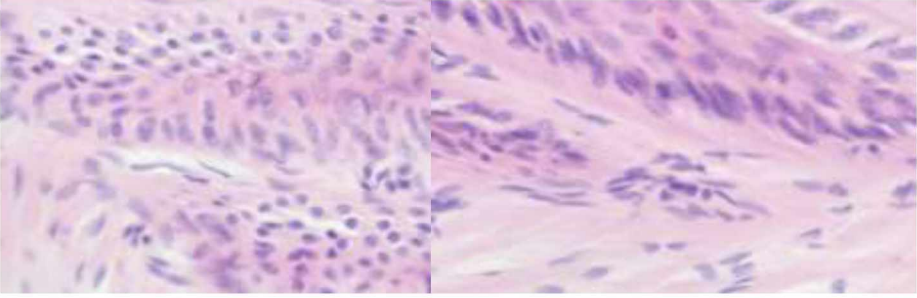
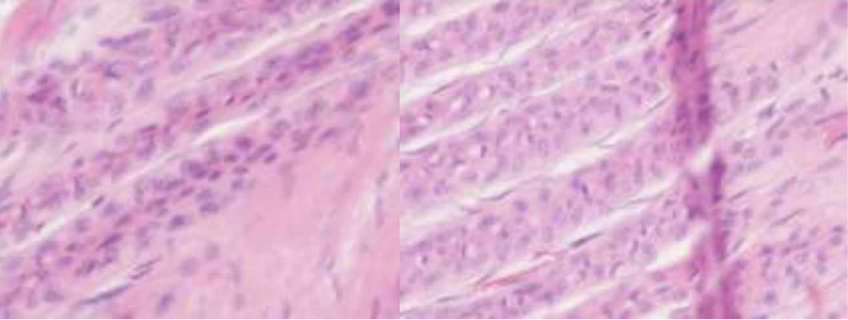
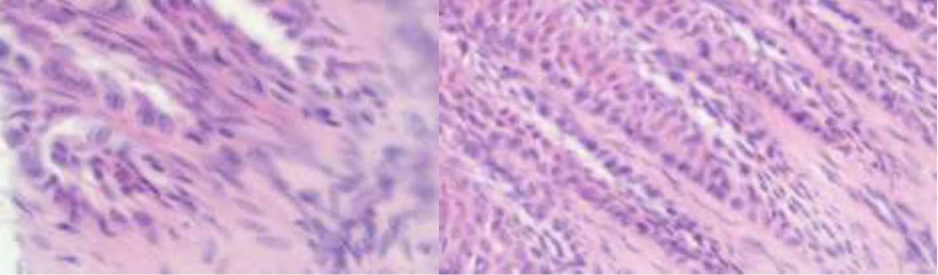
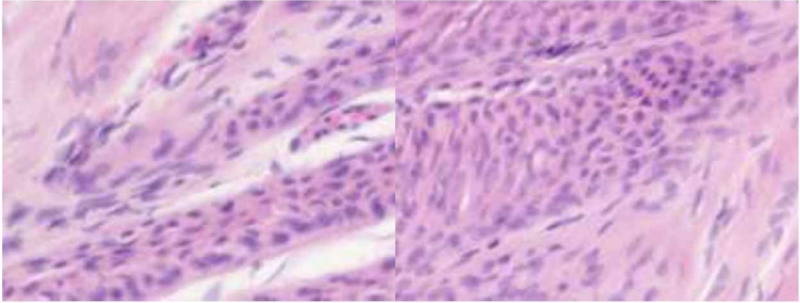
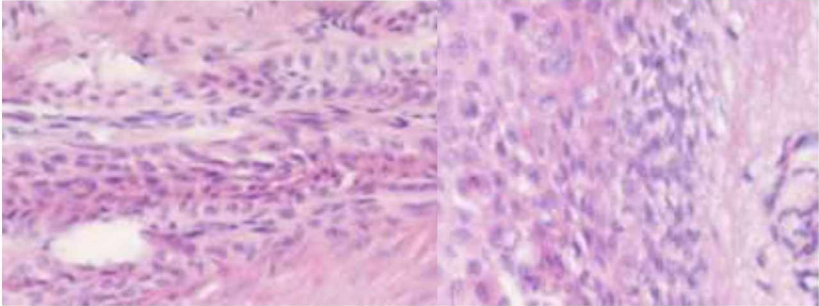
4-R	
5-R	
7-R	
9-R	
12-R	

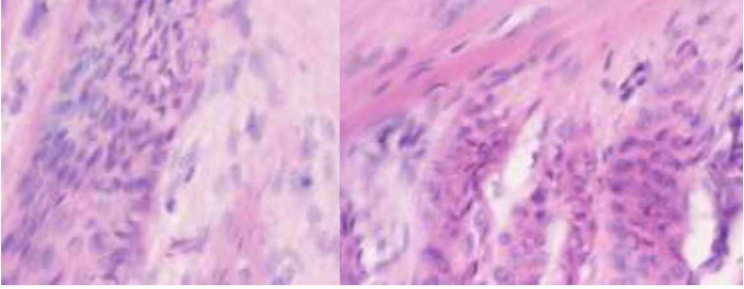
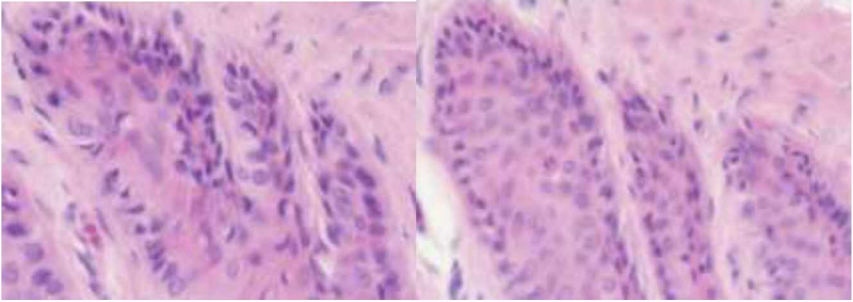
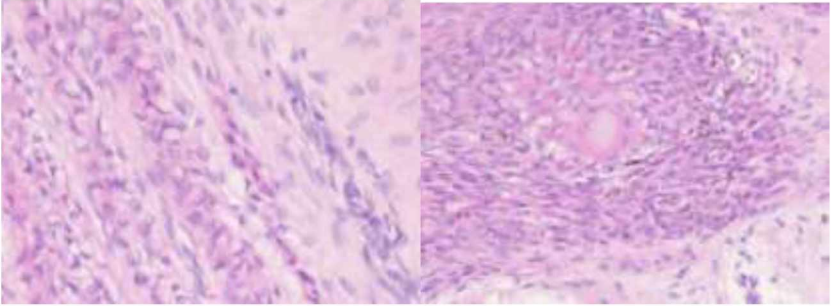
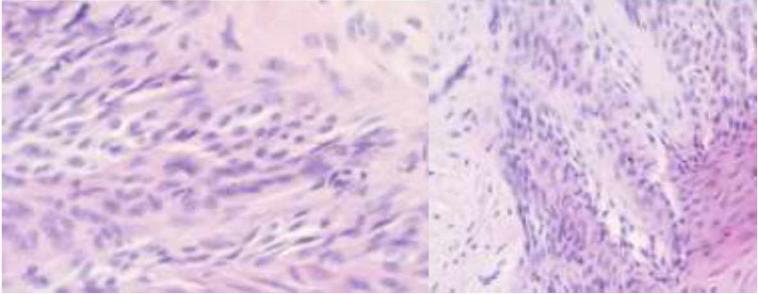
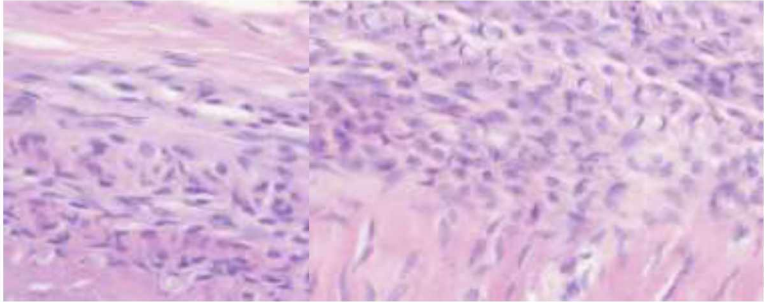
Table 19. Parameter “Epidermal Cell Response”, samples of grade (2):

Those samples correspond to biopsies of the dorsal hoof wall of the horses with their identification number presented on the left. In this table are presented slides with moderate degenerative changes of the basal epidermal cells in the SEL, corresponding to pyknotic nuclei with cellular vacuolation at SEL tip with visible mitoses (grade 2):

1-L	
1-R	
4-L	
6-L	



6-R	
8-R	
10-L	
11-L	
11-R	

12-L	
14-R	
16-L	
18-L	
19-L	



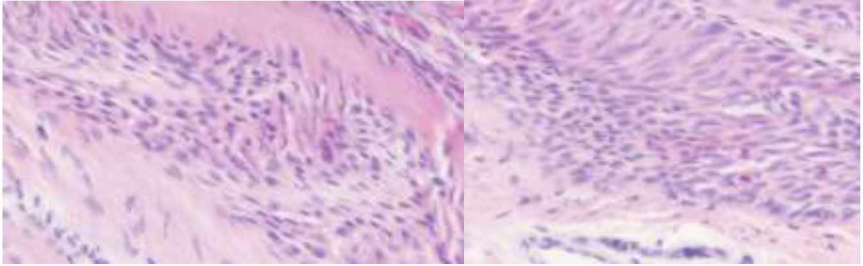
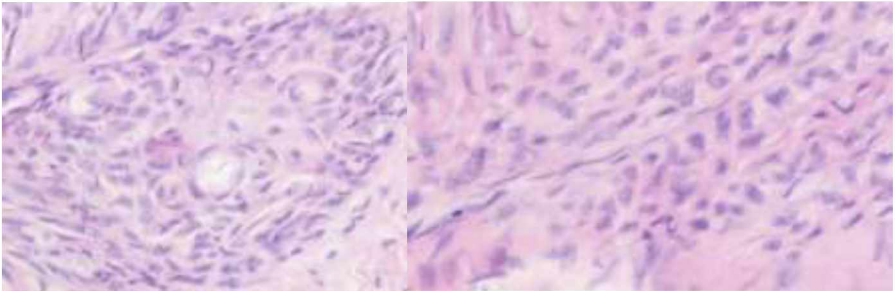
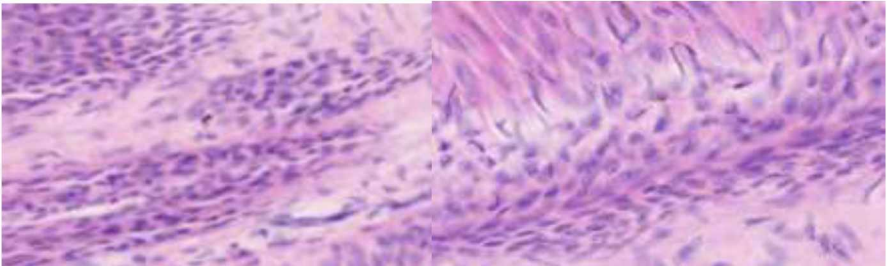
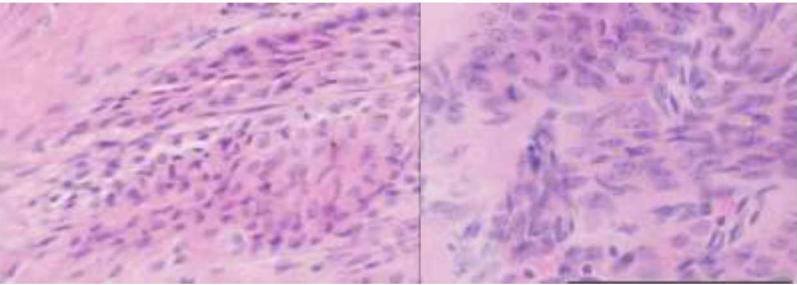
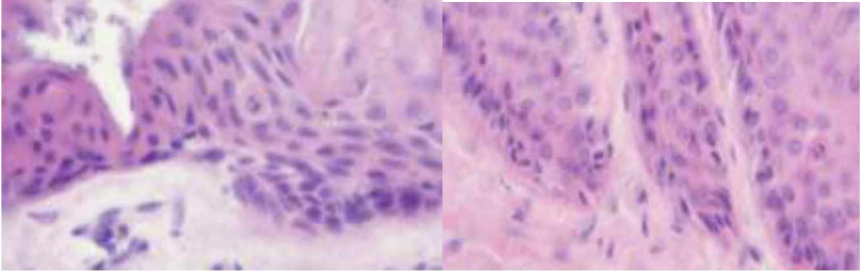
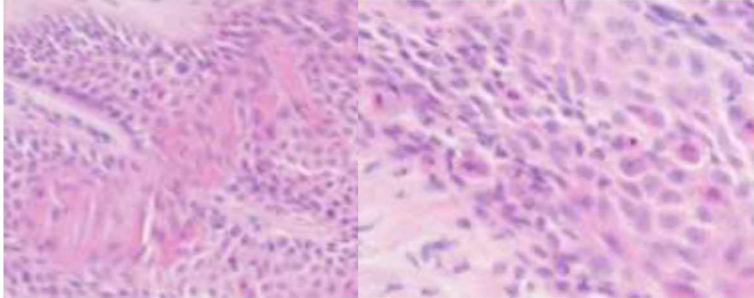
20-L	
21-R	

Table 20. Parameter “Epidermal Cell Response”, samples of grade (3):

Those samples correspond to biopsies of the dorsal hoof wall of the horses with their identification number presented on the left. In this table are presented slides with severe degenerative changes of the basal epidermal cells in the SEL, corresponding to generalised changes mentioned previously, visible on more than 5 SEL (grade 3):

10-R	
13-R	

14-L	
17-R	

#### 4.2 General results: individual and average grades per sample

Lamellae tissue evaluation concluded with an average grade of 1 (“mild change”) or less for ten samples (32.3%), eighteen (58%) between 1 and 2 (“moderate change”) and three had an average of 2 (9.7%) for a total of 31 exploitable samples. Almost 13% (12.9%) of the samples (n=4) were graded with a 3 (“severe change”) in at least one parameter. The average severity grade was 1.2 (between mild and moderate severity of the changes).

In this study, 69% of Posavac horses had a laminitic grade above 1 compared to 73% for the horses of Croatian cold blood breed. Out of 12 paired limbs, in 50% both fronts had the same grade and 50% had different grading, including one pair with a 1-point interval (14-L and 14-R). The grades attributed by parameter for each sample is indicated in this table. The average grade for one sample corresponds to the summation of the grades obtained in each parameter, divided by 5 (number of parameters evaluated per sample).

Table 21. Individual and average histopathological grades by parameters for each sample.

Sample	SEL sup.	BM	Cells	Vasc.	ECR	Av. Grade
1-L	2	2	1	1	2	1.6
1-R	2	2	2	1	2	1.8
2-L	0	1	0	0	0	0.2
2-R	0	1	0	0	0	0.2
3-L	0	0	1	1	1	0.6
3-R	0	0	1	1	1	0.6
4-L	1	1	1	1	2	1.2
4-R	1	1	1	1	1	1
5-L	0	1	1	1	0	0.4
5-R	0	1	1	0	1	0.6
6-L	2	2	2	0	2	1.6
6-R	2	1	2	0	2	1.4
7-L	1	0	1	0	0	0.4
7-R	1	0	0	0	1	0.4
8-L	NA	NA	NA	NA	NA	NA
8-R	2	2	2	1	2	1.8
9-R	2	2	2	1	1	1.8
10-L	2	2	2	2	2	2
10-R	2	2	2	1	3	2
11-L	1	2	0	1	2	1.2
11-R	1	1	2	0	2	1.2
12-L	1	2	1	1	2	1.4
12-R	1	1	1	0	1	0.8
13-L	NA	NA	NA	NA	NA	NA
13-R	2	2	1	0	3	1.6
14-L	2	2	1	2	3	2
14-R	1	1	0	1	2	1
15-L	NA	NA	NA	NA	NA	NA
15-R	NA	NA	NA	NA	NA	NA
16-L	2	2	1	1	2	1.6
17-R	3	1	0	0	3	1.4
18-L	1	1	0	0	2	0.8
19-L	1	1	1	0	2	1
20-L	2	1	1	1	2	1.4
21-R	1	1	1	2	2	1.4

The photos taken before dissection show gross macroscopical abnormalities of the hoof capsule, in many of the specimens such as shown below.

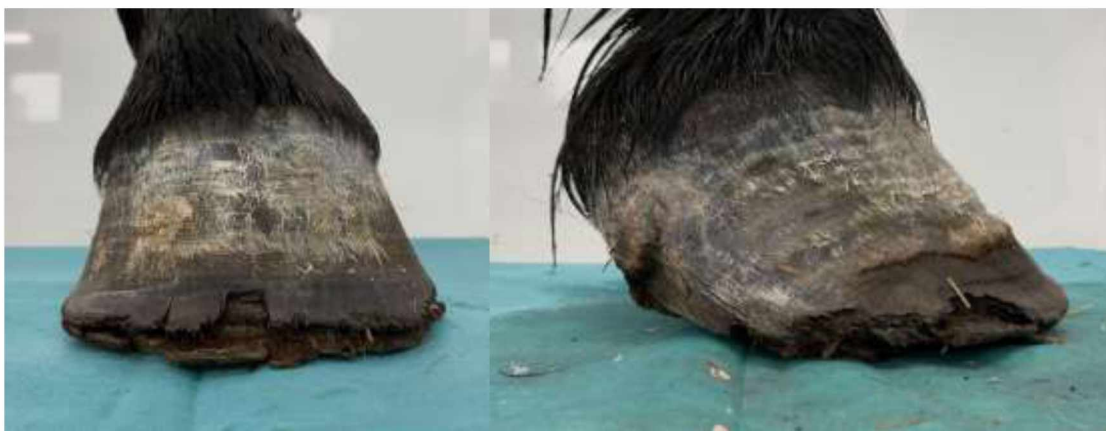

Figure 4. Left: front view of the hoof 10-L and right: lateral view of 14-L, both histological grade 2 average.

## 5. DISCUSSION

All horses included in the present study showed at least one pathological change typical for laminitis without showing obvious clinical signs of the disease. The average laminitic severity grade of the group was 1.2 out of 3, indicating mild to moderate severity of laminitis. Of the total samples, 68% (21 hooves) had an average grade of 1 or above and 32% (10 hooves) were graded between 0.2 and 0.8. The high prevalence of laminitic changes can be surprising when considering the experimental population only included randomly selected horses. However, those findings correspond with the two blind studies previously published with such aim of detecting laminitis. In the study of HAMPSON et al. (2012), 45% of the feral horses were diagnosed post-mortem with chronic laminitis (no history data). The samples from Thoroughbreds described by KAWASAKO et al. (2009) also revealed numerous structural changes coherent with laminitic changes, despite no reported clinical symptoms. One possible explanation for such results would be that our studied population, such as the feral horses, was not provided with hoof care or subjected to diagnosis for laminitis.

In our study, depending on the manner the cutting was performed, either at dissection or before the microtomy step, the appearance of the lamellae was impacted. This led to difficulties ruling a finding as artefact or pathological. Interpretation of immunohistochemical markers such as specific antibodies in the hoof has become more common and in recent studies, structural pathology changes are not used to directly affirm a diagnosis of laminitis (KAWASAKO et al., 2009). Rather, they allow for description and comparison of the different morphologies of the lamellae per horse (SLOWIKOWSKA et al., 2022). The decision to exclude structural pathology findings from our grading system seems then accurate and part of a recent trend in histopathology to use quantifiable and more reliable criteria for evaluation of lamellar tissue.

Confirming or refuting a definitive diagnosis of laminitis for each evaluated hoof was not a direct goal of this study. All samples presented with at least one histopathological change. The high prevalence of laminitic changes in our studied population with difference in severity would benefit from further development to establish a specific threshold on the adapted grading system. Great disparity in lesions were observed, visible in both PEL and SEL either axially or abaxially, which indicates both chronic and acute courses of the disease. Out of 12 paired limbs, in 50% both fronts had the same grade and 50% had different grading, including one pair with a 1-point interval (Sample 14-R, grade 1 and 14-L, grade 2). The plurality of findings in the



population indicates various stages and/or possible different aetiologies of laminitis. In the case of marked histopathological difference between two hooves from the same horse, a potential differential could be laminitis of primary traumatic origin with milder changes in the supporting limb. Further review of the results and cross evaluation with macroscopic hoof characteristics would allow to more precisely understand the lesions and hypothesize on the possible causes.

The high prevalence in lamellar pathologies, considering the population only included 3 horses over 10 years of age, indicates those horses must have been subjected to several concurrent factors favouring development of laminitis. All originated from Croatia and Slovenia and were majorly bred with the intent of meat production. Assumption can be made of poor living conditions with inadequate soil or nutrition and lack of hoof care, despite some horses being previously shod. Investigation of their exact living conditions and questioning over overall health status, including potential susceptibility of metabolic syndrome or insulin resistance in those breeds, would be relevant.

The main limitation of the present study is related to the intent of studying subclinical laminitis. While those horses presented with a health certificate, history of lameness or a clinical diagnosis of laminitis might not have been mentioned to the official veterinarian at slaughter and they most likely were not subjected to regular veterinary care. The severity and frequency of hoof lesions were not expected to this extent and would perhaps have been noticeable with a lameness examination prior to slaughter. It is likely that thorough examination and diagnosis imaging, if performed in the live horses, would have led to a diagnosis before biopsies of lamellae tissue were to be performed. To more accurately describe the prevalence of subclinical laminitis, a more thorough selection of horses should be performed and ideally, biopsy should be taken in live horses after a thorough diagnosis investigation specifically conducted with the intent to detect laminitis. This would allow for a more accurate estimation of prevalence of laminitis, in any horse population, in Croatia.

While histopathology allows for diagnosis of lamellae inflammation with certainty, the relevance of findings in association with a clinical condition can be difficult to estimate. Response to pain varies between horses and breed predisposition among other parameters affect the symptomatic expression of the conditions (POLLITT, 2007). In our study, conduction of a lameness examination in the live horses would have permitted to measure the correlation between lameness, clinical signs and histopathological findings.

It is unlikely that histopathology becomes a widespread method of diagnosis for laminitis in live horses but it can be added tool of diagnosis together with radiology. Even considering the possibility of conducting safe biopsy using appropriate instruments, the laboratory processing as well as interpretation of lamellar tissue is lengthy and requires trained personnel. However, when available, its use should be considered to confirm a diagnosis, to obtain more information on the aetiology in cases refractory to treatment or to monitor lamellar adaptation and thus disease progression. The use of histopathology in experimental research has and continues to help tremendously understanding and defining the syndrome, thus improving general veterinary care regarding laminitis (MOORE, 2008).

## 6. CONCLUSION

1. Concerning the initial goals of this study, success was achieved by establishing a protocol to obtain slides of adequate quality for histopathological examination. Furthermore, microscopical examination did reveal pathological changes which could be evaluated according to a modified histological grading system for laminitis developed during the study.

2. In Croatia, histopathological evaluation of lamellar tissue was performed for the first time in this study. Results revealed a high prevalence of laminitis whose causes must be further investigated and questions the living conditions as well as welfare status of these horses.

3. Field veterinarians should aim at increasing monitoring of the condition in Croatia as well as promoting standardisation of hoof health care.

4. Further clinical procedures including a complete lameness and clinical examination should be performed to study the true prevalence of subclinical laminitis.

5. Obtaining an accurate diagnosis of laminitis by histopathological evaluation is possible with exclusion of structural pathology and reliance on other markers of inflammation, even without the use of immunohistochemistry. This method is a gold standard for laminitis diagnosis and it appears recommendable to consider live biopsy sampling and histopathological evaluation of lamellar tissue in certain cases. However, conducting histopathology as a diagnosis tool lacks practicability and the method is unlikely to become routinely used outside of research purposes.

## 7. REFERENCES

1. ASPLIN K.E, PATTERSON-KANE J.C, SILLENCE M.N, POLLITT C.C, MCGOWAN C.M (2010): Histopathology of insulin-induced laminitis in ponies. *EVJ*, 42, 700-706. DOI:10.1111/j.2042-3306.2010.00111.x
2. DE LAAT M, PATTERSON-KANE J, POLLITT C, SILLENCE M, MCGOWAN C (2012): Histological and morphometric lesions in the pre-clinical, developmental phase of insulin-induced laminitis in Standardbred horses. *TVJ*, 195, 305-312. DOI: 10.1016/j.tvjl.2012.07.003
3. EADES S.C (2010): Overview of current laminitis research. *Vet.Clin.North.Am Equine.*, 26, 51-63. DOI:10.1016/j.cveq.2010.01.001
4. ELLIOTT J, BAILEY S.R. (2023): A review of cellular and molecular mechanisms in endocrinopathic, sepsis-related and supporting limb equine laminitis. *EVJ*, 55, 350–375. DOI:10.1111/evj.13933
5. ENGILES J.B, GALANTINO-HOMER H.L, BOSTON R, MCDONALD D, DISHOWITZ M, HANKENSON K.D (2015): Osteopathology in the Equine Distal Phalanx Associated With the Development and Progression of Laminitis. *Vet Pathol.*, 52, 928-44. DOI:10.1177/0300985815588604
6. HAMPSON B.A, DE LAAT M.A, BEAUSAC C, ROVEL T, POLLITT C.C (2012): Histopathological examination of chronic laminitis in Kaimanawa feral horses of New Zealand. *NZVetJ.*, 60, 285-9. DOI:10.1080/00480169.2012.682271
7. HOOD D.M, GROSENBAUGH D.A, MOSTAFA M.B, MORGAN S.J, THOMAS B.C (1993): The role of vascular mechanisms in the development of acute equine laminitis. *J.Vet.Intern.Med.*, 7, 228-34. DOI:10.1111/j.1939-1676.1993.tb01012.x.
8. KARIKOSKI N.P, MCGOWAN C.M, SINGER E.R, ASPLIN K.E, TULAMO R.M, PATTERSON-KANE JC (2014): Pathology of Natural Cases of Equine Endocrinopathic Laminitis Associated With Hyperinsulinemia. *Vet. Pathol.*, V52, 945-56. DOI: 10.1177/0300985814549212
9. KAWASAKO K, HIGASHI T, NAKAJI Y, KOMINE M, HIRAYAMA K, MATSUDA K, OKAMOTO M, HASHIMOTO H, TAGAMI M, TSUNODA N, TANIYAMA H. (2009): Histologic evaluation of the diversity of epidermal laminae in hooves of horses without clinical signs of laminitis. *Am.J.Vet.Res.*, 70, 186-93. DOI: 10.2460/ajvr.70.2.186

10. LASKOSKI L.M, VALADÃO C.A.A, VASCONCELOS R, SOUZA A.H, FALEIROS R.A, AMORIM R (2010): Morphological abnormalities and apoptosis in lamellar tissue of equines after intestinal obstruction and treatment with hydrocortisone.  
Arquivo BMVZ, 62, 1331-1339. DOI:10.1590/S0102-09352010000600006
11. LITTLE D, SCHRAMME M.C (2007): Diagnostic Imaging in Equine Podiatry, Chapter 10, (Floyd A.E., Mansmann R.A) Elsevier Health Sciences, Pennsylvania p141-204. DOI: 10.1002/9781119169239.ch10
12. LOFTUS, J.P, JOHNSON P.J, BELKNAP J.K, PETTIGREW A, BLACK S.J (2008): Leukocyte-derived and endogenous matrix metalloproteinases in the lamellae of horses with naturally acquired and experimentally induced laminitis.  
Vet Immunol Immunopathol, 129, 221-30. DOI:10.1016/j.vetimm.2008.11.00
13. ORSINI J.A, PARSONS C.S, CAPEWELL L, SMITH G. (2010): Prognostic indicators of poor outcome in horses with laminitis at a tertiary care hospital.  
CanVetJ., 51, 623-8. PMCID: PMC2871359.
14. MOORE R.M (2008): Evidence-Based Treatment for Laminitis—"What Works?"  
JEVS, 28, 13. DOI:https://doi.org/10.1016/j.jevs.2008.01.015.
15. MORGAN S.J, HOOD D.M, WAGNER I.P, POSTL S.P (2003): Submural histopathologic changes attributable to peracute laminitis in horses.  
Am.J.Vet.Res., 64, 829-34. DOI: 10.2460/ajvr.2003.64.829.
16. PATTERSON-KANE J.C, KARIKOSKIN.P, MCGOWAN C.M (2018): Paradigm shifts in understanding equine laminitis.  
TVJ, 231:3340. DOI:10.1016/j.tvjl.2017.11.011
17. POLLARD D, WYLIE C.E, NEWTON J.R, VERHEYEN K.L.P (2018): Incidence and clinical signs of owner-reported equine laminitis in a cohort of horses and ponies in Great Britain. EVJ, 51, 587-594. DOI:https://doi.org/10.1111/evj.13059
18. POLLITT C (1996): Basement membrane pathology: a feature of acute equine laminitis. JEVS, 28, 38-46. DOI:10.1111/j.2042-3306.1996.tb01588.x
19. POLLITT C. (2007a): Microscopic Anatomy and Physiology of the Hoof. In Equine Podiatry, Chapter 1, (Floyd A.E., Mansmann R.A), Elsevier Health Sciences, Pennsylvania p. 90-101. DOI:10.1016/B978-072160383-4.50010-4
20. POLLITT C. (2007b): Laminitis pathophysiology. In Equine podiatry, Chapter 1, (Floyd A.E., Mansmann R.A), Elsevier Health Sciences, Pennsylvania, p. 313-319. DOI: 10.1016/B978-072160383-4.50019-0



21. POLLITT C. (2016a): Dysregulation of the Lamellar Basal Epithelial Cell in Laminitis: Role of the Cytoskeleton and Cell Junctions. In Equine Laminitis Chapter 19, (Belknap J.K, Geor R.J), JohnWiley & Sons, Inc. New Jersey, p.167-17.  
DOI: 10.1002/9781119169239.ch19
22. POLLITT C. (2016b): Lamellar function at the cellular level. In Equine Laminitis Chapter 4, (J. K. Belknap, R. J. Geor), JohnWiley & Sons, Inc. New Jersey p. 22-38.  
DOI:10.1002/9781119169239.ch4
23. POLLITT C., MILINOVICH G.J. (2017): Experimental models of laminitis: oligofructose overload. In Equine Laminitis Chapter 8, pp.59-63.  
DOI:10.1002/9781119169239.ch8
24. RIBEIRO R.M, MENDES H.M.F, VALADARES R.C, PAZ C.F.R, DE PAULA LAGE DE OLIVEIRA A, ODAEL SPADETO J., FALEIROS R.R (2016): A Novel Equine Hoof Lamellar Tissue Biopsy Technique.  
JEVS, 49, 63-68. DOI: <https://doi.org/10.1016/j.jevs.2016.10.007>
25. SENDERSKA-PLONOWSKA M, SIWIŃSKA N, ZAK-BOCHENEK A, RYKALA M, SLOWIKOWSKA M, MADEJ JP, KALETA-KURATEWICZ K, NIEDŹWIEDŹ A (2022): The Differences in Histoarchitecture of Hoof Lamellae between Obese and Lean Draft Horses. *Animals (Basel)*, 12, 14:1774. DOI: 10.3390/ani12141774
26. WALLET (2013): Laminitic paleopathology: evidence from the fossil record of Equus. *JEVS*, 33, 10:840. DOI: 10.1016/j.jevs.2013.08.007

## 8. SAŽETAK

Otkrivanje subkliničkog laminitisa: histopatološka studija kopitnih lamela iz nasumične populacije konja (*ex-vivo*)

Valentine Prié

Laminitis predstavlja jednu od najčešćih bolesti koja zahvaća konje diljem svijeta. Pouzdanost tradicionalnih dijagnostičkih metoda poput radiografije je varijabilna, osobito u slučaju subkliničkog laminitisa, odnosno prije početka karakterističnih kliničkih znakova. Međutim, prognoza je povoljna ukoliko se bolest dijagnosticira u početnim stadijima razvoja bolesti.

Postavljena je hipoteza da je bolest moguće otkriti u nasumičnoj populaciji konja za koje se smatralo da su klinički slobodni od bolesti i u kojih nije prethodno postavljena dijagnoza laminitisa. Provedena je *ex vivo* patohistološka pretraga bioptata lamelarnog tkiva 31 prednje noge. Rezultati su pokazali da je u 100% kopita utvrđena barem jedna patološka promjena. Za prosječno 5 procijenjenih patohistoloških parametara, 67,7% uzoraka ocijenjeno je ocjenom iznad 1 od ukupno 3 na ljestvici težine laminitisa. Potrebno je provesti daljnja istraživanja na drugoj istraživanoj skupini s više anamnestičkih podataka.

Može se zaključiti da je prevalencija nedijagnosticiranog laminitisa u Hrvatskoj visoka te su potrebna daljnja istraživanja u svrhu utvrđivanja mogućih uzroka, kao što su uvjeti držanja i razina dobrobiti regionalnih pasmina. Nadalje, patohistološka pretraga preporučena je metoda dijagnostike laminitisa, koja se može provesti bez uključivanja procjene parametara strukturne patologije uz održavanje visoke razine točnosti rezultata.

Općenito, biopsija lamelarnog tkiva živih konja sa sumnjom na početni stadij laminitisa vjerojatno bi rezultirala ranijom i točnijom dijagnozom u predkliničkim ili subkliničkim stadijima bolesti.

Ključne riječi: subklinički laminitis, lamelarna patohistologija konja, dijagnostika

## 9. ABSTRACT

Detecting subclinical laminitis: histopathological study of hoof lamellae from a random population of horses (*ex-vivo*)

Valentine Prié

Laminitis is one the most common and debilitating conditions affecting horses worldwide. Reliability of standard diagnostic methods such as radiography is variable specifically in case of subclinical laminitis, before onset of the characteristic clinical signs. However, prognosis is favoured when diagnosis is obtained during the earliest possible phase of disease development.

Hypothesis was made that the condition could be detected in a random population of horses that were certified healthy but did not undergo laminitis diagnosis before death. Histopathological examination of lamellar tissue from dorso-sagittal wall biopsy of 31 *ex-vivo* front hooves were performed. Results showed that 100% of the lamellar samples presented with at least one pathological change. Based on the average grading of the 5 histopathological parameters evaluated, 67.7% of the samples were above 1 out of 3 on a laminitis severity index.

Conclusion can be made that the occurrence of undiagnosed laminitis is high in Croatia and investigation over possible causes such as living conditions of those regional breeds should be conducted. Further experimentation on a different study group with more history data and a complete lameness examination is necessary. Furthermore, histopathological examination is a recommendable diagnosis method for laminitis, which can be performed without inclusion of structural pathology parameters while maintaining accurate results. Generally, biopsy of lamellar samples also in live horses when laminitis onset is suspected, would likely result in earlier and more certain diagnosis during pre or subclinical phases of the condition development. However, practicability of the method is lacking and histopathological diagnosis of laminitis in live horses is likely to remain rare.

Key-word: subclinical laminitis, equine lamellar histopathology, diagnosis

## 10. BIOGRAPHY

Valentine was born in Léhon, Brittany (France), the 17th of May 2000. She grew up on the family farm, supported by a strong equestrian tradition emanating from both her parents and became a dedicated horse lover and rider. She always wished to become a veterinarian and was enrolled in the English Studies program at the Veterinary Faculty of Zagreb in Croatia from 2018 to 2024.

She was part of the equine volunteer team at the Veterinary Teaching Hospital of the faculty from 2019 to 2024 including being the group student coordinator for 2 years. During her last 2 years of studies, she participated in extra-mural foal watch, equine reproduction fieldwork and research projects both as an author and translator.

She completed over 40 weeks of equine externships in different countries and languages, including private clinics and hospitals, one institute and three veterinary schools (Veterinärmedizinische Universität - Vienna, École Nationale Vétérinaire - Maisons-Alfort, University of California - Davis) in Croatia, Ireland, France, Florida, Kentucky, Austria as a CEEPUS scholarship recipient and California.

She joined in 2021 the committee of the Equi Junior Locomotion podiatry association in France, dedicated to the promotion of knowledge exchange about the equine foot between veterinarians, farriers and students. She represented her faculty as team leader in the international competition of the association which occurred at the 2021 Equi-Meeting Congress, largest farriery and veterinary podiatry orientated event in Europe. They participated again at the 2023 Edition, finishing in second place. As a committee member, she joined multiple congresses and formations for farriers in France, Switzerland and Spain. During Equi-Meeting Congress 2023, she was for the first time an invited speaker in a large event, preparing and animating a debate about the use of traditional farriery versus barefoot podology with farriers colleagues.

Valentine's first employment in 2024 will be as an intern at Palm Beach Equine, equine hospital situated in Wellington's World Equestrian Center, Florida. In the future, she wishes to pursue a specialisation program in equine surgery or sports medicine and hopefully work jointly with her brother Benjamin, also soon to be equine veterinarian.